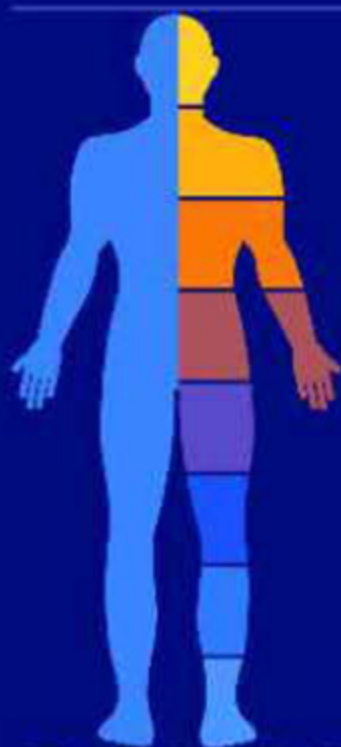

全彩
人体

解剖学
图谱

COLOUR ATLAS
OF HUMAN ANATOMY 经典版

主编 赵小云 赵凯冰 崔占军

西北大学出版社

全彩人体解剖学图谱

COLOUR ATLAS OF HUMAN ANATOMY

主 编 赵小云 赵凯冰 崔占军

西北大学出版社
西安

图书在版编目 (CIP) 数据

全彩人体解剖学图谱 / 赵小云, 赵凯冰, 崔占军主编. — 西安: 西北大学出版社, 2020.3
ISBN 978-7-5604-4476-5

I . ①全… II . ①赵… ②赵… ③崔… III . ①人体解剖学—图谱 IV . ① R322-64

中国版本图书馆 CIP 数据核字 (2020) 第 041884 号

全彩人体解剖学图谱

QUANCAI RENTI JIEPOUXUE TUPU

主 编 赵小云 赵凯冰 崔占军

出版发行 西北大学出版社

地 址 西安市太白北路 229 号

邮 编 710069

电 话 029-88305287

经 销 全国新华书店

印 刷 河南新起点印务有限公司

开 本 787 毫米 × 1092 毫米 1/16

印 张 19.5

字 数 320 千字

版 次 2020 年 3 月第 1 版 2020 年 3 月第 1 次印刷

书 号 ISBN 978-7-5604-4476-5

定 价 98.00 元

如有印装质量问题, 请与本社联系调换, 电话 029-88302966。

前 言

人体解剖学图谱是学习人体解剖学不可或缺的工具书。人体解剖学属于形态学科，主要通过解剖观察、结构辨认和描述等方法，以掌握正常人体器官的位置、形态、结构和重要的毗邻关系，为临床工作奠定基础。一本好的人体解剖学图谱，显示人体各器官的位置关系和形态结构直观、明了，它不仅是学生在课堂上观察和辨认的指南，也可供自学和课后复习参考。本图谱既可以作为医学生的辅助教材，也可以作为解剖学教师、临床医师特别是外科医师的工具书。

本图谱共有图片 600 余幅，按运动系统、消化系统、呼吸系统、泌尿生殖系统、循环系统、神经系统、感觉器、内分泌系统和局部解剖学等顺序编排。为了节省篇幅和考虑到某些院校的解剖学教学侧重于局部解剖的实际情况，本书的编排包括系统解剖学和局部解剖学两部分内容。在系统解剖学部分中，对某些内容采用一图多用表现方法进行设计绘制，例如肌肉、动脉和脊神经等内容，均在局部解剖图中予以综合展示，而未做独立部分或完整系统编排。因此，使用本图谱时可分别在运动系统、循环系统和神经系统的文字说明中查找肌肉、动脉和脊神经内容的图号。

本图谱大多数图稿以实物标本写生为主，力求反映国人的形态结构特点和我国的医学绘图风格。在编写过程中编者根据国内高等医学院校解剖学教学大纲的要求，同时考虑基础与临床等相关专业技术工作者教学、医疗及科研工作的需要，结合编者多年的实际教学经验，参阅了国内外若干资料予以综合或更改后绘制而成。

本书内容丰富，标注结构较为详细，采用部分标注简写，如 M.(muscle)、lig.(ligament)、A.(artery)、T.(tendon)、V.(vein)、N.(nerve) 等，图片清晰，立体感较强，是学习研究人体解剖学较为理想的参考图书。本图谱所有标注采取中英文对照方式，便于读者学习。本书的编写得到了国内众多医学院校及医院的帮助和支持，在此表示衷心的感谢。

由于编者水平有限，加之时间较为仓促，本图谱难免有疏漏之处，恳望各位读者见谅指正。

编 者

目 录

Contents

| | | |
|------|--|----|
| 图 1 | 全身骨骼 (前面观) The skeleton(anterior aspect)····· | 1 |
| 图 2 | 全身骨骼 (后面观) The skeleton(posterior aspect)····· | 2 |
| 图 3 | 骨的构造 Structure of the bone····· | 3 |
| 图 4 | 骨连结的分类与构造 Classification and structure of the joint····· | 4 |
| 图 5 | 脊柱全貌 The vertebral column····· | 5 |
| 图 6 | 寰椎 (上面观) The atlas(superior aspect)····· | 6 |
| 图 7 | 枢椎 (后面观) The axis(posterior aspect)····· | 6 |
| 图 8 | 颈椎 (上面观) The cervical vertebra(superior aspect)····· | 6 |
| 图 9 | 隆椎 (上面观) The vertebra prominens(superior aspect)····· | 6 |
| 图 10 | 胸椎 (上面观) The thoracic vertebra(superior aspect)····· | 6 |
| 图 11 | 胸椎 (左侧面观) The thoracic vertebra(left lateral aspect)····· | 6 |
| 图 12 | 腰椎 (上面观) The lumbar vertebra(superior aspect)····· | 6 |
| 图 13 | 腰椎 (左侧面观) The lumbar vertebra(left lateral aspect)····· | 6 |
| 图 14 | 骶骨和尾骨 The sacrum and coccyx····· | 7 |
| 图 15 | 椎骨间的连接 (正中矢状面) Intervertebral joints(median sagittal plane)····· | 8 |
| 图 16 | 椎骨间的连接 (前面观) Intervertebral joints(anterior aspect)····· | 8 |
| 图 17 | 椎间盘 (上面观) Intervertebral disc(superior aspect)····· | 8 |
| 图 18 | 颅颈外韧带 External craniocervical ligament····· | 9 |
| 图 19 | 颅颈内韧带 Internal craniocervical ligament····· | 10 |
| 图 20 | 颈椎 X 线像 (侧面观) Radiograph of cervical vertebra(lateral aspect)····· | 11 |
| 图 21 | 颈椎 X 线像 (后面观) Radiograph of cervical vertebra(posterior aspect)····· | 11 |
| 图 22 | 腰椎 X 线像 (侧面观) Radiograph of lumbar vertebra(lateral aspect)····· | 11 |
| 图 23 | 腰椎 X 线像 (后面观) Radiograph of lumbar vertebra(posterior aspect)····· | 11 |
| 图 24 | 腰椎间盘突出 The lumbar disc herniation····· | 12 |
| 图 25 | 胸廓 (前面观) The thorax(anterior aspect)····· | 13 |
| 图 26 | 肋骨 The costal bone····· | 14 |
| 图 27 | 肋椎关节 (上面观) The costovertebral joint(superior aspect)····· | 14 |
| 图 28 | 肋椎关节 (侧面观) The costovertebral joint(lateral aspect)····· | 15 |
| 图 29 | 胸骨 The sternum····· | 15 |
| 图 30 | 颅 (前面观) The cranium(anterior aspect)····· | 16 |
| 图 31 | 新生儿颅 (上面观) The cranium of newborn infant(superior aspect)····· | 16 |
| 图 32 | 颅 (侧面观) The cranium(lateral aspect)····· | 17 |
| 图 33 | 新生儿颅 (侧面观) The cranium of newborn infant(lateral aspect)····· | 17 |
| 图 34 | 颅底外面 The external surface of the base of cranium····· | 18 |
| 图 35 | 颅底内面 The internal surface of the base of cranium····· | 19 |
| 图 36 | 颅 (正中矢状面) The cranium(median sagittal plane)····· | 20 |
| 图 37 | 眶 (前面观) The orbit(anterior aspect)····· | 21 |
| 图 38 | 下颌骨 The mandible····· | 21 |
| 图 39 | 腭骨 The palatine bone····· | 22 |
| 图 40 | 舌骨 The hyoid bone····· | 22 |
| 图 41 | 骨性鼻中隔 The bony nasal septum····· | 22 |
| 图 42 | 鼻腔外侧壁 Lateral nasal wall····· | 23 |
| 图 43 | 颅的 X 线像 Radiograph of the cranium····· | 24 |
| 图 44 | 筛骨 (上面观、后面观) The ethmoid bone(superior, posterior aspect)····· | 25 |

| | | |
|------|--|----|
| 图 45 | 颞骨 (外面观、内面观) The temporal bone(external, internal aspect)..... | 25 |
| 图 46 | 颞下颌关节 The temporomandibular joint | 26 |
| 图 47 | 额骨 The frontal bone | 27 |
| 图 48 | 枕骨 The occipital bone | 28 |
| 图 49 | 颅骨冠状面的后面观 (示筛小房) Posterior aspect of frontal plane of the cranium(showing the ethmoidal cellules) | 29 |
| 图 50 | 锁骨 The clavicle..... | 29 |
| 图 51 | 蝶骨 The sphenoid bone..... | 30 |
| 图 52 | 肱骨和肩胛骨 (前面观) The humerus and scapula(anterior aspect) | 31 |
| 图 53 | 肱骨和肩胛骨 (后面观) The humerus and scapula(posterior aspect)..... | 32 |
| 图 54 | 桡骨和尺骨 The radius and ulna..... | 33 |
| 图 55 | 手骨 The bones of the hand..... | 34 |
| 图 56 | 掌间和指间韧带 Metacarpophalangeal and interphalangeal ligaments..... | 35 |
| 图 57 | 腕的韧带 (背面观) The ligaments of the wrist(dorsal aspect)..... | 36 |
| 图 58 | 腕关节冠状面 (背面观) The frontal plane of the wrist joint(dorsal aspect)..... | 36 |
| 图 59 | 胸锁关节 (前面观) The sternoclavicular joint(anterior aspect) | 37 |
| 图 60 | 肩关节 (前面观) The shoulder joint(anterior aspect) | 37 |
| 图 61 | 肩关节 (冠状面) The shoulder joint(frontal plane) | 38 |
| 图 62 | 肩关节内面 (前外侧观) The shoulder joint inside(anterolateral aspect)..... | 38 |
| 图 63 | 肘关节 (1) The elbow joint(1) | 38 |
| 图 64 | 肘关节 (2) The elbow joint(2) | 39 |
| 图 65 | 肩关节 X 线像 (前后位) Radiograph of the shoulder joint(anteroposterior) | 40 |
| 图 66 | 肘关节 X 线像 (前后位) Radiograph of the elbow joint(anteroposterior) | 40 |
| 图 67 | 肘关节 X 线像 (侧位) Radiograph of the elbow joint(lateral) | 40 |
| 图 68 | 手 X 线像 (前后位) Radiograph of the hand(anteroposterior) | 40 |
| 图 69 | 髌骨 The hip bone | 41 |
| 图 70 | 股骨 The femur | 42 |
| 图 71 | 胫骨和腓骨 The tibia and fibula | 43 |
| 图 72 | 足骨 (1) The bone of foot(1) | 44 |
| 图 73 | 足骨 (2) The bone of foot(2) | 45 |
| 图 74 | 跟骨 (上面观) The calcaneus(superior aspect) | 45 |
| 图 75 | 髌骨 The patella..... | 45 |
| 图 76 | 胫骨 (上面观) The tibia(superior aspect) | 45 |
| 图 77 | 骨盆的韧带 The ligament of the pelvis | 46 |
| 图 78 | 骨盆 The pelvis | 47 |
| 图 79 | 髋关节 The hip joint | 48 |
| 图 80 | 股骨及其动脉 The femur and its artery | 49 |
| 图 81 | 膝关节 (1) The knee joint (1) | 50 |
| 图 82 | 膝关节 (2) (前面观) The knee joint (2) (anterior aspect) | 51 |
| 图 83 | 膝关节 (3) The knee joint (3) | 52 |
| 图 84 | 膝 (下面观) Knee(inferior aspect) | 53 |
| 图 85 | 足的韧带 The ligaments of the foot | 54 |
| 图 86 | 足底的韧带 The ligaments of sole of foot | 55 |
| 图 87 | 跖趾关节和趾间关节的关节囊和韧带 Capsule and ligaments of metatarsophalangeal and interphalangeal joints | 55 |
| 图 88 | 骨盆和髋关节 X 线像 (前后位) Radiograph of pelvis and hip joint(anteroposterior) | 56 |
| 图 89 | 膝关节 X 线像 (前后位) Radiograph of knee joint(anteroposterior) | 56 |
| 图 90 | 膝关节 X 线像 (侧位) Radiograph of knee joint(lateral) | 56 |
| 图 91 | 踝和足的 X 线像 (侧位) Radiograph of ankle and foot(lateral) | 56 |
| 图 92 | 全身体表及肌肉 (前面观) Surface anatomy and muscles of the body(anterior aspect) | 57 |
| 图 93 | 全身体表及肌肉 (后面观) Surface anatomy and muscles of the body(posterior aspect) | 58 |
| 图 94 | 肌的各种形状 Forms of muscles | 59 |
| 图 95 | 肌的横断面 Transverse section of muscle | 60 |

| | | |
|-------|---|----|
| 图 96 | 腱鞘示意图 Schematic diagram of tendinous sheath | 60 |
| 图 97 | 筋膜鞘示意图 Schematic diagram of fascial sheath | 60 |
| 图 98 | 消化系统概观 General view of alimentary system | 61 |
| 图 99 | 口腔顶 The roof of the mouth | 62 |
| 图 100 | 口腔底 The floor of the mouth | 63 |
| 图 101 | 上颌恒牙 Maxillary permanent teeth | 64 |
| 图 102 | 下颌恒牙 Mandibular permanent teeth | 64 |
| 图 103 | 牙 (1) The teeth(1) | 64 |
| 图 104 | 牙 (2) The teeth(2) | 65 |
| 图 105 | 舌 (1) The tongue(1) | 66 |
| 图 106 | 舌 (2) The tongue(2) | 67 |
| 图 107 | 唾液腺 (1) The salivary gland (1) | 67 |
| 图 108 | 唾液腺 (2) The salivary gland (2) | 68 |
| 图 109 | 鼻腔、口腔、咽和喉的正中矢状面 Median sagittal plane of nasal cavity, oral cavity, pharynx and larynx | 69 |
| 图 110 | 咽门 The fauces | 70 |
| 图 111 | 咽肌正中矢状面 Median sagittal plane of pharyngeal muscle | 71 |
| 图 112 | 咽腔 (后面观) The cavity of pharynx (posterior aspect) | 72 |
| 图 113 | 咽肌 (后面观) The muscles of pharynx (posterior aspect) | 73 |
| 图 114 | 咽肌 (外侧面观) The muscles of pharynx (lateral aspect) | 74 |
| 图 115 | 食管 (前面观) The esophagus (anterior aspect) | 75 |
| 图 116 | 胃的黏膜 The gastric mucosa | 76 |
| 图 117 | 胃 The stomach | 76 |
| 图 118 | 大网膜和腹腔脏器 Greater omentum and abdominal viscera | 77 |
| 图 119 | 空肠 (内面观) The jejunum (internal aspect) | 78 |
| 图 120 | 回肠 (内面观) The ileum (internal aspect) | 78 |
| 图 121 | 结肠 (外面观) The colon (external aspect) | 78 |
| 图 122 | 盲肠和阑尾 The cecum and vermiform appendix | 79 |
| 图 123 | 直肠 (内面观) The rectum (internal aspect) | 79 |
| 图 124 | 食管的 X 线像 (斜位) Radiograph of the esophagus (oblique) | 80 |
| 图 125 | 胃和十二指肠的 X 线像 (前后位) Radiograph of the stomach and duodenum (anteroposterior) | 80 |
| 图 126 | 小肠的 X 线像 (前后位) Radiograph of the small intestine (anteroposterior) | 80 |
| 图 127 | 大肠的 X 线像 (前后位) Radiograph of the large intestine (anteroposterior) | 80 |
| 图 128 | 膈面 Diaphragmatic surface | 81 |
| 图 129 | 肝 The liver | 81 |
| 图 130 | 肝叶、肝段和血管、胆管的肝内分布 The lobe of liver, the segment of liver and the intrahepatic distribution of the blood vessels and bile ducts | 82 |
| 图 131 | 胆道、十二指肠 (前面观) The bile duct, duodenum (anterior aspect) | 83 |
| 图 132 | 胰 The pancreas | 84 |
| 图 133 | 呼吸系统概观 General arrangement of the respiratory system | 85 |
| 图 134 | 鼻 The nose | 86 |
| 图 135 | 喉软骨 The laryngeal cartilage | 86 |
| 图 136 | 鼻腔外侧壁 (内侧面观) Lateral wall of the nasal cavity (internal aspect) | 87 |
| 图 137 | 喉肌 The muscles of larynx | 88 |
| 图 138 | 喉的冠状面 The frontal plane of larynx | 88 |
| 图 139 | 喉的神经 The nerve of larynx | 89 |
| 图 140 | 喉口 (后面观) The aperture of larynx (posterior aspect) | 90 |
| 图 141 | 通过声带的喉横切面 A transverse section of the larynx through the level of the vocal fold | 90 |
| 图 142 | 喉腔的喉镜所见 Laryngoscope view of the laryngeal cavity | 90 |
| 图 143 | 肺 (前面观) The lungs (anterior aspect) | 91 |
| 图 144 | 右肺 Right lung | 92 |
| 图 145 | 左肺 Left lung | 92 |
| 图 146 | 支气管肺段 (1) Bronchopulmonary segments (1) | 93 |

| | | |
|-------|---|-----|
| 图 147 | 支气管肺段(2) Bronchopulmonary segments(2) | 94 |
| 图 148 | 气管和支气管 Trachea and bronchi | 95 |
| 图 149 | 肺的体表投影(前面观) The surface projection of lungs(anterior aspect) | 96 |
| 图 150 | 肺的体表投影(后面观) The surface projection of lungs(posterior aspect) | 97 |
| 图 151 | 泌尿生殖系统概观 General view of the urogenital system | 98 |
| 图 152 | 腹后壁(示肾及输尿管的位置) Posterior abdominal wall (showing kidneys and ureters in situ) | 99 |
| 图 153 | 肾(后面观) The kidneys(posterior aspect) | 100 |
| 图 154 | 肾的毗邻 The relations of kidney | 100 |
| 图 155 | 肾的大体结构 Cross structure of kidney | 101 |
| 图 156 | 肾的动脉和静脉 The artery and vein of kidney | 102 |
| 图 157 | 肾的动脉和肾段 Intrarenal artery and renal segments | 103 |
| 图 158 | 肾动脉和静脉的变异 The variation of renal arteries and veins | 104 |
| 图 159 | 肾筋膜 Renal fascia | 105 |
| 图 160 | 前列腺和精囊 Prostate and seminal vesicle | 106 |
| 图 161 | 男性骨盆正中矢状面 Median sagittal plane of male pelvis | 107 |
| 图 162 | 阴囊及其内容物 Scrotum and contents | 108 |
| 图 163 | 睾丸、附睾和输精管 Testis, epididymis and deferent duct | 109 |
| 图 164 | 男性会阴和外生殖器 Perineum and external genital organs of male | 110 |
| 图 165 | 阴茎 The penis | 111 |
| 图 166 | 女性骨盆正中矢状面 Median sagittal plane of female pelvis | 112 |
| 图 167 | 女性外生殖器 External genital organs of female | 112 |
| 图 168 | 女性内生殖器 Internal genital organs of female | 113 |
| 图 169 | 子宫口 Orifice of uterus | 114 |
| 图 170 | 女性盆腔器官(前上面观) Pelvic organs of female(antero-superior aspect) | 114 |
| 图 171 | 阴蒂、前庭球及前庭大腺 The clitoris, bulb of vestibule and greater vestibular gland | 115 |
| 图 172 | 乳房 The breast | 116 |
| 图 173 | 乳房矢状面示意图 Schematic diagram of sagittal plane of breast | 116 |
| 图 174 | 男性会阴肌 Perineal muscle of male | 117 |
| 图 175 | 女性会阴肌 Perineal muscle of female | 117 |
| 图 176 | 男性骨盆冠状面(示泌尿生殖膈及盆膈) The frontal plane of male pelvis(showing urogenital diaphragm and pelvic diaphragm) | 118 |
| 图 177 | 女性骨盆冠状面(示泌尿生殖膈及盆膈) The frontal plane of female pelvis(showing urogenital diaphragm and pelvic diaphragm) | 118 |
| 图 178 | 女性盆膈(上面观) Female pelvic diaphragm(superior aspect) | 119 |
| 图 179 | 女性盆膈(下面观) Female pelvic diaphragm(inferior aspect) | 119 |
| 图 180 | 男性盆膈(上面观) Male pelvic diaphragm(superior aspect) | 120 |
| 图 181 | 坐骨肛门窝 Ischioanal fossa | 120 |
| 图 182 | 男性盆膈(下面观) Male pelvic diaphragm(inferior aspect) | 121 |
| 图 183 | 腹后壁的腹膜 The peritoneum on the posterior abdominal wall | 122 |
| 图 184 | 男性盆腔正中矢状面 Median sagittal plane of male abdominal cavity | 123 |
| 图 185 | 腹腔水平面 Horizon plane of abdominal cavity | 124 |
| 图 186 | 血管分布 The distribution of blood vessels | 125 |
| 图 187 | 大、小循环示意图 Schematic diagram of the greater and the lesser circulation | 126 |
| 图 188 | 心脏的位置 Position of heart | 127 |
| 图 189 | 心脏的外形和血管 External features and blood vessels of heart | 128 |
| 图 190 | 右心房和右心室 The right atrium and ventricle | 129 |
| 图 191 | 左心房和左心室 The left atrium and ventricle | 130 |
| 图 192 | 心房、心室和室间隔 Atrium, ventricle and interventricular septum | 131 |
| 图 193 | 心肌的走行 Course of the cardiac muscles | 132 |
| 图 194 | 心底 The cardiac base | 132 |
| 图 195 | 心的传导系统 The conduction system of heart | 133 |

| | | |
|-------|--|-----|
| 图 196 | 心的瓣膜和纤维支架 Valves and fibrous skeleton of heart | 134 |
| 图 197 | 主动脉瓣 Aortic valve | 135 |
| 图 198 | 三尖瓣 Tricuspid valve | 135 |
| 图 199 | 二尖瓣 Mitral valve | 135 |
| 图 200 | 心包 The pericardium | 136 |
| 图 201 | 心瓣膜的体表投影 Surface projection of valves of heart | 137 |
| 图 202 | 心的 X 线像 Radiograph of heart | 137 |
| 图 203 | 面和颅顶浅动、静脉 Superficial arteries and veins of face and scalp | 138 |
| 图 204 | 板障静脉 The diploic veins | 139 |
| 图 205 | 脊柱的静脉 The veins of vertebral column | 139 |
| 图 206 | 肝门静脉和门腔静脉吻合 Hepatic portal vein and portacaval anastomosis | 140 |
| 图 207 | 肝门静脉的变异 The variation of hepatic portal vein | 141 |
| 图 208 | 胎儿血液循环示意图 Schematic diagram of fetal blood circulation | 142 |
| 图 209 | 淋巴系统示意图 Schematic diagram of lymphatic system | 143 |
| 图 210 | 腹后壁的静脉、淋巴管和淋巴结 Veins, lymphatic vessels and lymph nodes of posterior abdominal wall | 144 |
| 图 211 | 头和颈的淋巴管和淋巴结 Lymphatic vessels and lymph nodes of head and neck | 145 |
| 图 212 | 咽和舌的淋巴管、淋巴结 Lymphatic vessels and lymph nodes of pharynx and tongue | 146 |
| 图 213 | 乳腺的淋巴管和淋巴结 Lymphatic vessels and lymph nodes of mammary gland | 147 |
| 图 214 | 气管、支气管及肺的淋巴管和淋巴结 Lymphatic vessels and lymph nodes of trachea, bronchi and lungs | 148 |
| 图 215 | 胃的淋巴管和淋巴结 Lymphatic vessels and lymph nodes of stomach | 149 |
| 图 216 | 大肠的淋巴管和淋巴结 Lymphatic vessels and lymph nodes of large intestine | 150 |
| 图 217 | 胰的淋巴管和淋巴结 Lymphatic vessels and lymph nodes of pancreas | 151 |
| 图 218 | 女性生殖器的淋巴管和淋巴结 Lymphatic vessels and lymph nodes of female genital organs | 152 |
| 图 219 | 上肢的淋巴管和淋巴结 Lymphatic vessels and lymph nodes of upper limb | 153 |
| 图 220 | 下肢的淋巴管和淋巴结 Lymphatic vessels and lymph nodes of lower limb | 154 |
| 图 221 | 脾 Spleen | 155 |
| 图 222 | 神经系统示意图 Schematic diagram of nervous system | 156 |
| 图 223 | 神经元示意图 Schematic diagram of neurons | 157 |
| 图 224 | 脊髓白质固有束示意图 Schematic diagram of the fasciculus proprius in white matter of spinal cord | 158 |
| 图 225 | 膝跳反射示意图 Schematic diagram of the knee jerk | 158 |
| 图 226 | 脊神经的组成和分布示意图 Schematic diagram of the constitution and distribution of spinal nerves | 158 |
| 图 227 | 脊髓的横切面 Transverse sections of spinal cord | 159 |
| 图 228 | 脊髓的外形和被膜 External morphology of spinal cord and meninges | 159 |
| 图 229 | 脊髓和脊神经根 The spinal cord and roots of spinal nerves | 160 |
| 图 230 | 脊髓节段与椎骨的相应位置关系示意图 Schematic diagram of the relation of segments of spinal cord to vertebrae | 160 |
| 图 231 | 脊髓颈段横切面 Transverse section through cervical segment of spinal cord | 161 |
| 图 232 | 脊髓的细胞构筑分层 Cytoarchitectural lamination of spinal cord | 161 |
| 图 233 | 脑干(前面观) The brain stem(anterior aspect) | 162 |
| 图 234 | 脑干(后面观) The brain stem(posterior aspect) | 162 |
| 图 235 | 脑干内脑神经核(1) Nuclei of cranial nerve in brain stem(1) | 163 |
| 图 236 | 脑干内脑神经核(2) Nuclei of cranial nerve in brain stem(2) | 164 |
| 图 237 | 延髓横切面(经锥体交叉) Transverse section of the medulla oblongata(through the decussation of pyramid) | 165 |
| 图 238 | 延髓横切面(经内侧丘系交叉) Transverse section of the medulla oblongata(through the decussation of medial lemniscus) | 165 |
| 图 239 | 延髓横切面(经下橄榄核中部) Transverse section of the medulla oblongata(through the middle part of the inferior olivary nucleus) | 166 |
| 图 240 | 延髓横切面(经蜗神经核) | |

| | | |
|-------|--|-----|
| | Transverse section of the medulla oblongata(through the cochlear nucleus)····· | 166 |
| 图 241 | 脑桥横切面 (经面神经丘) | |
| | Transverse section of the pons(through the facial colliculus)····· | 167 |
| 图 242 | 脑桥横切面 (经三叉神经运动核) | |
| | Transverse section of the pons(through the motor nucleus of the trigeminal nerve)····· | 167 |
| 图 243 | 中脑横切面 (经下丘) | |
| | Transverse section of the midbrain(through the inferior colliculus)····· | 168 |
| 图 244 | 中脑横切面 (经上丘) | |
| | Transverse section of the midbrain(through the superior colliculus)····· | 168 |
| 图 245 | 第四脑室脉络组织和脉络丛 | |
| | The tela choroidea and choroid plexus of fourth ventricle····· | 169 |
| 图 246 | 内、外侧丘系 The medial and lateral lemniscus····· | 169 |
| 图 247 | 前庭神经核的主要纤维投射 Principal fiber projections of the vestibular nucleus····· | 170 |
| 图 248 | 面神经在脑桥内的行程示意图 Schematic diagram of intrapontine course of facial nerve····· | 170 |
| 图 249 | 锥体束 The pyramidal tract····· | 171 |
| 图 250 | 视束及视辐射 The optic tract and optic radiation····· | 171 |
| 图 251 | 下丘脑核团示意图 Schematic diagram of the hypothalamic nucleus····· | 172 |
| 图 252 | 丘脑核团示意图 Schematic diagram of the thalamic nucleus····· | 172 |
| 图 253 | 小脑 The cerebellum····· | 173 |
| 图 254 | 小脑分叶示意图 Schematic diagram of the lobes of the cerebellum····· | 174 |
| 图 255 | 小脑皮质结构示意图 Schematic diagram of the structure of the cerebellar cortex····· | 174 |
| 图 256 | 小脑脚及外侧丘系 The peduncles of the cerebellum and lateral lemniscus····· | 175 |
| 图 257 | 小脑上脚及小脑齿状核 | |
| | The superior cerebellar peduncle and dentate nucleus····· | 175 |
| 图 258 | 大脑半球外侧面 Lateral surface of the cerebral hemisphere····· | 176 |
| 图 259 | 大脑半球内侧面 Medial surface of the cerebral hemisphere····· | 176 |
| 图 260 | 大脑皮质的细胞构筑分区 (外侧面) | |
| | Cytoarchitectonic areas of the cerebral cortex(lateral surface)····· | 177 |
| 图 261 | 大脑皮质的细胞构筑分区 (内侧面) | |
| | Cytoarchitectonic areas of the cerebral cortex(medial surface)····· | 177 |
| 图 262 | 脑底面 Basal surface of the brain····· | 178 |
| 图 263 | 脑岛 The insula····· | 178 |
| 图 264 | 脑的正中矢状面 Median sagittal plane of the brain····· | 179 |
| 图 265 | 穹窿 The fornix····· | 179 |
| 图 266 | 海马 The hippocampus····· | 180 |
| 图 267 | 基底核 The basal nuclei····· | 180 |
| 图 268 | 脑的水平面 Horizon plane of the brain····· | 180 |
| 图 269 | 胼胝体 (上面观) The corpus callosum(superior aspect)····· | 181 |
| 图 270 | 大脑半球内主要联络纤维 Principal association fibers in the cerebral hemisphere····· | 181 |
| 图 271 | 脑的冠状面 Frontal plane of the brain····· | 182 |
| 图 272 | 纹状体与内囊 The corpus striatum and internal capsule····· | 182 |
| 图 273 | 侧脑室 (上面观) The lateral ventricle(superior aspect)····· | 183 |
| 图 274 | 脑室的铸型 A cast of the ventricle····· | 183 |
| 图 275 | 大脑半球外侧面的动脉 Arteries of the lateral surface of the cerebral hemisphere····· | 184 |
| 图 276 | 大脑半球内侧面的动脉 Arteries of the medial surface of the cerebral hemisphere····· | 184 |
| 图 277 | 脑底的动脉 Arteries at the base of the brain····· | 185 |
| 图 278 | 脑动脉 (冠状面) Cerebral artery(frontal plane)····· | 185 |
| 图 279 | 脑室造影像 (前后位) The ventriculogram(antero-posterior aspect)····· | 186 |
| 图 280 | 脑室造影像 (侧位) The ventriculogram(lateral aspect)····· | 186 |
| 图 281 | 脑动脉造影像 (前后位) The encephalo-arteriogram(antero-posterior aspect)····· | 186 |
| 图 282 | 脑动脉造影像 (侧位) The encephalo-arteriogram(lateral aspect)····· | 186 |
| 图 283 | 大脑半球外侧面的静脉 Veins of the lateral surface of the cerebral hemisphere····· | 187 |
| 图 284 | 脊髓的静脉 The veins of the spinal cord····· | 187 |
| 图 285 | 大脑深静脉 The deep cerebral veins····· | 187 |

| | | |
|-------|--|-----|
| 图 286 | 脊髓的动脉 The arteries of the spinal cord | 188 |
| 图 287 | 颅内外静脉的交通 Communication of the intra-extra cranial veins | 188 |
| 图 288 | 脊髓的血液供应 Blood supply of the spinal cord | 189 |
| 图 289 | 脊髓的被膜 Meninges of the spinal cord | 190 |
| 图 290 | 脑膜冠状解剖 The coronal dissection of meninge | 190 |
| 图 291 | 硬脑膜窦 The sinuses of dura mater | 191 |
| 图 292 | 海绵窦冠状面 Frontal plane of the cavernous sinus | 191 |
| 图 293 | 脑脊液循环示意图 Schematic diagram of cerebrospinal fluid circulation | 192 |
| 图 294 | 脑神经示意图 Schematic diagram of the cranial nerves | 193 |
| 图 295 | 眶及眶的内容物 (外侧面) The orbit and its contents(lateral aspect) | 194 |
| 图 296 | 眶及眶的内容物 (上面观) The orbit and its contents(superior aspect) | 194 |
| 图 297 | 三叉神经 (外侧面) The trigeminal nerve(lateral aspect) | 195 |
| 图 298 | 三叉神经 (内侧面) The trigeminal nerve(medial aspect) | 195 |
| 图 299 | 面神经在颞骨的分支 Branches of the facial nerve in temporal bone | 196 |
| 图 300 | 舌下神经 Hypoglossal nerve | 196 |
| 图 301 | 面神经 Facial nerve | 197 |
| 图 302 | 迷走神经 Vagus nerve | 198 |
| 图 303 | 副神经 Accessory nerve | 199 |
| 图 304 | 浅感觉传导路 Pathway of the superficial sensation | 200 |
| 图 305 | 本体感觉传导路 Pathway of the proprioceptive sense | 201 |
| 图 306 | 视觉传导路 The visual pathway | 202 |
| 图 307 | 听觉传导路 The auditory pathway | 203 |
| 图 308 | 平衡觉传导路 The equilibratory pathway | 204 |
| 图 309 | 嗅觉传导路 The olfactory pathway | 204 |
| 图 310 | 锥体系 (皮质脊髓束) The pyramidal system(corticospinal tract) | 205 |
| 图 311 | 锥体系 (皮质核束) The pyramidal system(corticonuclear tract) | 205 |
| 图 312 | 锥体交叉示意图 Schematic diagram of the pyramidal decussation | 206 |
| 图 313 | 内囊主要结构示意图 Schematic diagram of the main components in the internal capsule | 206 |
| 图 314 | 面神经瘫 Paralysis of the facial nerve | 206 |
| 图 315 | 舌下神经瘫 Paralysis of the hypoglossal nerve | 206 |
| 图 316 | 锥体外系 (纹状体 - 苍白球系统) The extrapyramidal system(strio-pallidal system) | 207 |
| 图 317 | 锥体外系 (皮质 - 脑桥 - 小脑系统) The extrapyramidal system(corticopontocerebellar system) | 207 |
| 图 318 | 交感神经系统示意图 Schematic diagram of the sympathetic nervous system | 208 |
| 图 319 | 自主神经系统概观 Scheme of general arrangement of autonomic nervous system | 209 |
| 图 320 | 交感系同脊神经和脊髓的关系示意图 Schematic diagram of relation of the sympathetic system to the spinal nerves and spinal cord | 210 |
| 图 321 | 头部自主神经系统分布示意图 Schematic diagram of distribution of the autonomic nervous system in the head | 210 |
| 图 322 | 腹部自主神经系统 Autonomic nervous system of abdomen | 211 |
| 图 323 | 心的神经支配和血压调节示意图 Schematic diagram of innervation of the heart and regulation of the blood pressure | 212 |
| 图 324 | 支气管、肺的神经支配和呼吸调节示意图 Schematic diagram of innervation of the bronchi, lungs and control of respiration | 212 |
| 图 325 | 膀胱的神经支配示意图 Schematic diagram of innervation of the urinary bladder | 213 |
| 图 326 | 肝、胆牵涉性痛的反射途径示意图 Schematic diagram of reflex tracts of the referred pain of the liver and gallbladder | 213 |
| 图 327 | 心脏牵涉性痛的反射途径示意图 Schematic diagram of reflex tracts of the referred pain of the heart | 213 |
| 图 328 | 眼球 The eyeball | 214 |
| 图 329 | 眼球冠状面 (后面观) The eyeball sectioned in frontal plane (posterior aspect) | 215 |
| 图 330 | 眼球前部的断面 Sectioned of the anterior part of the eyeball | 215 |

| | | |
|-------|---|-----|
| 图 331 | 眼底镜所见 (右侧) Ophthalmoscopic view of fundus of the eyeball(right side) | 215 |
| 图 332 | 眼球水平面 Horizon plane of the eyeball | 216 |
| 图 333 | 右眼眶隔 The orbital septum of the right eye | 216 |
| 图 334 | 右眼 (前面观) The right eye(anterior aspect) | 217 |
| 图 335 | 泪器 (右侧) The lacrimal apparatus(right side) | 217 |
| 图 336 | 眼球外肌 The ocular muscles | 218 |
| 图 337 | 眼球的血管神经分布示意图 Schematic diagram of distribution of the blood vessels and nerves of the eyeball | 219 |
| 图 338 | 眼球的动脉供应及静脉回流示意图 Schematic diagram of the arterial supply and venous drainage of the eyeball | 219 |
| 图 339 | 声音的感受途径 Pathway of sound reception | 220 |
| 图 340 | 耳郭 The auricle | 221 |
| 图 341 | 右鼓膜 The right tympanic membrane | 221 |
| 图 342 | 外耳道和中耳的冠状面 Frontal plane of external acoustic meatus and middle ear | 221 |
| 图 343 | 鼓膜切除后鼓室 Tympanic cavity after removal of tympanic membrane | 221 |
| 图 344 | 听小骨 The auditory ossicles | 221 |
| 图 345 | 鼓室外侧壁 (内面观) Lateral wall of tympanic cavity(medial aspect) | 222 |
| 图 346 | 鼓室内侧壁 (外侧面观) Medial wall of tympanic cavity(lateral aspect) | 222 |
| 图 347 | 右侧骨迷路 Right bony labyrinth | 223 |
| 图 348 | 右侧骨迷路内面 Interior of the right bony labyrinth | 223 |
| 图 349 | 右侧膜迷路 (后内侧面) Right membranous labyrinth (postero-medial aspect) | 223 |
| 图 350 | 迷路的血管 (后内侧面) Blood vessels of the labyrinth (postero-medial aspect) | 224 |
| 图 351 | 螺旋器水平面 Horizon plane of the spiral organ | 224 |
| 图 352 | 骨迷路与膜迷路示意图 Schematic diagram of bony and membranous labyrinths | 225 |
| 图 353 | 嗅区 The olfactory region | 225 |
| 图 354 | 味器及其神经分布 The gustatory organ and its innervation | 226 |
| 图 355 | 皮肤 The skin | 226 |
| 图 356 | 指甲 The nail of finger | 227 |
| 图 357 | 内分泌腺 The endocrine glands | 227 |
| 图 358 | 胸腺 The thymus | 228 |
| 图 359 | 肾上腺 The suprarenal glands | 228 |
| 图 360 | 垂体的血管供应 Blood supply of the hypophysis | 229 |
| 图 361 | 垂体的分部 Divisions of the hypophysis | 229 |
| 图 362 | 甲状腺 (前面观) The thyroid gland(anterior aspect) | 230 |
| 图 363 | 甲状旁腺 (后面观) The parathyroid gland(posterior aspect) | 230 |
| 图 364 | 头颈部左侧面的肌肉、血管和神经 (1) Muscles, blood vessels and nerves of left lateral aspect of the head and neck(1) | 231 |
| 图 365 | 头颈部左侧面的肌肉、血管和神经 (2) Muscles, blood vessels and nerves of left lateral aspect of the head and neck(2) | 232 |
| 图 366 | 头颈部左侧面的肌肉、血管和神经 (3) Muscles, blood vessels and nerves of left lateral aspect of the head and neck(3) | 233 |
| 图 367 | 颈斜角肌和椎前肌 Scalenus and prevertebral muscles | 234 |
| 图 368 | 翼肌 Pterygoid | 234 |
| 图 369 | 头皮及颅的冠状面 Frontal plane of the scalp and cranium | 234 |
| 图 370 | 颈部水平面 Horizon plane of the neck | 235 |
| 图 371 | 颈筋膜矢状面 Sagittal plane of cervical fascia | 235 |
| 图 372 | 背部的肌肉和神经 (1) Muscles and nerves of the back(1) | 236 |
| 图 373 | 背部的肌肉和神经 (2) Muscles and nerves of the back(2) | 237 |
| 图 374 | 背部的肌肉和神经 (3) Muscles and nerves of the back(3) | 238 |
| 图 375 | 背部的肌肉和神经 (4) Muscles and nerves of the back(4) | 239 |
| 图 376 | 胸腹壁的肌肉、血管和神经 (1) Muscles, blood vessels and nerves of the thoracic and abdominal wall(1) | 240 |
| 图 377 | 胸腹壁的肌肉、血管和神经 (2) | |

| | | |
|-------|--|-----|
| | Muscles, blood vessels and nerves of the thoracic and abdominal wall(2) | 241 |
| 图 378 | 胸腹壁的肌肉、血管和神经 (3) | |
| | Muscles, blood vessels and nerves of the thoracic and abdominal wall(3) | 242 |
| 图 379 | 胸腹壁的肌肉、血管和神经 (4) | |
| | Muscles, blood vessels and nerves of the thoracic and abdominal wall(4) | 243 |
| 图 380 | 胸廓前壁 (外面观) Anterior wall of thoracic cage(external aspect) | 244 |
| 图 381 | 胸廓前壁 (内面观) Anterior wall of thoracic cage(internal aspect) | 245 |
| 图 382 | 胸壁 The thoracic wall | 246 |
| 图 383 | 纵隔 (右侧) The mediastinum(right aspect) | 247 |
| 图 384 | 纵隔 (左侧) The mediastinum(left aspect) | 248 |
| 图 385 | 胸部水平面 Horizon plane of the thoracic part | 249 |
| 图 386 | 腹部水平面 Horizon plane of the abdominal part | 249 |
| 图 387 | 腹股沟管 (1) The inguinal canal (1) | 250 |
| 图 388 | 腹股沟管 (2) The inguinal canal (2) | 250 |
| 图 389 | 腹股沟管 (3) The inguinal canal (3) | 251 |
| 图 390 | 腹股沟斜疝 The indirect inguinal hernia | 252 |
| 图 391 | 腹上部器官和腹腔干及其分支 (1) | |
| | The organs of the upper abdomen and the celiac trunk and its branches(1) | 253 |
| 图 392 | 腹上部器官和腹腔干及其分支 (2) | |
| | The organs of the upper abdomen and the celiac trunk and its branches(2) | 253 |
| 图 393 | 小肠、大肠和肠系膜上动脉 | |
| | The small and large intestines and the superior mesenteric artery | 254 |
| 图 394 | 小肠、大肠和肠系膜下动脉 | |
| | The small and large intestines and the inferior mesenteric artery | 255 |
| 图 395 | 盆腔的血管 (男性) Blood vessels of the pelvic cavity(male) | 256 |
| 图 396 | 盆腔的血管 (女性) Blood vessels of the pelvic cavity(female) | 257 |
| 图 397 | 男性会阴血管和神经 Blood vessels and nerves of the male perineum | 258 |
| 图 398 | 女性会阴血管和神经 Blood vessels and nerves of the female perineum | 259 |
| 图 399 | 腹后壁的神经 The nerves of the posterior abdominal wall | 260 |
| 图 400 | 腋窝的肌肉、血管和神经 | |
| | Muscles, blood vessels and nerves of the axillary fossa | 261 |
| 图 401 | 颈动脉 Carotid artery | 262 |
| 图 402 | 腋窝矢状面 Sagittal plane of the axillary fossa | 262 |
| 图 403 | 上肢的皮神经和浅静脉 (1) | |
| | Cutaneous nerves and superficial veins of the upper limb(1) | 263 |
| 图 404 | 上肢的皮神经和浅静脉 (2) | |
| | Cutaneous nerves and superficial veins of the upper limb(2) | 264 |
| 图 405 | 肩及臂的肌肉、血管和神经 (1) | |
| | Muscles, blood vessels and nerves of the shoulder and arm(1) | 265 |
| 图 406 | 肩及臂的肌肉、血管和神经 (2) | |
| | Muscles, blood vessels and nerves of the shoulder and arm(2) | 266 |
| 图 407 | 前臂的肌肉、血管和神经 (1) | |
| | Muscles, blood vessels and nerves of the forearm(1) | 267 |
| 图 408 | 前臂的肌肉、血管和神经 (2) | |
| | Muscles, blood vessels and nerves of the forearm(2) | 268 |
| 图 409 | 前臂的肌肉、血管和神经 (3) | |
| | Muscles, blood vessels and nerves of the forearm(3) | 269 |
| 图 410 | 前臂的肌肉、血管和神经 (4) | |
| | Muscles, blood vessels and nerves of the forearm(4) | 270 |
| 图 411 | 前臂连续水平面 The serial horizon planes of forearm | 271 |
| 图 412 | 手掌的肌肉、血管和神经 (1) | |
| | Muscles, blood vessels and nerves of the palm of hand(1) | 272 |
| 图 413 | 手掌的肌肉、血管和神经 (2) | |
| | Muscles, blood vessels and nerves of the palm of hand(2) | 273 |

| | | | |
|-------|--|---|-----|
| 图 414 | 手掌的肌肉、血管和神经 (3) | Muscles, blood vessels and nerves of the palm of hand(3) | 274 |
| 图 415 | 手掌的肌肉、血管和神经 (4) | Muscles, blood vessels and nerves of the palm of hand(4) | 275 |
| 图 416 | 手的滑膜囊、间隙和腱鞘 | Synovial bursa, spaces and tendinous sheaths of hand | 276 |
| 图 417 | 下肢的皮神经和浅静脉 (1) | Cutaneous nerves and superficial veins of the lower limb (1) | 277 |
| 图 418 | 下肢的皮神经和浅静脉 (2) | Cutaneous nerves and superficial veins of the lower limb (2) | 278 |
| 图 419 | 大腿前内侧面的肌肉、血管和神经 (1) | Muscles, blood vessels and nerves of antero-medial aspect of the thigh(1) | 279 |
| 图 420 | 大腿前内侧面的肌肉、血管和神经 (2) | Muscles, blood vessels and nerves of antero-medial aspect of the thigh(2) | 280 |
| 图 421 | 大腿前内侧面的肌肉、血管和神经 (3) | Muscles, blood vessels and nerves of antero-medial aspect of the thigh(3) | 281 |
| 图 422 | 大腿连续水平面 The serial horizon planes of thigh | | 282 |
| 图 423 | 髋和臀部的神经 Nerves of hip and buttock | | 283 |
| 图 424 | 股神经和股外侧皮神经 Femoral nerve and lateral femoral cutaneous nerve | | 284 |
| 图 425 | 小腿前外侧面及足背的肌肉、血管和神经 (1) | Muscles, blood vessels and nerves of antero-lateral aspect of the leg and dorsum of foot(1) | 285 |
| 图 426 | 小腿前外侧面及足背的肌肉、血管和神经 (2) | Muscles, blood vessels and nerves of antero-lateral aspect of the leg and dorsum of foot(2) | 286 |
| 图 427 | 小腿前外侧面及足背的肌肉、血管和神经 (3) | Muscles, blood vessels and nerves of antero-lateral aspect of the leg and dorsum of foot(3) | 287 |
| 图 428 | 小腿前外侧面及足背的肌肉、血管和神经 (4) | Muscles, blood vessels and nerves of antero-lateral aspect of the leg and dorsum of foot(4) | 288 |
| 图 429 | 小腿的肌肉、血管和神经 (1) | Muscles, blood vessels and nerves of posterior aspect of the leg(1) | 289 |
| 图 430 | 小腿的肌肉、血管和神经 (2) | Muscles, blood vessels and nerves of posterior aspect of the leg(2) | 290 |
| 图 431 | 小腿的肌肉、血管和神经 (3) | Muscles, blood vessels and nerves of posterior aspect of the leg(3) | 291 |
| 图 432 | 小腿上部的水平面和骨筋膜鞘 | The horizon plane and osseofascial compartments of leg | 292 |
| 图 433 | 足的腱滑膜鞘 | The synovial sheaths of the tendons of foot | 293 |
| 图 434 | 足底的肌肉、血管和神经 (1) | Muscles, blood vessels and nerves of the sole of foot(1) | 294 |
| 图 435 | 足底的肌肉、血管和神经 (2) | Muscles, blood vessels and nerves of the sole of foot(2) | 295 |
| 图 436 | 足底的肌肉、血管和神经 (3) | Muscles, blood vessels and nerves of the sole of foot(3) | 296 |
| 参考文献 | | | 297 |

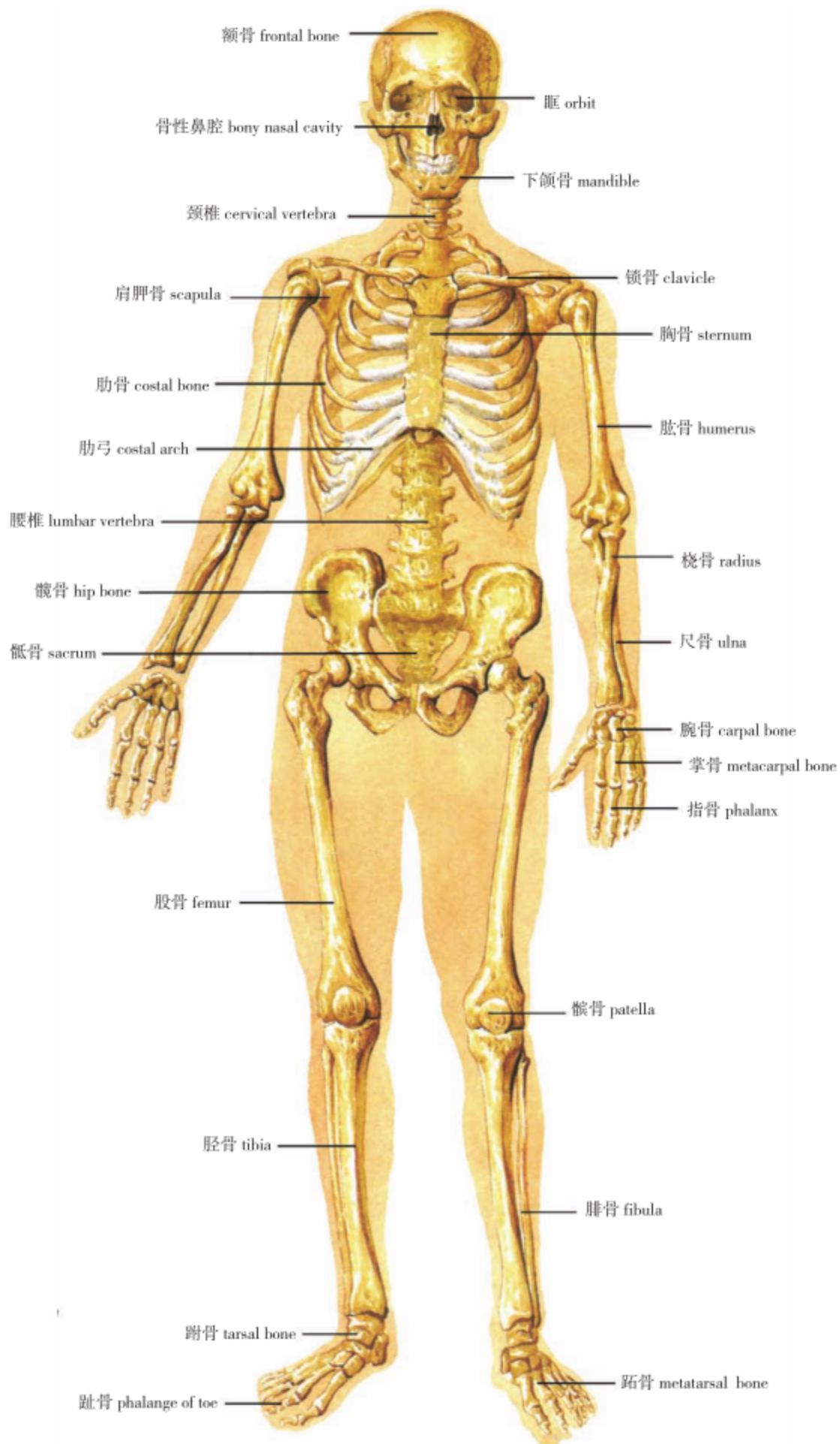


图 1 全身骨骼 (前面观)
The skeleton (anterior aspect)

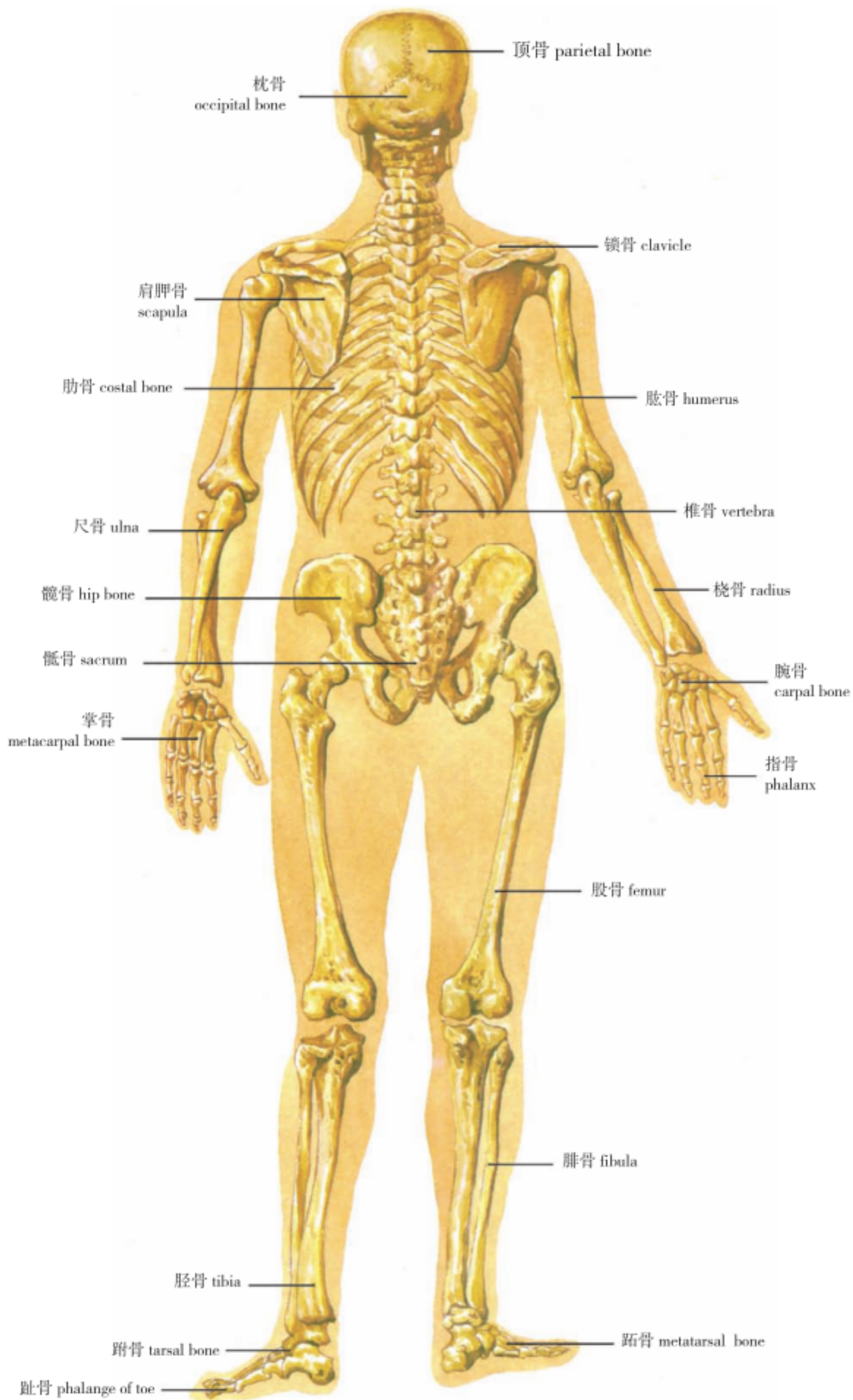
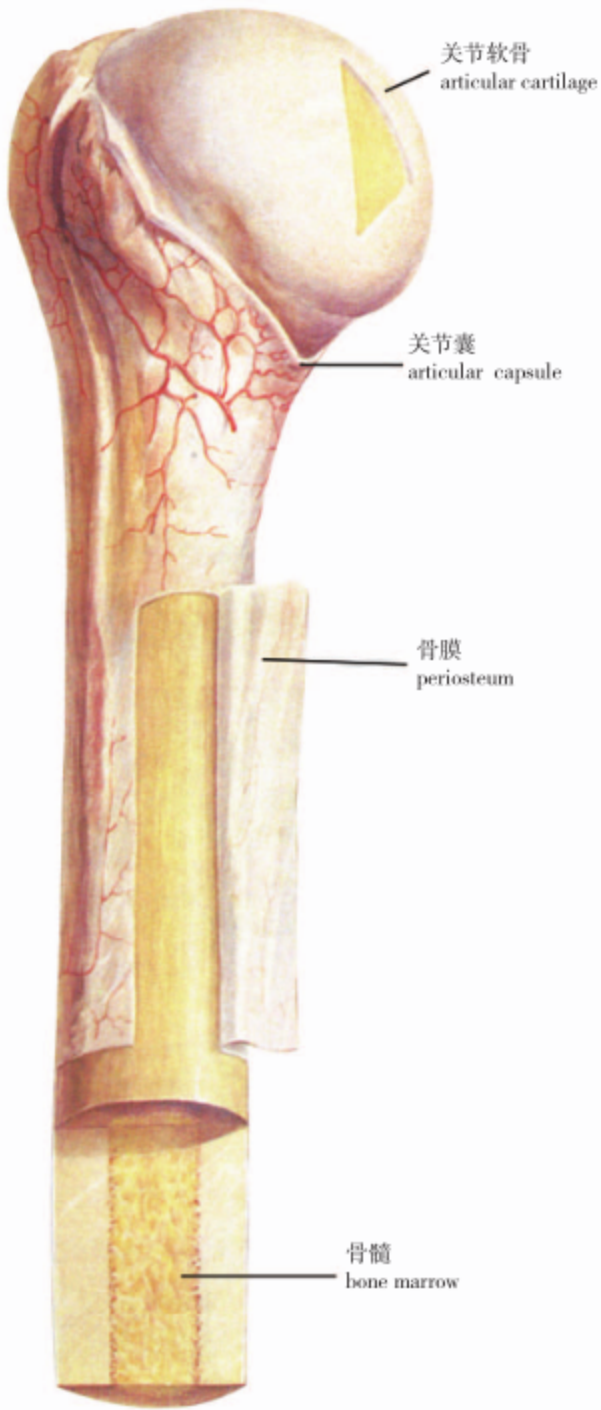
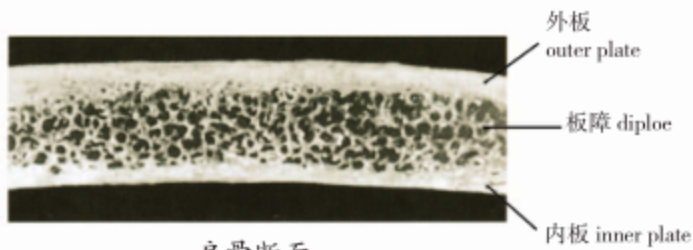


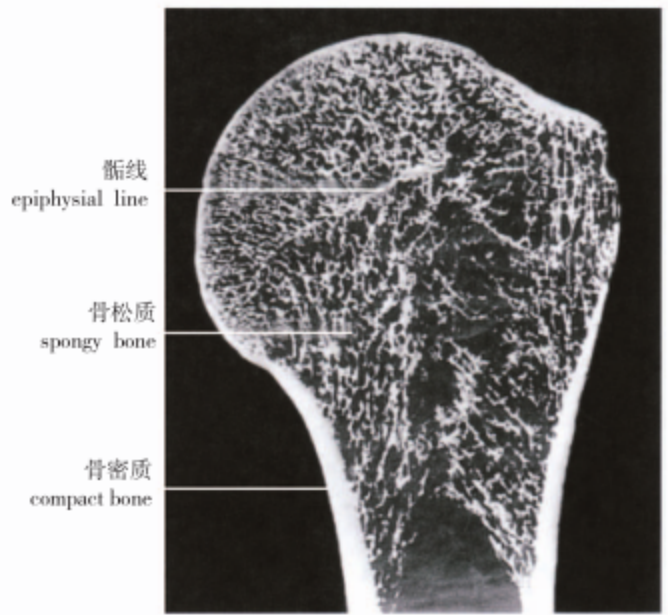
图 2 全身骨骼 (后面观)
The skeleton (posterior aspect)



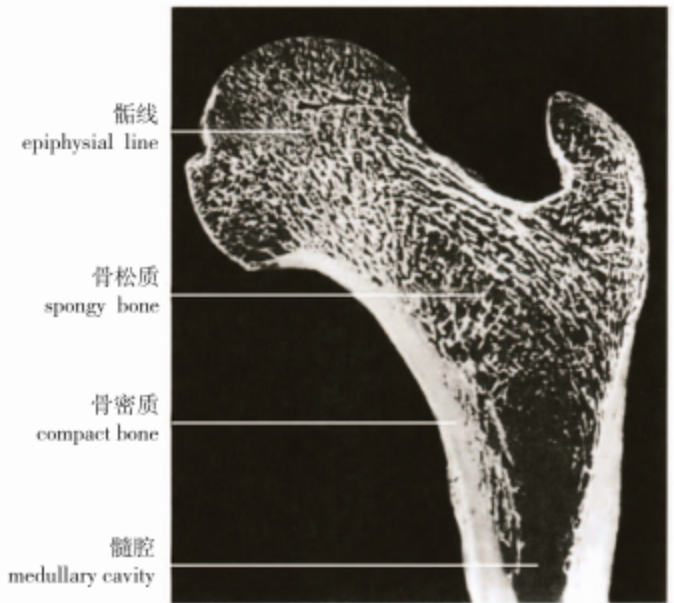
新鲜骨的构造
structure of a living bone



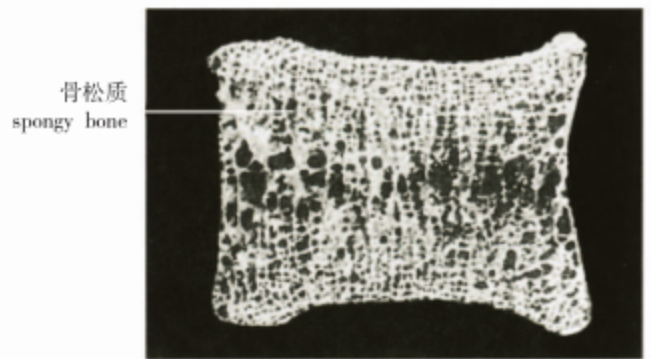
扁骨断面
section of flat bone



肱骨上端冠状面
frontal plane of the upper end of humerus



股骨上端冠状面
frontal plane of the upper end of femur



椎体冠状面
frontal plane of the body of vertebral body

图3 骨的构造
Structure of the bone