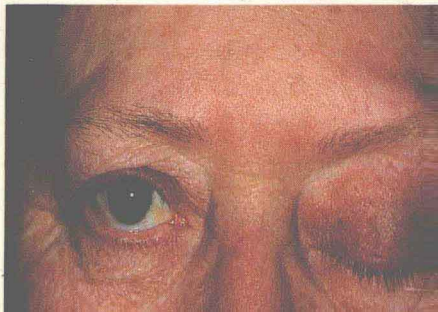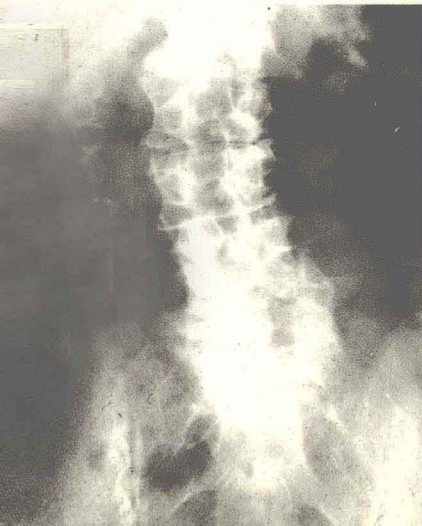
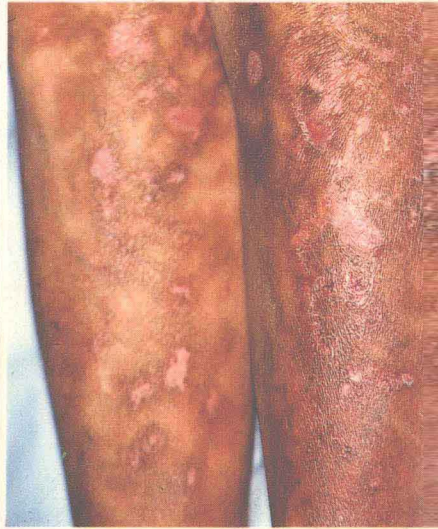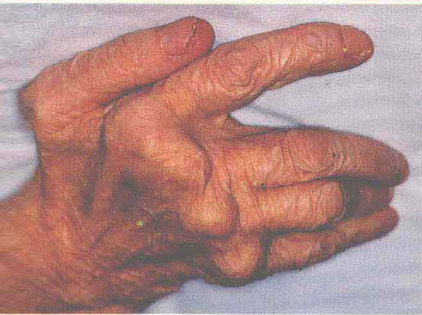


DIAGNOSTIC PICTURE TESTS IN

GERIATRIC MEDICINE

Asif Kamal



DIAGNOSTIC PICTURE TESTS IN

GERIATRIC MEDICINE

ASIF KAMAL

FRCP (Lond)

Consultant Physician in Geriatric Medicine
St George's Hospital, Lincoln



YEAR BOOK MEDICAL PUBLISHERS, INC.

Titles in this series, published or being developed, include:

Diagnostic Picture Tests in Pediatrics

Picture Tests in Human Anatomy

Diagnostic Picture Tests in Oral Medicine

Diagnostic Picture Tests in Orthopedics

Diagnostic Picture Tests in Infectious Diseases

Diagnostic Picture Tests in Dermatology

Diagnostic Picture Tests in Ophthalmology

Diagnostic Picture Tests in Rheumatology

Diagnostic Picture Tests in Obstetrics/Gynecology

Diagnostic Picture Tests in Neurology

Diagnostic Picture Tests in Sports Injuries

Picture Tests in Surgical Diagnosis

Diagnostic Picture Tests in Cardiology

Copyright © A. Kamal, 1990

Published by Wolfe Medical Publications Ltd, 1990

Printed by W.S. Cowell Ltd, Ipswich, England

ISBN 0-8151-4981-6

This book is copyrighted in England and may not be reproduced by any means in whole or part. Distributed in North America, Canada, Hawaii and Puerto Rico by Year Book Medical Publishers, Inc. by arrangement with Wolfe Medical Publications Ltd.

DIAGNOSTIC PICTURE TESTS IN

GERIATRIC MEDICINE

ASIF KAMAL

FRCP (Lond)

Consultant Physician in Geriatric Medicine
St George's Hospital, Lincoln



YEAR BOOK MEDICAL PUBLISHERS, INC.

Titles in this series, published or being developed, include:

Diagnostic Picture Tests in Pediatrics
Picture Tests in Human Anatomy
Diagnostic Picture Tests in Oral Medicine
Diagnostic Picture Tests in Orthopedics
Diagnostic Picture Tests in Infectious Diseases
Diagnostic Picture Tests in Dermatology
Diagnostic Picture Tests in Ophthalmology
Diagnostic Picture Tests in Rheumatology
Diagnostic Picture Tests in Obstetrics/Gynecology
Diagnostic Picture Tests in Neurology
Diagnostic Picture Tests in Sports Injuries
Picture Tests in Surgical Diagnosis
Diagnostic Picture Tests in Cardiology

Copyright © A. Kamal, 1990

Published by Wolfe Medical Publications Ltd, 1990

Printed by W.S. Cowell Ltd, Ipswich, England

ISBN 0-8151-4981-6

This book is copyrighted in England and may not be reproduced by any means in whole or part. Distributed in North America, Canada, Hawaii and Puerto Rico by Year Book Medical Publishers, Inc. by arrangement with Wolfe Medical Publications Ltd.

Preface

Clinical presentation of disease in old age is often unique, and usually different from similar conditions in younger patients. Together with the fact that elderly patients also show changes of ageing and of multiple pathology, this tends to make accurate clinical assessment both challenging and at times difficult. This is one reason why this speciality has a special status within the field of general medicine. The range of illustrations in this volume is as broad as possible, reflecting the great variety of signs seen in geriatric medicine.

This book is intended for all medical and paramedical personnel who are involved in the clinical management of elderly patients - especially undergraduate and postgraduate medical students, junior hospital doctors and general practitioners. It should be used as a tool for revising the clinical aspects of medicine in old age. It should also be of value to those preparing for examinations, particularly the MRCP exams and Diploma in Geriatric Medicine.

The answers to the questions are given as general guidelines and should serve as useful starting points for further discussion.

A. Kamal
Lincoln

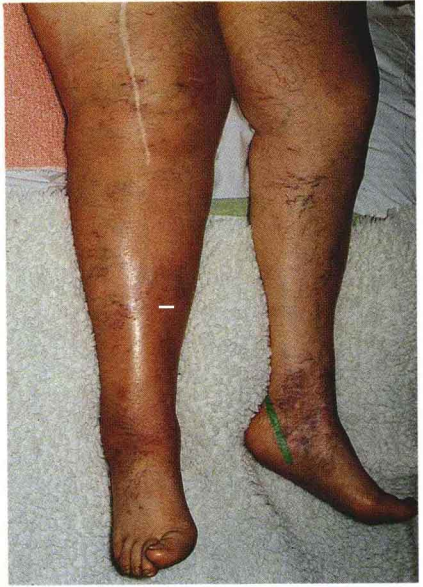Author's acknowledgements

My thanks to Dr Simon Leach for providing illustrations **9** and **149**, to Dr T. Powell for **16, 21, 42, 52, 113, 127, 152, 156**, to Dr Leeming for **29**, to Mr Lamerton for **34**, to Dr Scott for **48** and **106**, to Dr Prangnell for **68, 118, 139, 170** and to Boehringer Ingelheim Ltd for **81, 169** and **182**.

My special thanks to Glenise de Lacy for typing the manuscript and to the Department of Medical Illustrations at St George's Hospital, Lincoln, for taking many of the pictures in this volume.

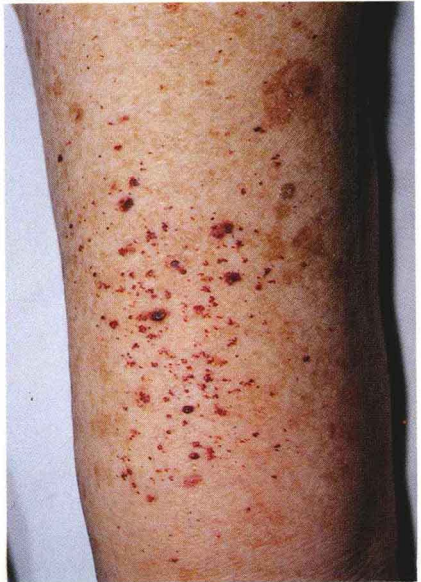1 This elderly patient was admitted with pain and swelling in the right leg. She gave past medical history of right knee replacement.

- (a) Give two likely diagnoses.
(b) What complications may occur in this case?

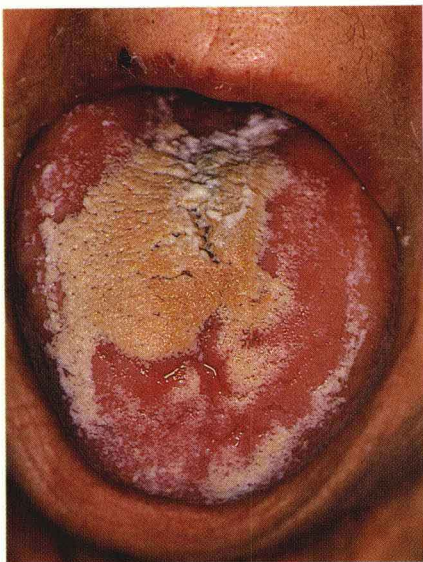


2 (a) Give four causes of this condition.

- (b) What investigations are indicated?



3



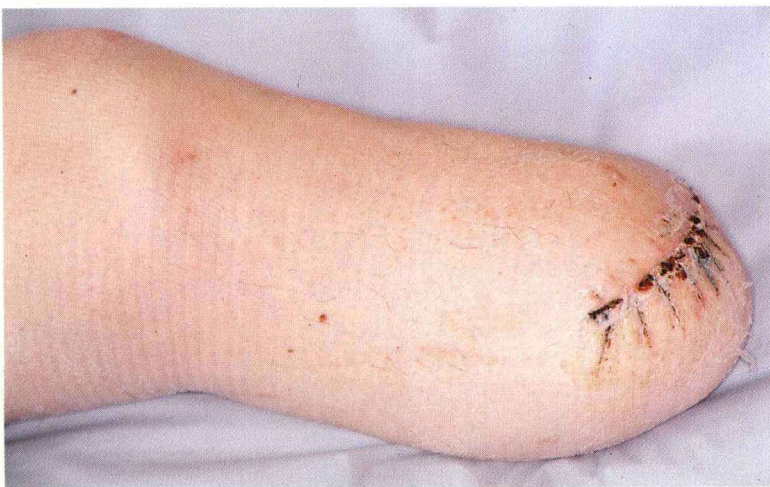3 This 80 year old patient has a painful mouth.

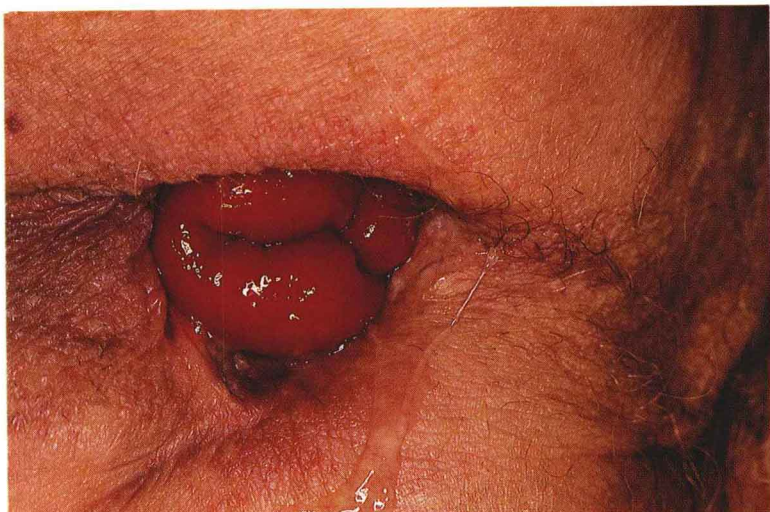
- (a) What is the diagnosis?
- (b) What may be the underlying condition?

4 This elderly man underwent below knee amputation for severe peripheral vascular disease.

- (a) What are the main elements of post-operative rehabilitation?
- (b) What long term problems might occur in this patient?

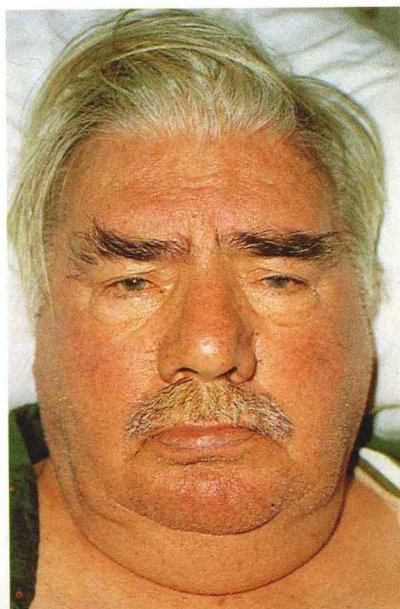
4



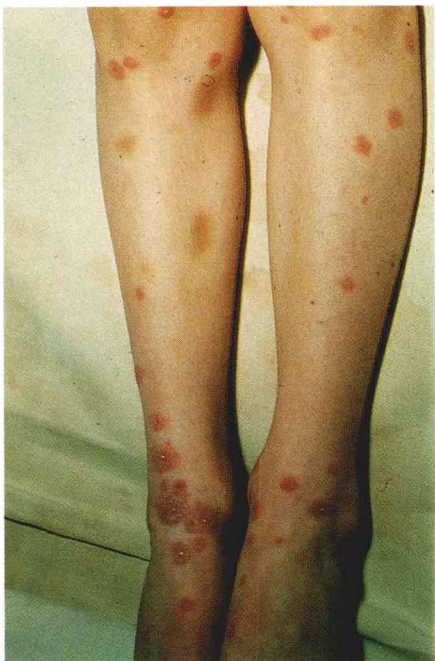

- 5 (a) What is this condition?
 (b) What complications might occur?

- 6 This elderly man was admitted with a history of headaches and hypertension.
 (a) What diagnosis is suggested by the facial appearance?
 (b) What are the causes of this syndrome?

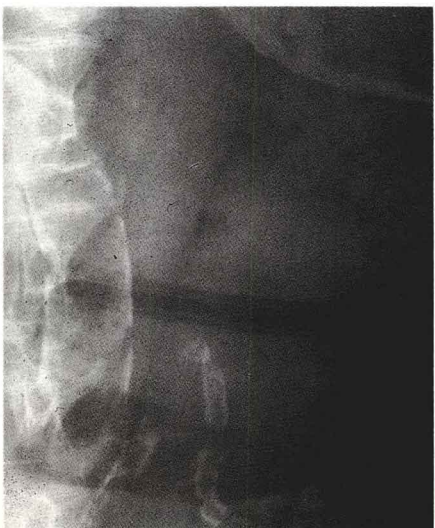

7

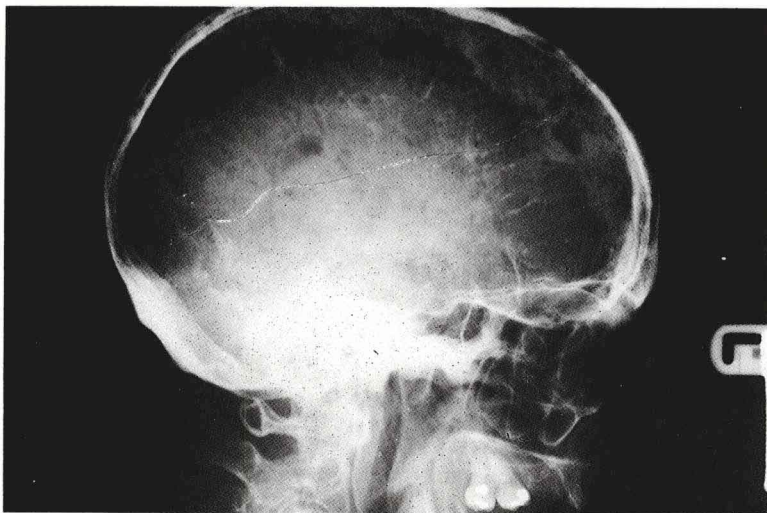


- 7 (a) What is this skin condition?
(b) What are the clinical features of Stevens-Johnson syndrome?

8



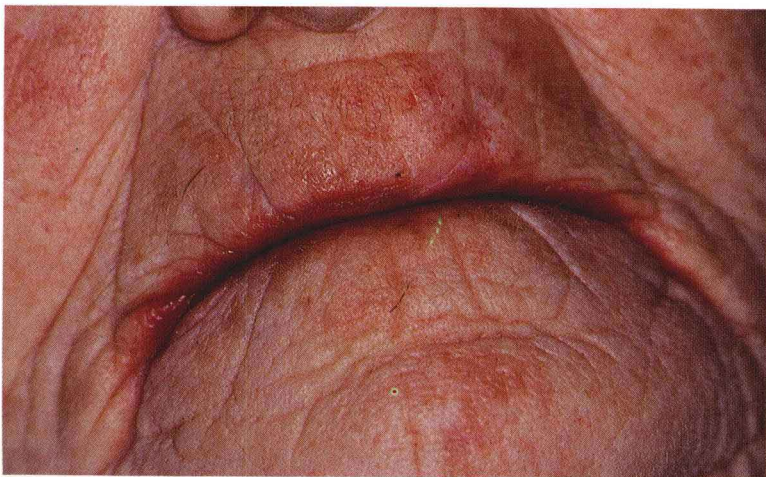
- 8 (a) What abnormality is seen in this plain X-ray of the abdomen?
(b) Are further investigations necessary?



9

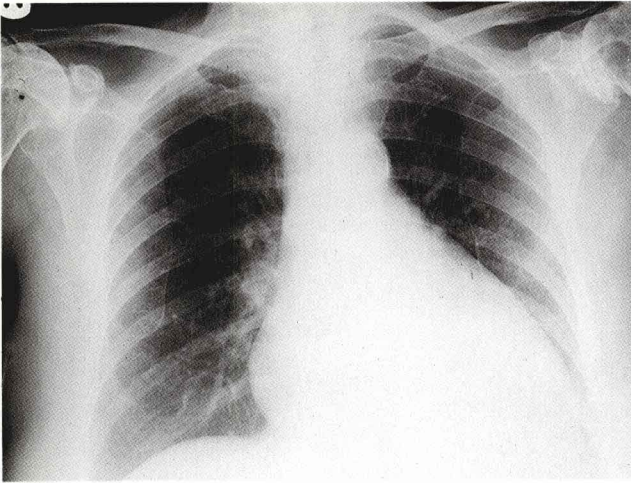
- 9 (a) What investigations are necessary after seeing this skull X-ray?
(b) What problems may this patient experience?

- 10 (a) What is this condition?
(b) Which investigations are required?



10

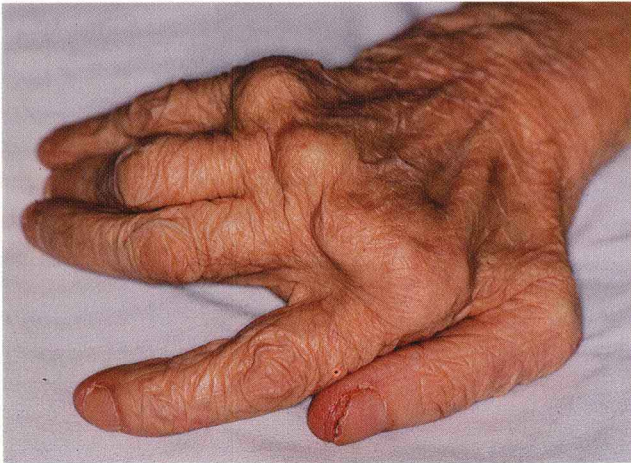11

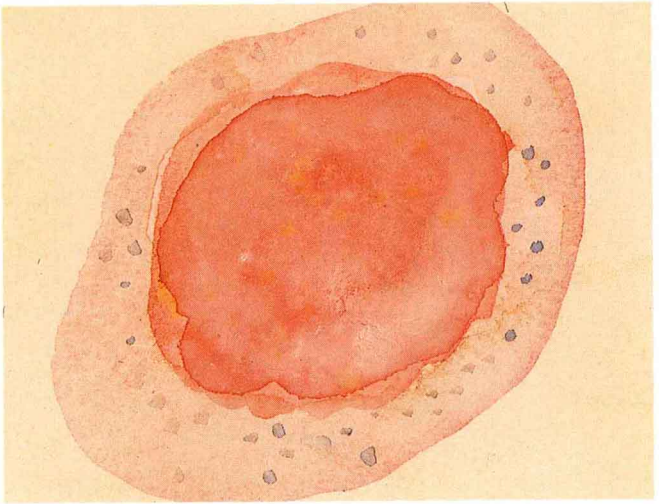


- 11** This chest X-ray is of a 70 year old patient who complains of dyspnoea on exertion of long standing and has suffered one minor stroke.
- (a) What are the typical auscultatory findings in such cases?
 - (b) Name the complications that can occur in this patient?

- 12** (a) Identify the abnormalities seen in this hand.
- (b) What are the special features of this disorder in the elderly?

12





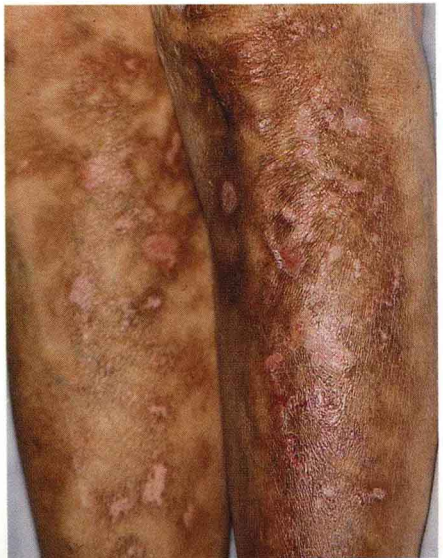13

13 An erythroblast from the bone marrow of an 80 year old with anaemia.

- (a) Which drugs can cause this type of anaemia?
- (b) Describe the typical features of this anaemia.

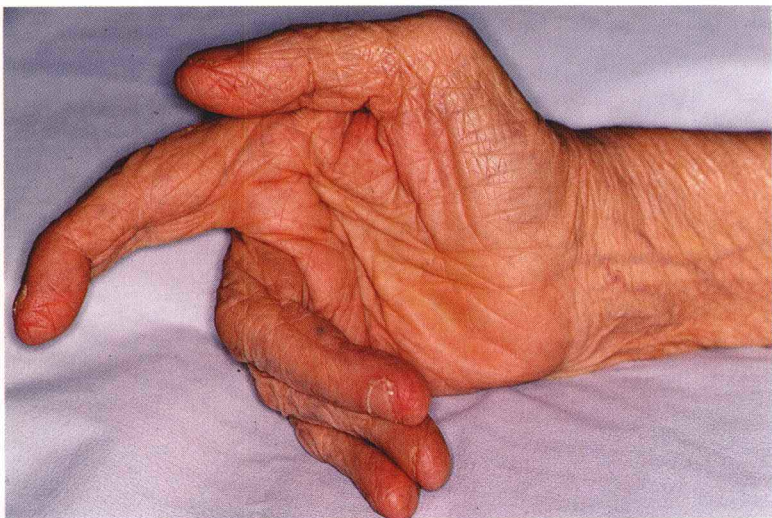
14 This skin condition was seen in a 90 year old patient.

- (a) What does this condition tell us about the woman's living conditions?
- (b) Which investigations are necessary?



14

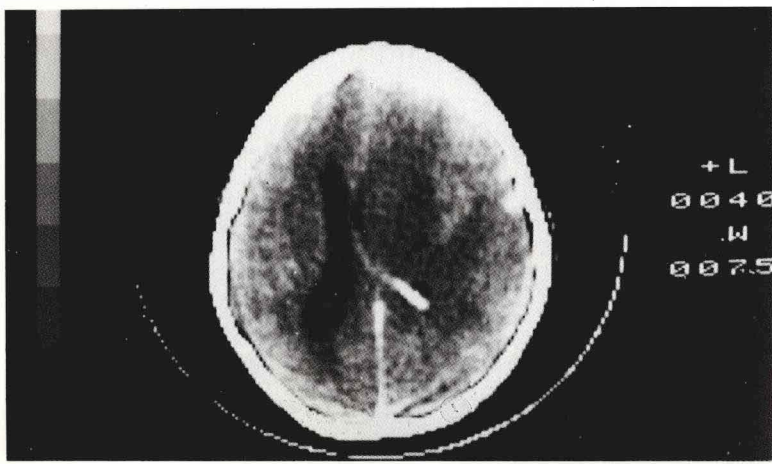
15



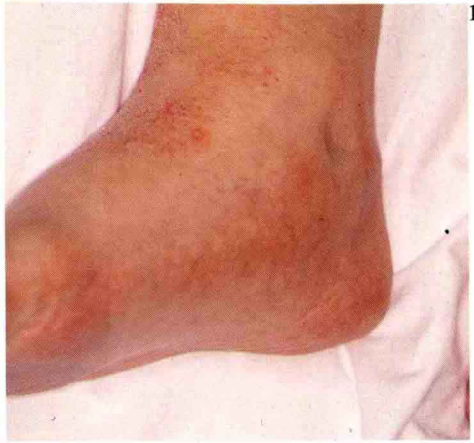- 15 (a) What is this condition?
- (b) Which disorders are associated with this abnormality?
- (c) What is the preferred surgical treatment?

- 16 (a) Describe the clinical features which may be present in this patient.
- (b) How should this case be managed?

16

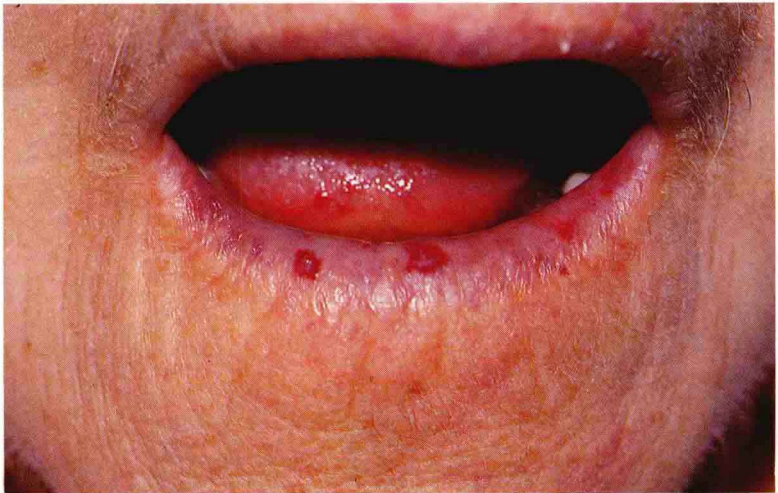

17 This elderly patient has chronic oedema of the feet.
(a) What are the likely causes?
(b) What are the common side-effects of diuretics used to treat such cases?



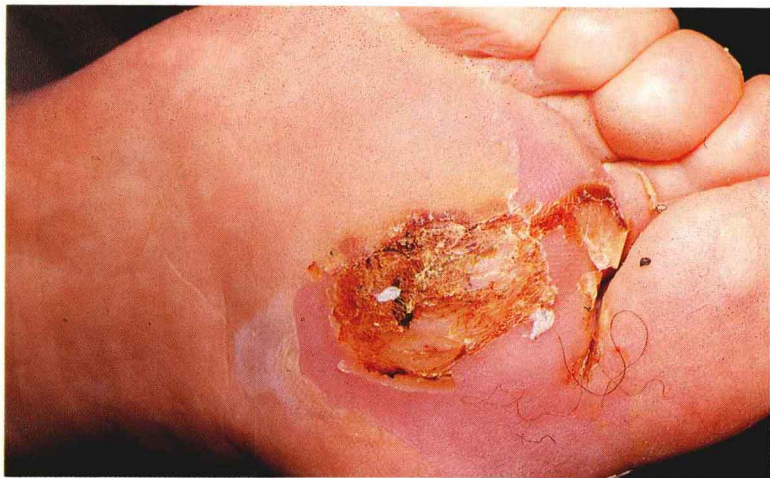17

18 (a) What is this condition called?
(b) What symptoms may be present in this patient?



18

19

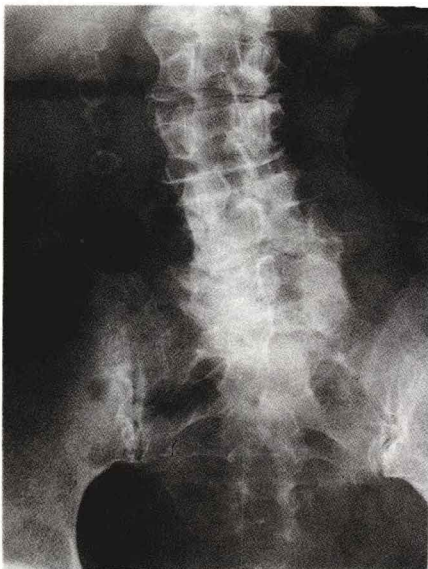


19 This 75 year old woman was admitted with recurrent falls.

(a) What is the most likely cause of her falls?

(b) What are the commonest environmental causes of recurrent falls in old age?

20



20 (a) What symptoms might this patient have?

(b) What are the different types of gall stones seen in elderly people?