

Diseases of the Ears, Nose, and Throat

A Guide to Diagnosis and
Management

D. THANE R. CODY, M.D., C.M., Ph.D.

EUGENE B. KERN, M.D., M.S.

BRUCE W. PEARSON, M.D., F.R.C.S.(C.)

Diseases of the Ears, Nose, and Throat

A Guide to Diagnosis and Management

D. THANE R. CODY, M.D., C.M., Ph.D.

Professor of Otolaryngology
Mayo Medical School;
Chairman, Department of Otolaryngology
Mayo Clinic
Rochester, Minnesota

EUGENE B. KERN, M.D., M.S.

Associate Professor of Otolaryngology
Mayo Medical School;
Consultant, Department of Otolaryngology
Mayo Clinic
Rochester, Minnesota

BRUCE W. PEARSON, M.D., F.R.C.S.(C.)

Assistant Professor of Otolaryngology and Anatomy
Mayo Medical School;
Consultant, Department of Otolaryngology
Mayo Clinic
Rochester, Minnesota



YEAR BOOK MEDICAL PUBLISHERS, INC.
CHICAGO • LONDON

Copyright © 1981 by Mayo Foundation. All rights reserved. No part of this publication may be reproduced, stored in a retrieval system, or transmitted, in any form or by any means, electronic, mechanical, photocopying, recording, or otherwise, without prior written permission from the publisher. Printed in the United States of America.

Library of Congress Cataloging in Publication Data

Cody, D Thane R 1932-

Diseases of the ears, nose, and throat.

Includes index.

I. Otolaryngology. I. Kern, Eugene B., joint author. II. Pearson, Bruce W., joint author. III. Title. [DNLM: 1. Otorhinolaryngologic diseases—Diagnosis. 2. Otorhinolaryngologic diseases—Therapy. WV100 C671d]

RF46.C665 617'.51 80-23387

ISBN 0-8151-1798-1

Preface

Various surveys have revealed that a substantial portion of the primary care physician's practice is concerned with diseases and disorders of the ears, nose, and throat (ENT). Despite the involvement of this large segment of the medical profession in the treatment of patients with ENT complaints, to our knowledge, there is no book devoted to this subject that has been written specifically for these physicians. The purpose of this book is to fill that void.

The emphasis is on the differential diagnosis of the ENT symptoms. The history, the physical examination, and the practical management of the problem are overriding concerns. This is a radical departure from the usual medical text format, but physicians find the office patient a radical departure from the medical text. The book is designed to facilitate the recall of possible causes of an initial symptom and the arrival at the correct diagnosis. The book is completely clinically oriented. Anatomy, embryology, and physiology are not discussed in any detail, since this information is readily available in standard ENT textbooks. References have been kept to a minimum and are only included when it seemed possible that the reader might wish to obtain additional information on a subject.

It is our sincere hope that the purpose in writing this book has been achieved and that the primary care physician will find it valuable in the management of this important part of his practice.

D. THANE R. CODY
EUGENE B. KERN
BRUCE W. PEARSON

Contents

PART I

DISEASES AND DISORDERS OF THE EARS,

<i>D. Thane R. Cody</i>	1
1. Examination of the Ear	3
The History	3
The Examination	4
Hearing Tests	10
Middle Ear Impedance Measurements (Impedance Audiometry)	15
Vestibular Tests	16
2. Vestibular Dizziness: Vertigo	21
Chronic Vertigo	22
A Single Spontaneous Long Episode of Vertigo ...	22
Recurrent Spontaneous Attacks of Vertigo	31
Postural Vertigo	45
Postural Vertigo Due to a Vestibular Labyrinth or Nerve Disorder	45
Postural Vertigo Due to a Vestibular Nuclei- Cerebellar Complex Disorder	49
Vertigo Caused by Pressing on the Ear	50
Summary	51
3. Vestibular Dizziness: Imbalance (Disequilibrium)	
Without Vertigo	53
Chronic Imbalance	53
Vestibular Disorders	53
Nonvestibular Disorders	60
A Single Spontaneous Long Episode of Imbalance	62
Recurrent Spontaneous Attacks of Imbalance	62
Postural Imbalance	63
Summary	66

4. Hearing Loss without Otoscope Abnormalities	74
Congenital Hearing Loss	75
Alport's Syndrome	77
Otosclerosis (Otospongiosis)	77
Paget's Disease	80
Viral Labyrinthitis	81
Meningitic Suppurative Labyrinthitis	82
Latent Congenital Syphilitic Endolymphatic Hydrops	83
Temporal Bone Trauma	83
Noise Trauma	83
Presbycusis	85
Aminoglycoside Antibiotic Ototoxicity	85
Aspirin Ototoxicity	85
Ménière's Disease (Idiopathic Endolymphatic Hydrops)	86
Inner Ear Vascular Accidents	86
Perilymph Fistula	86
Cogan's Syndrome (Nonsyphilitic Interstitial Keratitis with Vestibuloauditory Symptoms)	87
Myxedema	87
Petrous Apex Congenital Cholesteatoma (Epidermoid Cyst)	87
Acoustic Neuroma (Neurilemmoma)	88
Posterior Fossa Meningioma	89
Multiple Sclerosis (Disseminated Sclerosis)	90
Functional (Nonorganic) Hearing Loss	90
5. Hearing Loss with Oscope Abnormalities	92
Congenital Atresia of the External Auditory Canal	92
Impacted Cerumen	93
Exostoses and Osteoma of the Ear Canal	94
Middle Ear Congenital Cholesteatoma (Epidermoid Cyst)	94
Secretory and Serous Otitis Media	95
Idiopathic Hemotympanum (Blue Eardrum)	99
Acute Suppurative Otitis Media	100
Herpes Zoster Oticus Labyrinthitis (Ramsey Hunt's Syndrome)	100
Chronic Suppurative Otitis Media	100

Otologic Suppurative Labyrinthitis	101
Aerotitis Media (Barotrauma)	101
Ear Trauma	102
Otosclerosis (Otospongiosis)	102
Fixed Malleus Syndrome	103
Relapsing Polychondritis	104
Temporal Bone Chemodectomas (Nonchromaffin Paragangliomas)	104
Temporal Bone Malignant Neoplasms	105
6. Tinnitus and Ear Pressure (Fullness)	107
Nonpulsatile Tinnitus	107
Pulsatile Tinnitus	109
Vascular Tinnitus	110
Nonvascular Pulsatile Tinnitus	113
Ear Pressure (Fullness)	115
7. Otalgia (Earache and Ear Pain)	117
Otalgia (Primary) with Otoscopic Abnormalities	117
Otalgia (Secondary) without Otoscopic Abnormalities	132
8. Otorrhea (Ear Discharge, Ear Drainage) and Ear Pruritus	134
Dermatoses of the External Auditory Canal	134
External Otitis	135
Malignant External Otitis	135
Acute Suppurative Otitis Media	135
Acute Suppurative Mastoiditis	135
Chronic Suppurative Otitis Media	135
Temporal Bone Trauma	141
Temporal Bone Neoplasms	141
Postoperative States	141
Ear Pruritus	143
9. Peripheral (Flaccid) Facial Paralysis	147
Bell's Palsy	149
Herpes Zoster Oticus	151
Malignant External Otitis	151
Acute Suppurative Otitis Media	151
Active Chronic Suppurative Otitis Media	152
Temporal Bone Trauma	152
Petrous Apex Congenital Cholesteatoma	153
Benign Temporal Bone Neoplasms	153
Temporal Bone Malignant Neoplasms	153

PART II

DISEASES AND DISORDERS OF THE NOSE,

<i>Eugene B. Kern</i>	155
10. Examination of the Nose and Sinuses	157
History	157
The Physical Examination	160
Roentgenograms	179
Rhinomanometry—Nasal Breathing Tests	181
11. Nasal Obstruction Due to Mucosal Changes	184
Physiologic Considerations	186
Infectious Diseases	187
The Allergic Nose as a Cause of Nasal Obstruction	196
The Vasomotor Nose (Vasomotor Rhinopathy, Vasomotor Rhinitis, or Nonallergic Rhinitis) as a Cause of Nasal Obstruction	209
Rhinitis Medicamentosa	215
Hypertrophied Mucosa—Hypertrophied Turbinates	218
Atrophic Mucosa, Nasal Atrophy, Atrophic Rhinitis and Ozena	219
12. Nasal Obstruction Due to Structural Changes	222
Nasal Septal Abnormalities	222
Diagnosis	223
Symptoms	223
Management	224
Nasal Trauma	225
New Growths	234
Miscellaneous Causes of Nasal Airway Obstruction	238
13. Other Local Symptoms of Nose and Sinus Disease	243
Disorders of Smell	243
Sneezing	246
Rhinorrhea	248
Postnasal Drip	250
The Dry Nose	251
Nasal Pain	254
Nasal Manifestations of Systemic Disorders	256
External Nasal Lesions	259
14. Sinusitis	263
Pathophysiology	263

Classification	264
Symptoms	265
Differential Diagnosis	267
Sinus Roentgenograms	267
Diagnosis	268
Cultures	268
Management	268
Complications	275
Patient Discussion	276
Pediatric Sinusitis	277
15. Epistaxis	282
Patient Evaluation	282
Concepts	282
16. Regional and Systemic Symptoms of Nasal and Paranasal Sinus Disease	297
Regional Symptoms	297
Systemic Symptoms of Nasal and Paranasal Sinus Disease	314

PART III

THE THROAT, <i>Bruce W. Pearson</i>	319
17. Examination of the Throat	321
The History	321
The Examination	321
Roentgenographic Examinations of the Throat	332
18. Sore Throats	334
Examination Findings and Their Importance	336
Acute Sore Throats	341
Chronic and Recurrent Sore Throats	357
Tonsillectomy and Adenoidectomy	360
19. A Lump in the Throat	367
Review of the History and Physical Examination .	367
Psychogenic Globus (Globus Hystericus)	368
Cricopharyngeal Spasm	369
Diaphragmatic Hernia and Reflux	370
Hidden Tumors	371
20. Difficulty in Swallowing	374
How a Normal Swallow is Accomplished	374
The Significance of Swallowing Symptoms	375
Congenital Causes of Difficult Feeding	376
Neuromuscular Causes of Difficult Swallowing.	379

Corrosive Ingestion and Stricture of the Pharynx and Esophagus	381
Foreign Bodies	383
Pharyngeal Diverticula	384
Neoplasms	384
Gastroesophageal Reflux	388
Roentgenographic, Manometric, and Endoscopic Examinations of the Pharynx and Esophagus ...	388
21. Hoarseness and Disorders of the Voice	392
Abnormalities of Voice and Speech	393
Examination in Voice and Speech Disorders	393
Hoarseness with Visible Abnormality of the Larynx	394
Dysphonia Without Mirror Laryngoscopic Abnormalities	403
Dysphonia and Dysarthria in Infants and Children	406
Aids to Examining the Larynx: Diagnostic Laryngoscopy	408
22. Airway Obstruction	410
Emergency Intubation	410
Emergency Cricothyroidotomy	412
Emergency Tracheotomy	413
Causes of Airway Obstruction	415
Elective Tracheotomy	425
23. Nasopharyngeal Lesions	428
Differential Diagnosis of Nasopharyngeal Masses	428
24. A Lump in the Neck	431
Clinical Classification	431
Biopsy	432
Anterior Midline Swellings in the Neck	432
Solitary Lateral Masses in the Neck	434
Multiple Lumps in the Lateral Neck	441
25. Upper Respiratory Tract Causes of Cough and Hemoptysis	443
Investigation of Coughing.	443
Hemoptysis: Sources of Bleeding in the Upper Respiratory Tract	446
26. Foreign Bodies in the Throat	448
Management When No Foreign Body Is Found ...	449

Removal of Foreign Bodies from the Pharynx, Larynx, Bronchial Tree, and Esophagus	450
27. Oral Diagnosis and Treatment	451
The Lips	451
Abnormal Appearances of the Tongue	452
The Burning Tongue Syndrome	452
Xerostomia	453
Disorders of Taste	453
Drooling	454
Stomatitis	454
Blisters	454
Oral Pigmentation	455
Disorders of the Gums	455
The Teeth	456
Leukoplakia and Oral Cancer	457
28. Salivary Gland Disorders	459
Signs and Symptoms of Salivary Gland Disease	459
Examination of the Salivary Glands	460
Oral Manifestations of Salivary Disease	462
Swellings of the Submandibular Region	463
Diffuse Unilateral Parotid Swelling	465
Diffuse Bilateral Parotid Swelling	467
Localized Swellings in the Parotid Region	469
29. Injuries to the Head and Neck	472
Facial Injuries	473
Blunt Trauma to the Neck	474
Penetrating Trauma to the Neck	475
Summary	475
Index	477

Diseases of the Ears, Nose, and Throat

A Guide to Diagnosis and Management

D. THANE R. CODY, M.D., C.M., Ph.D.

Professor of Otolaryngology
Mayo Medical School;
Chairman, Department of Otolaryngology
Mayo Clinic
Rochester, Minnesota

EUGENE B. KERN, M.D., M.S.

Associate Professor of Otolaryngology
Mayo Medical School;
Consultant, Department of Otolaryngology
Mayo Clinic
Rochester, Minnesota

BRUCE W. PEARSON, M.D., F.R.C.S.(C.)

Assistant Professor of Otolaryngology and Anatomy
Mayo Medical School;
Consultant, Department of Otolaryngology
Mayo Clinic
Rochester, Minnesota



YEAR BOOK MEDICAL PUBLISHERS, INC.
CHICAGO • LONDON

Examination of the Ear

THE EAR is a complex organ whose important functional components, the hearing apparatus and balance mechanism, are located in the temporal bone of the skull. A considerable portion of the ear is not accessible to direct examination and can only be evaluated by special tests. The ear can be divided into three parts: the external ear, the middle ear, and the internal ear (Fig 1-1). The external ear comprises the auricle and the external auditory canal. The middle ear includes the tympanic membrane, ossicular chain (malleus, incus, and stapes), and the middle ear space. In addition, the middle ear communicates with the attic (epitympanum), mastoid process, and Eustachian tube, and the area that is occupied by all of these structures is referred to as the middle ear cleft. The internal ear comprises the cochlea, vestibular labyrinth with the horizontal, superior, and posterior semicircular canals, the utricle and the saccule, and the acoustic nerve (eighth cranial nerve) with the auditory or cochlear nerve and the vestibular nerve with its superior and inferior divisions.

The complexity of otologic diseases and disorders is magnified by the ear's intimate relationship to the brain occupying the middle and posterior cranial fossa, the internal carotid artery, the sigmoid sinus, the jugular bulb, and cranial nerves V, VI, VII, IX, X, XI, and XII. The ear cannot be analyzed independent of these important structures or of the nose and pharynx.

The History

Just as in any other area of medicine, in evaluating a patient with an ear complaint, an accurate and detailed history is mandatory. The symptoms that patients ascribe to an ear disorder are dizziness, hearing loss, earache (ear pain, otalgia), drainage from the ear (otorrhea), noises in the ear (tinnitus), a plugged sensation or a sensation of pressure or fullness in the ear, and itching (pruritus) in the ear. In addition, peripheral facial nerve paralysis usually is caused by a disorder

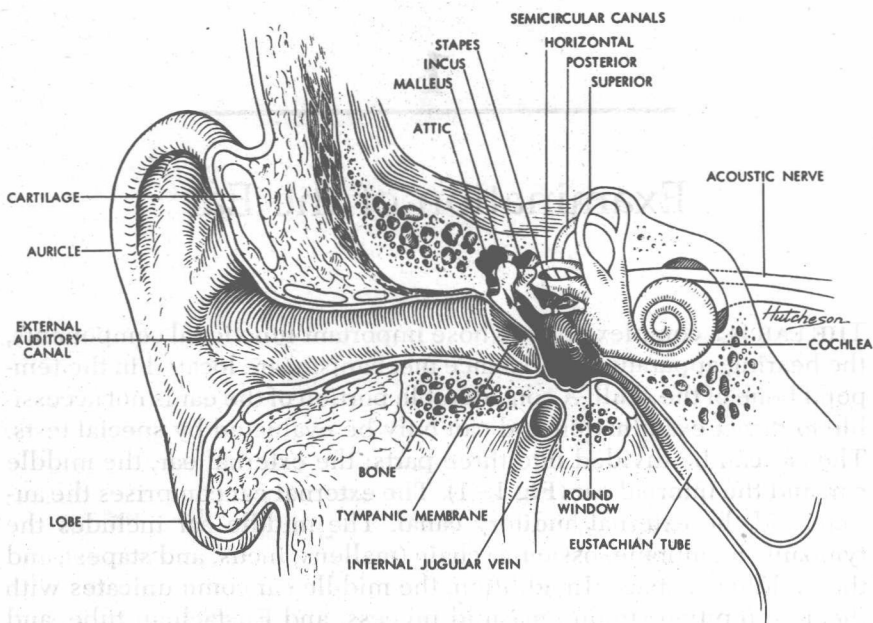


Fig 1-1.—Anatomy of ear.

in the temporal bone. Important features in history taking in the differential diagnosis of these symptoms will be covered in subsequent chapters.

The Examination

The extent of the examination of the patient with an aural symptom or symptoms will vary tremendously according to the specific complaint. For example, if the patient complains of itching in the ears, an otoscopic examination may be all that is necessary. On the other hand, if the patient complains of dizziness and hearing loss, a complete ear, nose, and throat examination, evaluation of the function of the cranial nerves and cerebellum, and a number of special tests are required.

INSPECTION AND PALPATION OF THE EAR

The auricle, usually only the orifice of the external auditory canal, and the mastoid process are accessible to gross inspection and palpation. It is important to remember that, with the exception of the lobe, the auricle is composed of cartilage. This fact will allow the physician


to differentiate between cellulitis of the auricle (p. 121) and auricular chondritis due to relapsing polychondritis (p. 118), both of which cause auricular swelling, redness, tenderness, and pain. With cellulitis the entire auricle will be involved, whereas with relapsing polychondritis the lobe will be unaffected. The correct diagnosis is extremely important, since the treatments of these conditions are entirely different.

At times, simple manipulations of the auricle can be of aid in the differential diagnosis. If gently pulling on the auricle or pressing the tragus inward causes pain in a patient complaining of earache, he probably has an external otitis. Ordinarily, these movements of the auricle do not cause discomfort if the patient has an otitis media.

If a patient with earache and otorrhea has tenderness over the mastoid process, a mastoiditis is usually indicated. Redness and swelling in addition to the tenderness make the diagnosis a certainty.

Routine inspection of the external auditory canal and tympanic membrane can be accomplished either with an otoscope or with a head mirror and ear speculum. The head mirror provides better illumination and greater flexibility than the otoscope in performing manipulations in the ear, and it is well worth the primary care physician's time to become adept in its use. Of course, the head mirror is also necessary for indirect examination of the pharynx and larynx. Inspection of the ear is facilitated by gently pulling upward and backward on the auricle to straighten the ear canal. During inspection of the external

Fig 1-2. — Pneumatic otoscope.



auditory canal, one should be looking for dryness and scaling, foreign bodies, inflammation, ulcers, lacerations, and tumors. The tympanic membrane should be examined for translucency, a light reflex, scarring, discoloration, a fluid level, bulging, retraction, and perforation.

The pneumatic otoscope (Fig 1-2) is an extremely useful tool. It provides a little magnification (1.5 times) and the capability of applying positive and negative pressure to the tympanic membrane to assess the mobility of the tympanic membrane and the malleus and to perform the fistula test. The physician should routinely use the pneumatic otoscope until he is familiar with the normal mobility of the tympanic membrane and the malleus.

To facilitate inspection and certain manipulations in the ear, an operating microscope can be used. It is helpful in determining whether there is an ossicular chain defect or a tumor in the middle ear. Most large hospitals will have one, and the primary care physician can arrange to examine his patient with it if that procedure seems indicated.

Fig 1-3.—Ear curettes (*top left*), cotton-tipped applicators (*top center*), ear (Lillie) hook (*top right*), alligator forceps (*bottom left*), and no. 5 French suction tip (*bottom right*).

