

MEDICAL EMBRYOLOGY

JAN LANGMAN, M.D., Ph.D.

Third Edition/Third Asian Edition

MEDICAL EMBRYOLOGY

Human Development—Normal and Abnormal

JAN LANGMAN, M.D., Ph.D.

Professor of Anatomy, University of Virginia, Charlottesville
(Formerly Professor of Anatomy, McGill University, Montreal)

Illustrations by JILL LELAND

THIRD EDITION/THIRD ASIAN EDITION



The Williams & Wilkins Company
BALTIMORE/1975



Igaku Shoin Ltd.
TOKYO/1975

Copyright © 1975

The Williams & Wilkins Company
428 E. Preston Street
Baltimore, Md. 21202, U.S.A.

First Asian Edition Published 1966

Second Asian Edition Published 1969

Third Asian Edition Published 1975

Reprinted 1976

Reprinted 1977

by

Igaku Shoin Ltd.
5-29-11 Hongo Bunkyo-ku
Tokyo, Japan

Sales Area of Asian Edition

Japan, Taiwan, Okinawa, Vietnam, Cambodia, Laos, Thailand, Singapore,
Malaysia, Indonesia, Afghanistan, Hong Kong, Burma, Korea, Sri Lanka,
and The Philippines.

Published by special arrangement with the original publishers, The Williams &
Wilkins Company, Baltimore, Md. 21202, U.S.A.

Composed and Printed at the

Waverly Press, Inc.
Mt. Royal & Guilford Avenues
Baltimore, Md. 21202, U.S.A.

MEDICAL EMBRYOLOGY

THIRD EDITION

To my wife
INA
in appreciation of her great support during
the writing of this book

Preface to the Third Edition

The worldwide acceptance of the first and, particularly, of the second edition of *Medical Embryology*, as shown by the many foreign translations that have appeared since the original printing in English, indicates that the book fills a need among students preparing themselves for a medical career. Although in both foregoing editions each chapter was complemented with a brief description of the most important birth defects, in this edition I have given still more attention to the clinical applications, and in some cases patients with congenital abnormalities are demonstrated by photographs. While ten years ago medical students would only occasionally see patients with birth defects, as a result of the enormous progress in genetics, pediatrics, and surgery they are now seen almost daily.

New illustrations have been added throughout the book and colors have been applied to many drawings in the hope that the student more easily can learn the essentials of development. Photographs of embryos and fetuses have also been added, since as a result of the liberalized abortion laws medical students will probably see the early products of human development.

As in the previous editions the excellent drawings were made by Miss Jill Leland. For some of the new drawings and particularly for the color work, I wish to express my thanks to Mr. Mike Schenk.

To the many colleagues and students who wrote to me from all over the world, I also wish to express my sincere thanks. Many of their good suggestions for improvement of the text and illustrations have been incorporated in this new edition.

August 1974

Preface to the First Edition

Recent advances in embryology, radioautography, and electron microscopy have been so overwhelming that the medical student often has difficulty in grasping the basic facts of development from the highly complicated picture presented to him. The aim of this book, therefore, is to give the future doctor a concise, well illustrated presentation of the essential facts of human development, clarifying the gross anatomical features without omitting the recent advances or changing concepts in the basic sciences. Furthermore, since embryology has become of great practical value because of the enormous progress made in surgery and teratology, each chapter on the development of the organ systems has been complemented by a description of those malformations important to the student in his further training. As a further reflection of the increased clinical importance of embryology an entire chapter has been devoted to the etiology of congenital defects.

Of the many colleagues who have been of help in the writing of this book, I particularly wish to thank Dr. C. P. Leblond for his continuous interest and encouragement; Dr. F. Clarke Fraser, for his help in discussing the various aspects of the congenital malformations; and my friends, Dr. Harry Maisel, Dr. Robert van Mierop, and Dr. Yves Clermont, who have spared no effort in assisting with the design of the drawings and the checking of the text.

I wish to express my sincere thanks to Miss Jill Leland, who prepared all the illustrations in this book, and to Mrs. E. Dawson, who has been of such excellent support to me in setting up the manuscript.

Contents

| | |
|---|-----|
| Preface to the Third Edition | vii |
| Preface to the First Edition | ix |

PART 1
GENERAL EMBRYOLOGY

| | |
|---|-----|
| 1. Gametogenesis | 1 |
| 2. Ovulation To Implantation | 19 |
| <i>First week of development</i> | |
| 3. Formation Of The Bilaminar Germ Disc | 38 |
| <i>Second week of development</i> | |
| 4. Formation Of The Trilaminar Germ Disc | 50 |
| <i>Third week of development</i> | |
| 5. Derivatives Of The Germ Layers And Establish- ment Of Body Form | 60 |
| <i>Fourth to eighth weeks of development</i> | |
| 6. Development Of The Fetus | 81 |
| <i>Third to tenth months of development</i> | |
| 7. Development Of The Fetal Membranes And Pla- centa | 89 |
| 8. Congenital Malformations And Their Causes | 108 |

PART 2
SPECIAL EMBRYOLOGY

| | |
|--|-----|
| 9. Skeletal System And Ossification | 137 |
|--|-----|

| | |
|---|-----|
| 10. Muscular System | 154 |
| 11. Urogenital System | 160 |
| <i>Urinary system; genital system</i> | |
| 12. Cardiovascular System | 201 |
| <i>Normal development of the heart; abnormal development of the heart; arterial system; venous system; circulatory changes at birth</i> | |
| 13. Digestive Tube And Its Derivatives | 258 |
| <i>Pharyngeal gut; caudal part of the foregut; midgut; hindgut</i> | |
| 14. Coelomic Cavity And Mesenteries | 303 |
| 15. Central Nervous System | 318 |
| <i>Spinal cord; brain; autonomic nervous system</i> | |
| 16. Eye | 368 |
| 17. Ear | 378 |
| 18. Face, Nose, And Palate | 389 |
| 19. Integumentary System | 401 |
| Index | 409 |

PART 1

GENERAL EMBRYOLOGY

CHAPTER 1

Gametogenesis

CHROMOSOMAL CHANGES DURING GERM CELL MATURATION

- FIRST MEIOTIC DIVISION: *pairing; chiasma formation*
- SECOND MEIOTIC DIVISION
- ABNORMAL MEIOTIC DIVISIONS: *trisomy; monosomy; nondisjunction*

MORPHOLOGICAL CHANGES DURING GERM CELL MATURATION

- APPEARANCE AND MIGRATION OF PRIMORDIAL GERM CELLS
 - OOGENESIS: *oogonium; primary oocyte; secondary oocyte and polar body; primordial follicle; mature follicle; mature oocyte*
 - SPERMATOGENESIS: *spermatogonium; primary spermatocyte; secondary spermatocyte; spermatid*
 - SPERMIOGENESIS: *acrosomic head cap; middle piece, body and tail*
 - ABNORMAL GAMETES: *multinucleated oocytes; abnormal spermatozoa*
-

The development of a human being begins with fertilization, a process by which two highly specialized cells, the *spermatozoon* from the male and the *oocyte* from the female, unite to give rise to a new organism, the *zygote*. In preparation for possible fertilization, both male and female germ cells undergo a number of changes involving the chromosomes as well as the cytoplasm. The purpose of these changes is twofold:

1. To reduce the number of chromosomes to half that in the normal somatic cell, *i.e.*, from 46 to 23. This is accomplished by two specialized divisions, known as *meiotic* or *maturation* divisions. The reduction in the number of chromosomes is necessary, since otherwise fusion of a male and a female germ cell would result in an individual with twice the number of chromosomes of the parent cells.

2. To alter the shape of the germ cells in preparation for fertiliza-

tion. The male germ cell, initially large and round, loses practically all of its cytoplasm and develops a head, neck and tail. The female germ cell, on the contrary, gradually becomes larger as the result of an increase in the amount of cytoplasm. At maturity the oocyte has a diameter of about 120 μ .

Although the reduction in the number of chromosomes as well as the cytoplasmic changes are integral parts of the germ cell maturation, each process is discussed separately in the following paragraphs.

Chromosomal Changes during Germ Cell Maturation

It is now firmly established that the human somatic cell contains 46 chromosomes. Forty-four of these are *autosomes* and two are *sex chromosomes*. In the female the latter are represented by two X-chromosomes; in the male by one X- and a much shorter Y-chromosome. Each autosome has among the other chromosomes a partner with the same morphological characteristics. Together they form the members of a *homologous pair*. Although the X- and Y-chromosomes in the male are not morphologically identical, the human somatic cell is said to contain 23 pairs, or a *diploid* (diploos—double) number of chromosomes. *One chromosome of each pair is originally derived from the mother and the other from the father* (fig. 1-1).

First Meiotic Division

In the course of development, the primitive germ cells undergo two special divisions, the *maturation* or *meiotic divisions*, by which the number of chromosomes is reduced to half the normal number. The mature germ cells contain 23 chromosomes, that is, the *haploid* (haploos—single) number.

Just before the first meiotic division begins, the female as well as the male primitive germ cells (primary oocyte and primary spermatocyte) replicate their DNA.¹ Hence, at the beginning of the division, the cells contain double the normal amount of DNA (4n) and each of the 46 chromosomes is a double structure (fig. 1-1).

The prophase of the first meiotic division is extremely long and in the female may last 40 years. The first characteristic of the meiosis is the pairing of the homologous chromosomes (fig. 1-1A). The pairing is exact and point for point, except for the X-Y combination.² The centromere regions of the homologous chromosomes do not pair. Since each individual chromosome is double-structured and contains two chromatids, the homologous pair consists of four chromatids (fig. 1-1B).

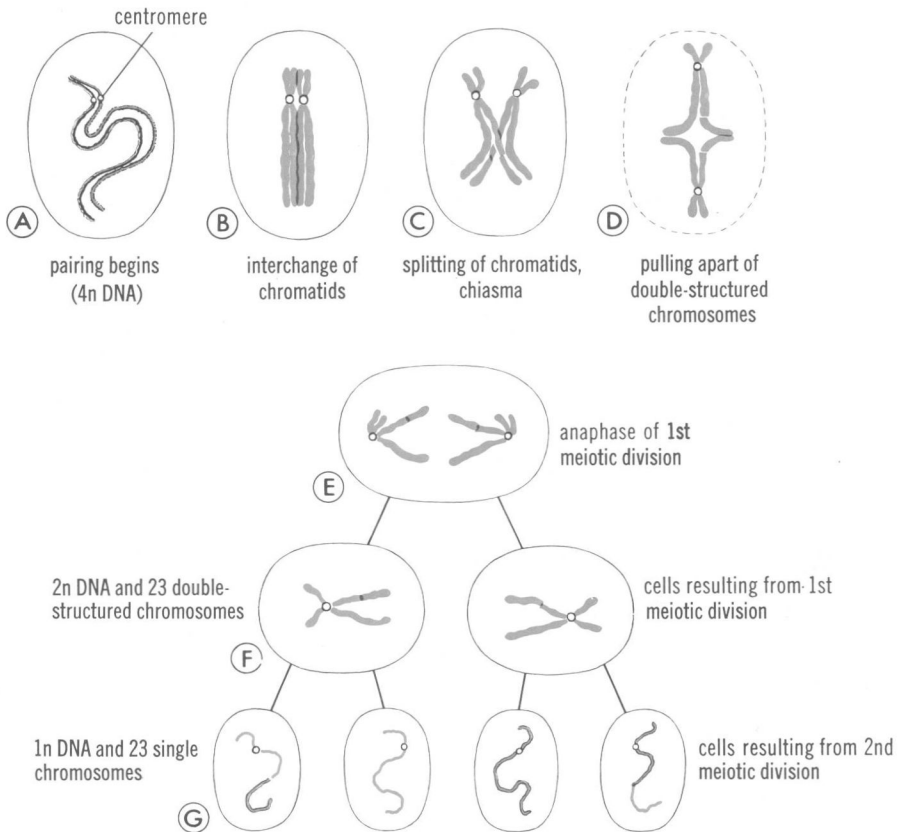


Figure 1-1. Schematic representation showing the fate of two homologous chromosomes during the first and second meiotic divisions. A, The homologous chromosomes approach each other and begin to pair. B, The homologous chromosomes are intimately paired and each member of the pair consists of two chromatids. At this stage interchange of chromatids begins. C, The intimately paired homologous chromosomes begin to separate. Note the chiasma. D, The double-structured chromosomes pull farther apart. E, Anaphase of the first meiotic division, in which each of the double-structured chromosomes moves to an opposite pole of the cell. F and G, During the second meiotic division the double-structured chromosomes split at the centromere. At completion of the division the chromosomes in each of the four daughter cells are different from each other.

The second characteristic of the first meiotic division is the *interchange of chromatid segments* between the two paired homologous chromosomes (fig. 1-1B, C). When subsequently each (double-structured) member of the homologous pair splits longitudinally, one or more transverse breaks occur in the chromatids and an interchange of

chromatid segments between two homologous chromosomes occurs (fig. 1-1C). During the separation of the homologous chromosomes, the points of interchange temporarily remain united and the chromosomal structure has then an X appearance, known as a *chiasma* (fig. 1-1C).^{3, 4} The chiasma is the morphological expression of a genetic phenomenon, known as *crossing over*, during which blocks of genes are exchanged between homologous chromosomes. In the meantime the separation continues into *diakinesis*, a stage at which the coiled, and partially separated, chromosomes are clearly distinguishable (fig. 1-1D). In the metaphase the two members of each pair are oriented on the spindle, and in subsequent stages the members migrate to the opposite poles of the cell (fig. 1-1E).

After the first meiotic division has been completed, each daughter cell contains one member of each chromosome pair and thus has 23 double-structured chromosomes (fig. 1-1F). Since each chromosome is still double-structured except at the centromere, the amount of DNA in each daughter cell equals that of a normal somatic cell ($2n$).

Second Meiotic Division

Immediately after the first meiotic division, the cell begins its second maturation division. *No DNA synthesis occurs in advance of this division.* The 23 double-structured chromosomes divide at the centromere and each of the newly formed daughter cells receives 23 single chromosomes (fig. 1-1G). The amount of DNA in the newly formed cells is now half that of the normal somatic cell. Hence, the purpose of the two meiotic or maturation divisions is twofold: (1) to enable the members of the homologous chromosome pair to exchange blocks of genetic material (first meiotic division); and (2) to provide each germ cell with both a haploid number of chromosomes and half the amount of DNA of a normal somatic cell (second meiotic division).

As a result of the meiotic divisions, the primary oocyte gives rise to four daughter cells, each with 22 plus 1 X-chromosomes (fig 1-2A). Only one of these develops into a mature oocyte; the other three, the *polar bodies*, receive hardly any cytoplasm and degenerate during subsequent development.

The primary spermatocyte gives rise to two daughter cells with 22 plus 1 X-chromosomes and two with 22 plus 1 Y-chromosomes (fig. 1-2B).

Abnormal Meiotic Divisions

The complicated events occurring during the meiotic divisions apparently are not without hazards. No sooner was the normal chromosome pattern in man established (fig. 1-3), when it became

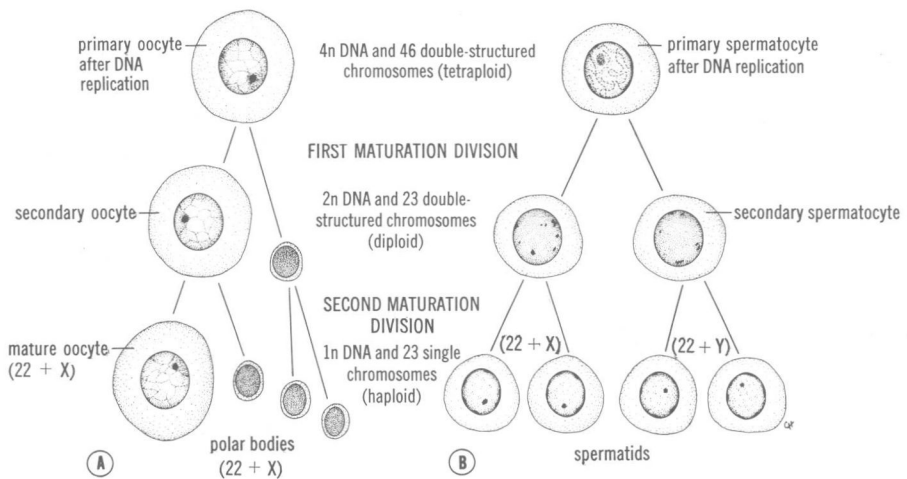


Figure 1-2. Schematic drawing showing the events occurring during the first and second maturation divisions. A, The primitive female germ cell (primary oocyte) produces only one mature cell, the mature oocyte. B, The primitive male germ cell (primary spermatocyte) produces four spermatids, all of which develop into spermatozoa.

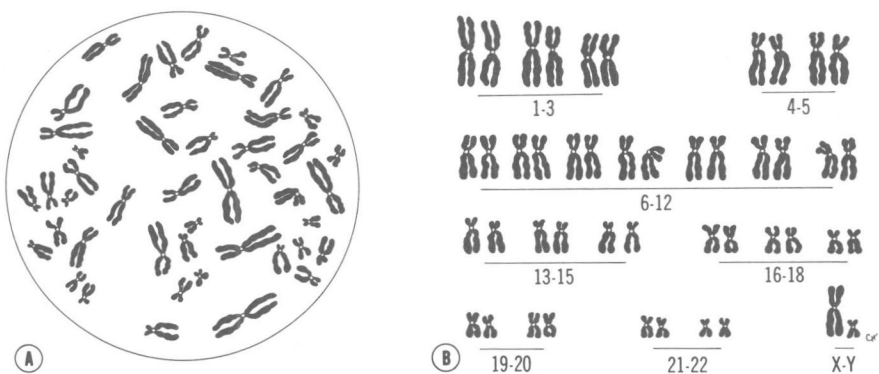


Figure 1-3. A, Karyotype of a normal human cell. Chromosomal spreads are obtained by culturing cells in an artificial medium and subsequently exposing them to a colchicine solution to arrest the mitoses in the metaphase. After a brief treatment with a hypotonic salt solution, the cells are fixed, spread on a slide, stained, and photographed. B, Diagrammatic representation (idiogram) of the chromosomes seen in A. The chromosomes are arranged in groups according to their total length, the position of the centromere, and the length of the arms on each side of the centromere.

evident that some people possessed an abnormal number of chromosomes. These abnormalities involved either the autosomes (the absence of a chromosome or the presence of an extra one), or the sex chromosomes (usually the presence of an extra one). The presence of an extra chromosome makes the individual trisomic for the particular chromosome, and this condition is known as *trisomy*. If one of the partners of a chromosome pair is absent, the condition is known as *monosomy*.

Chromosomal abnormalities originate during the meiotic divisions. Normally the two members of a homologous chromosome pair separate during the first meiotic division so that each daughter cell receives one component of each pair (fig. 1-4A). Sometimes, however, separation does not occur (*nondisjunction*), and both members of a pair then move into one cell (fig 1-4B). As a result of the nondisjunction of the chromosomes, one cell receives 24 chromosomes and the other 22, instead of the normal 23 chromosomes. When, at fertilization, a gamete having 23 chromosomes fuses with a gamete having 24 or 22 chromosomes, the result will be an individual with either 47 chromosomes (trisomy), or 45 chromosomes (monosomy). Nondisjunction is thought to occur during the first or second meiotic division of the female germ cells rather than during the divisions of the male germ cells (fig. 1-4C).

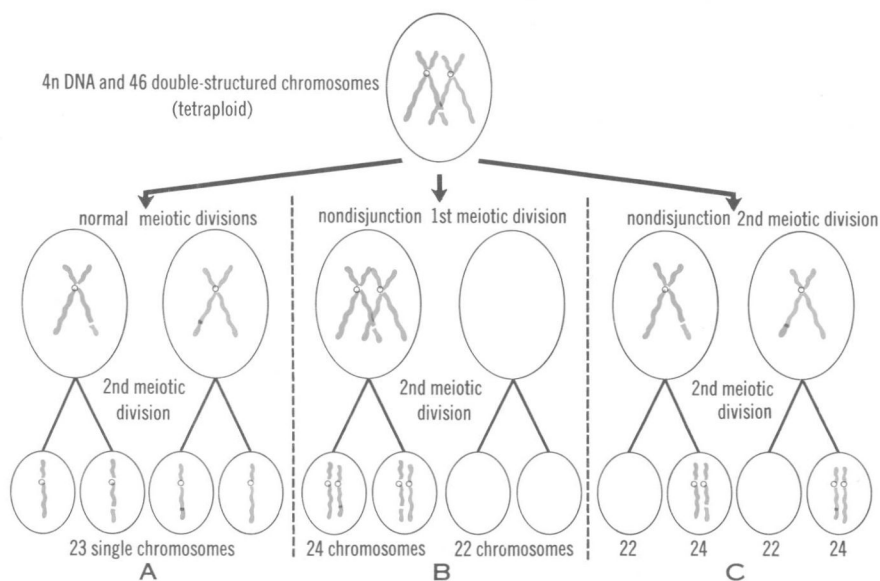


Figure 1-4. Schematic drawing showing: A, Normal maturation divisions. B, Nondisjunction in first meiotic division. C, Nondisjunction in second meiotic division.