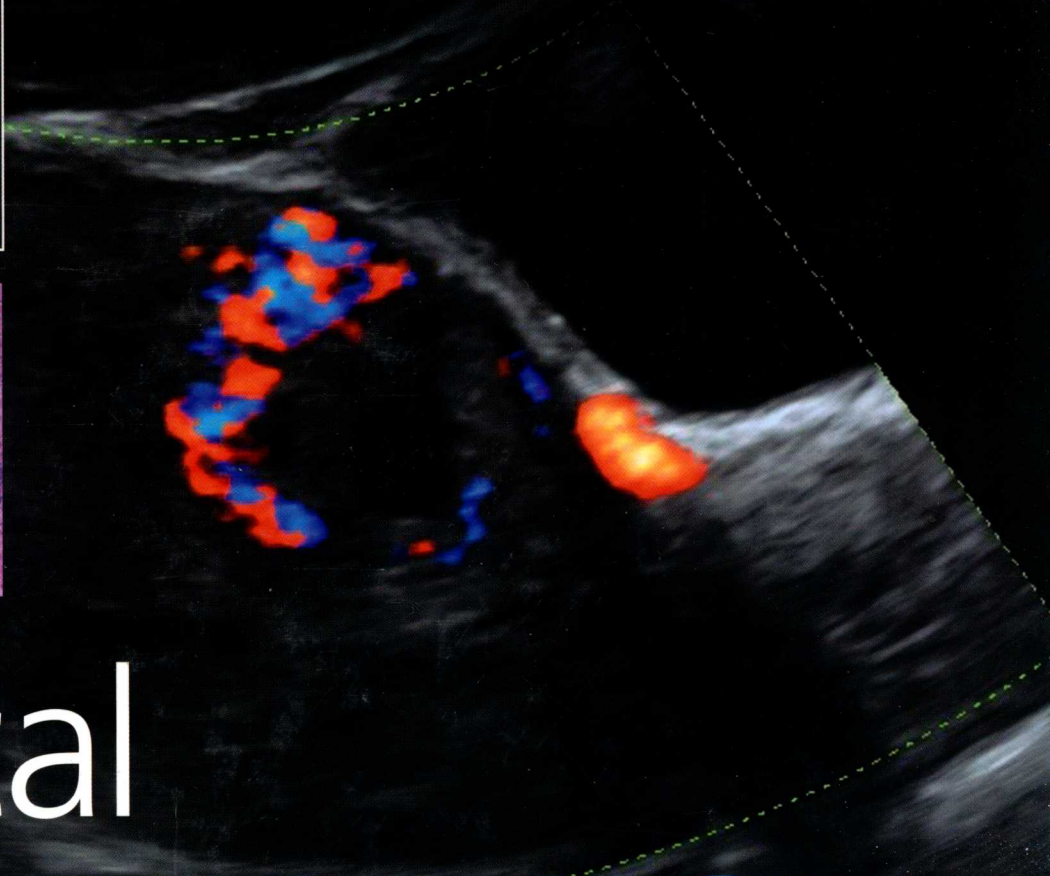
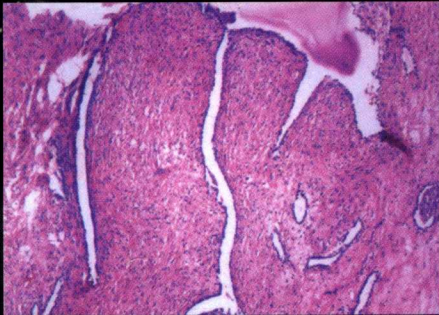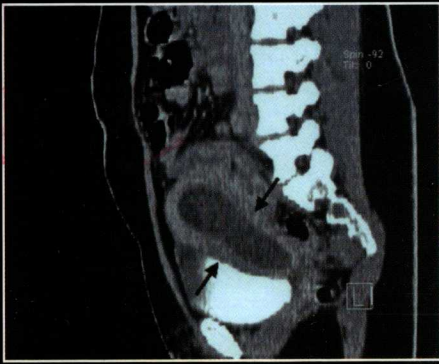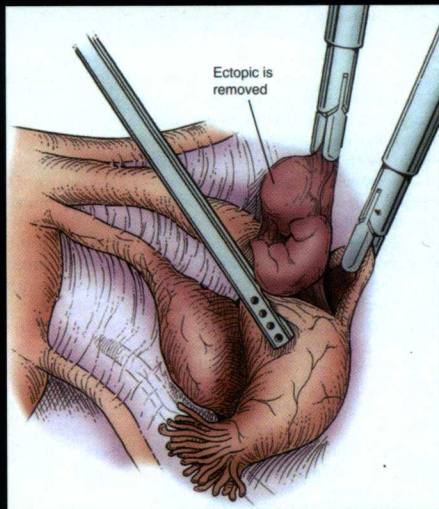


SECOND EDITION



Clinical GYNECOLOGY



Edited by:

Eric J. Bieber

Joseph S. Sanfilippo

Ira R. Horowitz

Mahmood I. Shafi

CAMBRIDGE

Medicine

Clinical Gynecology

Second Edition

Edited by

Eric J. Bieber MD MSHCM

Clinical Professor of Health Sciences, Rochester Institute of Technology,
Rochester Regional Health System, Rochester NY

Joseph S. Sanfilippo MD MBA

Professor of Obstetrics, Gynecology & Reproductive Sciences and Chief, Division of Reproductive Endocrinology & Infertility,
University of Pittsburgh, Pittsburgh, PA, USA

Ira R. Horowitz MD SM

John D. Thompson Professor and Chairman, Department of Gynecology and Obstetrics,
Emory University School of Medicine, Atlanta, GA, USA

Mahmood I. Shafi MD FRCOG

Consultant Gynaecological Surgeon and Oncologist, Addenbrooke's Hospital,
Cambridge University Hospitals NHS Foundation Trust, Cambridge, UK



CAMBRIDGE
UNIVERSITY PRESS



CAMBRIDGE
UNIVERSITY PRESS

University Printing House, Cambridge CB2 8BS, United Kingdom

Cambridge University Press is part of the University of Cambridge.

It furthers the University's mission by disseminating knowledge in the pursuit of education, learning and research at the highest international levels of excellence.

www.cambridge.org

Information on this title: www.cambridge.org/9781107040397

© Cambridge University Press 2015

This publication is in copyright. Subject to statutory exception and to the provisions of relevant collective licensing agreements, no reproduction of any part may take place without the written permission of Cambridge University Press.

First edition published 2006 by Churchill Livingstone Elsevier

Second edition published 2015

Printed in Spain by Grafos SA, Arte sobre papel

A catalog record for this publication is available from the British Library

Library of Congress Cataloging in Publication data

Clinical gynecology (Bieber)

Clinical gynecology / edited by Eric J. Bieber, Joseph S. Sanfilippo, Ira R. Horowitz, Mahmood I. Shafi. – Second edition.

p. ; cm.

Includes bibliographical references and index.

ISBN 978-1-107-04039-7 (Hardback)

I. Bieber, Eric J., editor of compilation. II. Sanfilippo, J. S. (Joseph S.), editor of compilation. III. Horowitz, Ira R., editor of compilation. IV. Shafi, Mahmood, editor of compilation. V. Title.

[DNLM: 1. Genital Diseases, Female. 2. Gynecologic Surgical Procedures—methods. 3. Gynecology—methods. WP 140]

RG101

618.1-dc23 2013034200

ISBN 978-1-107-04039-7 Hardback

Additional resources for this publication at www.cambridge.org/9781107040397

Cambridge University Press has no responsibility for the persistence or accuracy of URLs for external or third-party internet websites referred to in this publication, and does not guarantee that any content on such websites is, or will remain, accurate or appropriate.

.....

Every effort has been made in preparing this book to provide accurate and up-to-date information which is in accord with accepted standards and practice at the time of publication. Although case histories are drawn from actual cases, every effort has been made to disguise the identities of the individuals involved. Nevertheless, the authors, editors and publishers can make no warranties that the information contained herein is totally free from error, not least because clinical standards are constantly changing through research and regulation. The authors, editors and publishers therefore disclaim all liability for direct or consequential damages resulting from the use of material contained in this book. Readers are strongly advised to pay careful attention to information provided by the manufacturer of any drugs or equipment that they plan to use.

Contributors

Rony A. Adam MD

Division of Female Pelvic Medicine and Reconstructive Surgery, Professor, Department of Obstetrics and Gynecology, Vanderbilt University, TN, USA

Gloria Bachmann MD

Director, Women's Health Institute, Department of Obstetrics & Gynecology, UMDNJ-Robert Wood Johnson Medical School, New Brunswick, NJ, USA

Nichole M. Barker DO

Seattle Reproductive Medicine, Seattle, WA, USA

Randall B. Barnes MD

Department of Obstetrics & Gynecology, The Feinberg School of Medicine, Northwestern University, Chicago IL, USA

John Bennett MD

Department of Radiology, St. Joseph's Health Care London, London, Ontario, Canada

Inbar Ben-Shachar MD

Department of Obstetrics & Gynecology, Hadassah Mt. Scopus, Jerusalem, Israel

Jonathan S. Berek MD MMSc

Laurie Kraus Lacob Professor, Director Stanford Women's Cancer Center Stanford Cancer Institute, and Professor & Chair, Department of Obstetrics & Gynecology, Stanford University School of Medicine, Stanford, CA, USA

Sarah L. Berga MD

Professor & Chair, Department of Obstetrics & Gynecology, Wake Forest School of Medicine, Winston-Salem, NC, USA

Monica W. Best MD

Fellow, Department of Obstetrics & Gynecology, Emory University School of Medicine, Atlanta, GA, USA

Eric J. Bieber MD MSHCM

Clinical Professor of Health Sciences, Rochester Institute of Technology, Rochester Regional Health System, Rochester, NY, USA

Frank M. Biro MD

Rauh Professor, Department of Pediatrics, University of Cincinnati College of Medicine; Director, Division of Adolescent Medicine, Cincinnati Children's Hospital Medical Center, Cincinnati, OH, USA

Shan Biscette MD

Department of Obstetrics & Gynecology, University of Louisville School of Medicine, Louisville, KY, USA

Anita K. Blanchard MD FACOG

Department of Obstetrics & Gynecology, University of Chicago Medical Center, Chicago, IL, USA

Candace Brown MSN, PharmD

Department of Pharmacy Practice, University of Tennessee, Memphis, TN, USA

Ronald T. Burkman MD

Professor Tufts University School of Medicine, Division of General Obstetrics & Gynecology, Baystate Medical Center, Springfield, MA, USA

Joseph Buscema MD

Arizona Oncology, Tuscon, AZ, USA

John E. Buster MD

Professor Department of Obstetrics & Gynecology, Warren Alpert Medical School of Brown University, Providence, RI, USA

Michael Byas-Smith MD

Department of Anesthesiology, Emory University Hospital, Atlanta, GA, USA

Sandra Ann Carson MD

Professor & Director, Division of Reproductive Endocrinology & Infertility, Department of Obstetrics & Gynecology, Alpert Medical School of Brown University, Providence, RI, USA

Judy C. Chang MD MPH

Assistant Professor, Department of Obstetrics, Gynecology & Reproductive Sciences, University of Pittsburgh, Magee-Womens Hospital, Pittsburgh, PA, USA

Annie N. Y. Cheung MD FRCPATH

Professor, Department of Pathology, University of Hong Kong, Hong Kong, China

Mindy S. Christianson MD

Department of Gynecology & Obstetrics, Johns Hopkins University School of Medicine, Lutherville, MD, USA

Karishma Circelli MD

Department of Obstetrics and Gynecology, University of Kansas School of Medicine, Kansas City, KS, USA

Daniel L. Clarke-Pearson MD

Department of Obstetrics & Gynecology, University of North Carolina at Chapel Hill School of Medicine, Chapel Hill, NC, USA

Larry J. Copeland MD

Professor & Chair, Department of Obstetrics & Gynecology, Ohio State University Hospital, Columbus, OH, USA

Bryan D. Cowan MD (deceased)

Formerly Department of Obstetrics & Gynecology, University of Mississippi Medical Center, Jackson, MS, USA

Navneet Dhillon MD

Assistant Professor, Department of Hematology & Clinical Oncology, Emory University School of Medicine, Atlanta, GA, USA

Michael P. Diamond MD

Professor and Chair in Obstetrics and Gynecology, Medical College of Georgia, Augusta, GA, USA

Conception Diaz-Arrastia MD

Associate Professor & Director, Division of Gynecologic Oncology, Department of Obstetrics & Gynecology, Baylor College of Medicine, Houston, TX, USA

Nicole M. Donnellan MD

Fellow, Department of Obstetrics, Gynecology & Reproductive Sciences, University of Pittsburgh College of Medicine, Pittsburgh, PA, USA

Michael L. Eisenberg MD

Director, Male Reproductive Medicine and Surgery, Assistant Professor, Department of Urology, Stanford University School of Medicine, Palo Alto, CA, USA

Eric Eisenhauer MD

Department of Obstetrics & Gynecology, Ohio State University Comprehensive Cancer Center, Columbus, OH, USA

Sebastian Faro MD PhD FACOG

Professor & Vice Chairman, Department of Obstetrics & Gynecology, Lyndon Banes Johnson Hospital, Houston, TX, USA

J. Stuart Ferriss MD

Assistant Professor, Department of Obstetrics & Gynecology, Temple University School of Medicine, Philadelphia, PA, USA

Lisa C. Flowers MD

Associate Professor, Department of Obstetrics & Gynecology, Emory University School of Medicine, Atlanta, GA, USA

Susan J. Freeman BA MRCP FRCR

Consultant Radiologist, Department of Radiology, Cambridge University Hospitals NHS Foundation Trust, Cambridge, UK

Leda Gattoc MD

Associate Professor, Department of Obstetrics & Gynecology, Emory University School of Medicine, Atlanta, GA, USA

Claudine Marie Gayle MBBS MED

Department of Women's Health, Lewisham and Greenwich NHS Trust, London, UK

Timothy M. Geiger MD

Assistant Professor, Division of Colon & Rectal Surgery, Vanderbilt University Medical Center, Nashville, TN, USA

Jennifer S. Gell MD

Department of Obstetrics & Gynecology, Geisinger Health Systems, Danville, PA, USA

Alan N. Gordon MD

Professor, Central Georgia Gynecologic Oncology, Macon, GA, USA

Victoria L. Green MD MBA JD

Department of Obstetrics & Gynecology, Emory University School of Medicine, Atlanta, GA, USA

Jon K. Hathaway MD PhD FACOG FACS

Assistant Clinical Professor & Director of Minimally Invasive Gynecology, Department of Obstetrics & Gynecology, Indiana University School of Medicine, Indianapolis, IN, USA

Enrique Hernandez MD FACOG

Abraham Roth Professor & Chairman, Department of Obstetrics & Gynecology, Temple University School of Medicine, Philadelphia, PA, USA

S. Paige Hertweck MD

Professor & Director, Division of Pediatric & Adolescent Gynecology, Department of Obstetrics & Gynecology, University of Louisville School of Medicine, Louisville, KY, USA

Randall S. Hines MD

Mississippi Reproductive Medicine, Flowood, MS, USA

Ira R. Horowitz MD SM FACOG FACS

John D. Thompson Professor and Chairman, Department of Gynecology and Obstetrics, Emory University School of Medicine; Chief Medical Officer, Emory University Hospital, Atlanta, GA, USA

Fred M. Howard MS MD

Professor Emeritus, Department of Obstetrics & Gynecology, University of Rochester School of Medicine and Dentistry, Rochester, NY, USA

William W. Hurd MD MSc MPH

Professor and Director, Division of Reproductive Endocrinology, Duke University Medical Center, Durham, NC, USA

Fidan Israfilbayli MBBS DFFP PhD

Research Fellow, Birmingham Women's Hospital, Birmingham, UK

Denise J. Jamieson MD MPH

Branch Chief, Women's Health & Fertility Branch, Division of Reproductive Health, National Center for Chronic Disease & Health Promotion, Centers for Disease Control & Prevention; Clinical Professor of Gynecology & Obstetrics, Emory University School of Medicine, Atlanta, GA, USA

Carolyn R. Jaslow PhD

Biology Department, Rhodes College, Memphis, TN, USA

Erika B. Johnston-MacAnanny MD

Assistant Professor, Department of Obstetrics & Gynecology, Wake Forest Baptist Medical Center, Winston-Salem, NC, USA

Rohna M. Kearney MD MRCOG MRCPI

Consultant Urogynaecologist, Department of Obstetrics & Gynaecology, Addenbrooke's Hospital, Cambridge University Hospitals NHS Foundation Trust, Cambridge, UK

Namita Khanna MD

Assistant Professor, Department of Obstetrics & Gynecology, Emory University School of Medicine, Atlanta, GA, USA

Caroline C. King PhD MPH

Senior Service Fellow, Women's Health & Fertility Branch, Division of Reproductive Health, National Center for Chronic Disease & Health Promotion, Centers for Disease Control & Prevention, Atlanta, GA, USA

Jeremy A. King MD

Department of Obstetrics & Gynecology, United States Air Force, Wilford Hall Medical Center, Lackland Air Force Base, TX; Department of Obstetrics & Gynecology, Uniformed Services University of the Health Sciences, Bethesda, MD, USA

Ira J. Kodner MD

Solon & Bettie Gershman Professor & Director, Center for Colorectal & Pelvic Floor Disorders, Barnes-Jewish Hospital, St. Louis, MO, USA

Tamara Kolev

Fellow in Minimally Invasive Surgery, St. Luke's and Mount Sinai Roosevelt Hospital, New York, NY, USA

Athena P. Kourtis MD PhD MPH

Senior Service Fellow, Women's Health & Fertility Branch, Division of Reproductive Health, National Center for Chronic Disease & Health Promotion, Centers for Disease Control & Prevention; Clinical Associate Professor, Department of Pediatrics, Emory University School of Medicine, Atlanta, GA; Associate Professor, Department of Obstetrics & Gynecology, Eastern Virginia Medical School, Norfolk, VA, USA

S. Robert Kovac MD

Department of Obstetrics & Gynecology, Emory University School of Medicine, Atlanta, GA, USA

Ertug Kovanci MD

Assistant Professor, Department of Obstetrics and Gynecology, Baylor College of Medicine, Houston, TX, USA

William H. Kutteh MD PhD

Clinical Professor, Obstetric and Gynecology, Division of Reproductive Endocrinology, Vanderbilt University School of Medicine, and Director of the Center for the Study of Recurrent Pregnancy Loss, Fertility Associates of Memphis, Memphis, TN, USA

Eduardo Lara-Torre MD

Associate Professor, Department of Obstetrics & Gynecology, Virginia-Tech Carilion School of Medicine, Roanoke, VA, USA

Pallavi Latthe MD MRCOG

Consultant Gynaecologist, Birmingham Women's Hospital, Birmingham, UK

Herschel W. Lawson MD FACOG

Chief Medical Officer, American Society for Colposcopy & Cervical Pathology, Atlanta, GA, USA

Ronald L. Levine MD

Clinical Professor Emeritus, Department of Obstetrics & Gynecology, University of Louisville School of Medicine, Louisville, KY, USA

Frank W. Ling MD

Women's Health Specialists PLLC, Germantown, TN, USA

Larry I. Lipshultz MD

Professor of Urology, Lester & Sue Smith Chair in Reproductive Medicine, Chief, Division of Male Reproductive Medicine & Surgery, Baylor College of Medicine, Houston, TX, USA

Steven D. McCarus MD FACOG

Florida Hospital Celebration Health, Celebration, FL, USA

Robert McLellan MD

Cancer Care Center, Portsmouth Regional Hospital,
Portsmouth, NH, USA

Shruti Malik MD

Fellow, Department of Obstetrics & Gynecology,
University of Pittsburgh School of Medicine, Magee-Womens
Hospital, Pittsburgh, PA, USA

Suketu M. Mansuria MD

Assistant Director, Gynecologic Minimally Invasive
Surgery, Department of Obstetrics & Gynecology,
University of Pittsburgh, Magee-Womens Hospital,
Pittsburgh, PA, USA

Mohamed K. Mehaseb MSc MD PhD MRCOG

Consultant Gynaecological Surgeon & Oncologist,
Department of Gynaecological Oncology, Glasgow Royal
Infirmary, Glasgow, Scotland

Pamela J. Murray MD MHP

Professor & Chief of Adolescent Medicine, Department of
Pediatrics, West Virginia School of Medicine, Morgantown,
WV, USA

Saloney Nazeer MD

Director, International Network for Control of
Gynaecological Cancers, Geneva Foundation for Medical
Education & Research, WHO Collaborating Centre in
Education & Research in Human Reproduction,
Geneva, Switzerland

Farr R. Nezhat MD FACOG FACS

Professor Department of Obstetrics, Gynecology &
Reproductive Science, Icahn School of Medicine at
Mount Sinai; Director, Division & Fellowship in Minimally
Invasive Surgery & Robotics, Mount Sinai St. Luke's
and Mount Sinai Roosevelt, Mount Sinai Health System;
Adjunct Professor, Department of Obstetrics, Gynecology
and Reproductive Medicine, State University of New York
at Stony Brook, College of Medicine; Director, Minimally
Invasive Gynecologic Surgery, Department of Obstetrics
and Gynecology, Winthrop University Hospital, New York,
NY, USA

Hextan Y. S. Ngan MD FRCOG

Tsao Yin Kai Professor & Head, Department of Obstetrics &
Gynaecology, University of Hong Kong, Hong Kong, China

Gina M. Northington MD PhD

Assistant Professor & Director, Division of Female Pelvic
Medicine & Reconstructive Surgery, Department of
Obstetrics & Gynecology, Emory University School of
Medicine, Atlanta, GA, USA

Peggy A. Norton MD

University of Utah School of Medicine, Salt Lake City,
UT, USA

Ruth M. O'Regan MD

Department of Hematology & Clinical Oncology, Emory
University School of Medicine, Atlanta, GA, USA

Kristiina Parviainen MD

Department of Obstetrics & Gynecology,
University of Pittsburgh School of Medicine, Magee-Womens
Hospital, Pittsburgh, PA, USA

Resad P. Pasic MD PhD

Department of Obstetrics & Gynecology, University
of Louisville School of Medicine, Louisville, KY, USA

Tanja Pejovic MD PhD

Associate Professor, Division of Gynecologic Oncology,
Department of Obstetrics & Gynecology, Oregon Health
Sciences University, Portland, OR, USA

K. Ulrich Petry MD

Professor, Department of Gynecology & Obstetrics,
Klinikum Wolfsburg, Wolfsburg, Germany

Nancy A. Phillips MD

Clinical Assistant Professor, Department of Obstetrics &
Gynecology, UMDNJ-Robert Wood Johnson Medical School,
New Brunswick, NJ, USA

Ashish Pradhan MRCOG

Subspecialist Trainee in Urogynaecology, Department of
Obstetrics & Gynaecology, Addenbrooke's Hospital,
Cambridge University Hospitals NHS Foundation Trust,
Cambridge, UK

Elizabeth E. Puscheck MD

Professor and Frank P. Iacobell Endowed Chair,
Department of Obstetrics & Gynecology, Wayne State
University School of Medicine, Detroit, MI, USA

Suneetha Rachaneni MRCOG

Clinical Research Fellow, Birmingham Women's Hospital,
Birmingham, UK

Devon M. Ramaeker MD

Fellow, Department of Obstetrics & Gynecology, University of
Pittsburgh School of Medicine, Magee-Womens Hospital,
Pittsburgh, PA, USA

David B. Redwine MD

Formerly of St. Charles Medical Center, Bend, OR, USA

Robert L. Reid MD FRCSC

Professor, Department of Obstetrics & Gynecology,
Chair, Division REI, Kingston General Hospital and Queen's
University, Kingston, Ontario, Canada

Carla P. Roberts MD PhD

Assistant Professor, Department of Obstetrics & Gynecology,
Emory University School of Medicine, Atlanta, GA, USA

Walter Romano MD

Department of Radiology, St. Joseph's Health Care London,
London, Ontario, Canada

Peter G. Rose MD

Division of Gynecologic Oncology, The Cleveland Clinic
Foundation, Cleveland, OH, USA

Robert L. Rosenfield MD

Professor, Department of Pediatrics, University of Chicago
Pritzker School of Medicine, Chicago, IL, USA

Shon P. Rowan MD

Assistant Professor, Department of Obstetrics & Gynecology,
West Virginia University School of Medicine, Morgantown,
WV, USA

Mack T. Ruffin IV MD MPH

Professor, Department of Family Medicine,
University of Michigan, Ann Arbor, MI, USA

Janice M. Rymer MD FRCOG FRANZCOG FHEA

Professor of Gynaecology, King's College School of Medicine,
Guy's Hospital, London, UK

Evis Sala MD PhD FRCR

University Lecturer/Honorary Radiologist,
Department of Radiology, University of Cambridge,
Cambridge, UK

Ritu Salani MD MBA

Assistant Professor, Department of Obstetrics & Gynecology,
Ohio State University Comprehensive Cancer Center,
Columbus, OH, USA

Joseph S. Sanfilippo MD MBA

Professor & Chief, Division of Reproductive Endocrinology &
Infertility, Department of Obstetrics & Gynecology,
University of Pittsburgh, Magee-Womens Hospital,
Pittsburgh, PA, USA

Mahmood I. Shafi, MD, DA, FRCOG

Consultant Gynaecological Surgeon and Oncologist,
Addenbrooke's Hospital, Cambridge University Hospitals
NHS Foundation Trust, Cambridge, UK

Roger P. Smith MD

Professor and Director, Division of General Obstetrics and
Gynecology, Indiana University School of Medicine,
Indianapolis, IA, USA

Meredith L. Snook

Fellow, Department of Obstetrics & Gynecology, University of
Pittsburgh School of Medicine, Magee-Womens Hospital,
Pittsburgh, PA, USA

Thomas E. Snyder MD

Professor, Department of Obstetrics & Gynecology,
University of Kansas School of Medicine, Kansas City, KS, USA

Mary D. Stephenson MD MSc

Professor & Head, Department of Obstetrics & Gynecology,
University of Illinois College of Medicine, Chicago, IL, USA

Thomas G. Stovall MD MBA

Department of Obstetrics & Gynecology, University of
Tennessee, Memphis, TN, USA

Richard L. Sweet MD

Department of Obstetrics & Gynecology, University of
California Davis, Sacramento, CA, USA

Philip M. Toozs-Hobson MD FRCOG

Consultant Urogynaecologist, Birmingham Women's
Hospital, Birmingham, UK

Togas Tulandi MD MHCM, FRCSC FACOG

Professor and Academic Vice Chairman of Obstetrics
and Gynecology, Milton Leong Chair in Reproductive
Medicine, McGill University, Montreal, Quebec, Canada

Elizabeth R. Unger MD PhD

Chief, Chronic Viral Disease Branch, Centers for Disease
Control & Prevention, Atlanta, GA, USA

Denise S. Uyar, MD

Department of Obstetrics & Gynecology, Medical College of
Wisconsin, Milwaukee, WI, USA

Marion S. Verp MD

Department of Obstetrics & Gynecology, University of
Chicago, Chicago, IL, USA

Rahi Victory MD

Department of Obstetrics & Gynecology, Schulich School of
Medicine, University of Western Ontario, Windsor, Ontario,
Canada

Tamara J. Vokes MD

Professor & Director, Osteoporosis & Metabolic Bone Disease
Clinic, University of Chicago Medical Center, Chicago, IL, USA

Michelle J. Washington MSN PharmD

University of Tennessee College of Pharmacy, Memphis,
TN, USA

Katharine O'Connell White MD MPH

Chief, Division of General Obstetrics & Gynecology,
Department of Obstetrics & Gynecology, Baystate Medical
Center, Springfield, MA, USA

Paul E. Wise MD

Associate Professor of Surgery, Section of Colon and Rectal
Surgery, Washington University School of Medicine, St. Louis,
MO, USA

Frank M. Wittmaack MD

Aurora Health Center, Milwaukee, WI, USA

Miya P. Yamamoto MD

Clinical Instructor and Scibetta Fellow in Advanced Laparoscopic Surgery, Department of Obstetrics and Gynecology, University of Rochester School of Medicine and Dentistry, Rochester, NY, USA

Christine Yu MD

Assistant Professor, Department of Pediatrics, University of Chicago Pritzker School of Medicine, Chicago, IL, USA

Howard A. Zacur MD PhD

Department of Gynecology & Obstetrics, Johns Hopkins University School of Medicine, Lutherville, MD, USA

Since our prior edition in 2006, much has progressed in gynecology. Most notably as this book was going to press, the FDA in the US issued a black box warning on 11/28/2014 regarding the use of laparoscopic power morcellators. Please see the following statement released by the FDA, and we recommend that the reader stay abreast of this evolving situation.

UPDATED Laparoscopic Uterine Power Morcellation in Hysterectomy and Myomectomy: FDA Safety Communication

The following information updated our April 17, 2014 communication.

Date Issued: Nov. 24, 2014

Audience:

- Health Care Providers
- Medical Professional Associations
- Cancer Advocacy Organizations
- Health Care Facilities/Hospitals
- Women with Symptomatic Uterine Fibroids who are Considering Surgical Options
- Manufacturers of Devices used for Minimally Invasive Surgeries

Medical Specialties: Pathology, Internal Medicine, Nursing, Obstetrics/Gynecology, Oncology, Obstetrical/Gynecological Surgery, General Surgery

Product:

Laparoscopic power morcellators are medical devices used during certain types of laparoscopic (minimally invasive) surgeries. These can include certain procedures to treat uterine fibroids, such as resecting the uterus (hysterectomy) or removing the uterine fibroids (myomectomy). Morcellation refers to the division of tissue into smaller pieces or fragments and is often used during laparoscopic surgeries to facilitate the removal of tissue through small incision sites.

Purpose:

When a hysterectomy or myomectomy is performed in women with uterine fibroids, laparoscopic power morcellation poses a risk of spreading an unsuspected cancerous tissue, notably uterine

sarcomas, beyond the uterus. The FDA is warning against using laparoscopic power morcellators in the majority of women undergoing hysterectomy or myomectomy for uterine fibroids. Health care providers and patients should carefully consider available alternative treatment options for the removal of symptomatic uterine fibroids.

Summary of Problems and Scope

Uterine fibroids are non-cancerous growths that develop from the muscular lining of the uterus. Most women will develop uterine fibroids (also called leiomyomas) at some point in their lives, although most cause no symptoms. In some cases, however, fibroids can cause symptoms, including heavy or prolonged menstrual bleeding, pelvic pressure or pain, and/or frequent urination, requiring medical or surgical therapy.

Many women choose to undergo laparoscopic hysterectomy or myomectomy because these procedures are associated with benefits such as a shorter post-operative recovery time and a reduced risk of infection compared to abdominal hysterectomy and myomectomy. Many of these laparoscopic procedures are performed using a power morcellator.

Based on an FDA analysis of currently available data, we estimate that approximately 1 in 350 women undergoing hysterectomy or myomectomy for the treatment of fibroids is found to have an unsuspected uterine sarcoma, a type of uterine cancer that includes leiomyosarcoma. At this time, there is no reliable method for predicting or testing whether a woman with fibroids may have a uterine sarcoma.

If laparoscopic power morcellation is performed in women with unsuspected uterine sarcoma, there is a risk that the procedure will spread the cancerous tissue within the abdomen and pelvis, significantly worsening the patient's long-term survival. While the specific estimate of this risk may not be known with certainty, the FDA believes that the risk is higher than previously understood.

Because of this risk and the availability of alternative surgical options for most women, the FDA is warning against the use of laparoscopic power morcellators in the majority of women undergoing myomectomy or hysterectomy for treatment of fibroids.

Preface

Since our prior edition in 2006, much has progressed in gynecology. Most notably as this book was going to press, the FDA in the US issued a black box warning on 11/24/2014 regarding the use of laparoscopic power morcellators. Please see the following statement released by the FDA and we recommend that the reader stay abreast of this evolving situation.

UPDATED Laparoscopic Uterine Power Morcellation in Hysterectomy and Myomectomy: FDA Safety Communication

The following information updates our April 17, 2014 communication.

Date Issued: Nov. 24, 2014

Audience:

- Health Care Providers
- Medical Professional Associations
- Cancer Advocacy Organizations
- Health Care Facilities/Hospitals
- Women with Symptomatic Uterine Fibroids who are Considering Surgical Options
- Manufacturers of Devices used for Minimally Invasive Surgeries

Medical Specialties: Pathology, Internal Medicine, Nursing, Obstetrics/Gynecology, Oncology, Obstetrics/Gynecological Surgery, General Surgery

Product:

Laparoscopic power morcellators are medical devices used during different types of laparoscopic (minimally invasive) surgeries. These can include certain procedures to treat uterine fibroids, such as removing the uterus (hysterectomy) or removing the uterine fibroids (myomectomy). Morcellation refers to the division of tissue into smaller pieces or fragments and is often used during laparoscopic surgeries to facilitate the removal of tissue through small incision sites.

Purpose

When used for hysterectomy or myomectomy in women with uterine fibroids, laparoscopic power morcellation poses a risk of spreading unsuspected cancerous tissue, notably uterine

sarcomas, beyond the uterus. The FDA is warning against using laparoscopic power morcellators in the majority of women undergoing hysterectomy or myomectomy for uterine fibroids. Health care providers and patients should carefully consider available alternative treatment options for the removal of symptomatic uterine fibroids.

Summary of Problem and Scope

Uterine fibroids are non-cancerous growths that develop from the muscular tissue of the uterus. Most women will develop uterine fibroids (also called leiomyomas) at some point in their lives, although most cause no symptoms¹. In some cases, however, fibroids can cause symptoms, including heavy or prolonged menstrual bleeding, pelvic pressure or pain, and/or frequent urination, requiring medical or surgical therapy.

Many women choose to undergo laparoscopic hysterectomy or myomectomy because these procedures are associated with benefits such as a shorter post-operative recovery time and a reduced risk of infection compared to abdominal hysterectomy and myomectomy². Many of these laparoscopic procedures are performed using a power morcellator.

Based on an FDA analysis of currently available data, we estimate that approximately 1 in 350 women undergoing hysterectomy or myomectomy for the treatment of fibroids is found to have an unsuspected uterine sarcoma, a type of uterine cancer that includes leiomyosarcoma. At this time, there is no reliable method for predicting or testing whether a woman with fibroids may have a uterine sarcoma.

If laparoscopic power morcellation is performed in women with unsuspected uterine sarcoma, there is a risk that the procedure will spread the cancerous tissue within the abdomen and pelvis, significantly worsening the patient's long-term survival. While the specific estimate of this risk may not be known with certainty, the FDA believes that the risk is higher than previously understood.

Because of this risk and the availability of alternative surgical options for most women, **the FDA is warning against the use of laparoscopic power morcellators in the majority of women undergoing myomectomy or hysterectomy for treatment of fibroids.**

Limiting the patients for whom laparoscopic morcellators are indicated, the strong warning on the risk of spreading unsuspected cancer, and the recommendation that doctors share this information directly with their patients, are part of FDA guidance to manufacturers of morcellators. The guidance strongly urges these manufacturers to include this new information in their product labels.

Recommendations for Health Care Providers

- Be aware of the following new contraindications recommended by the FDA:
 1. Laparoscopic power morcellators are contraindicated for removal of uterine tissue containing suspected fibroids in patients who are peri- or post-menopausal, or who are candidates for en bloc tissue removal, for example through the vagina or mini-laparotomy incision. (Note: These groups of women represent the majority of women with fibroids who undergo hysterectomy and myomectomy.)
 2. Laparoscopic power morcellators are contraindicated in gynecologic surgery in which the tissue to be morcellated is known or suspected to contain malignancy.
- Be aware of the following new boxed warning recommended by the FDA:
The FDA warns that uterine tissue may contain unsuspected cancer. The use of laparoscopic power morcellators during fibroid surgery may spread cancer, and decrease the long-term survival of patients. This information should be shared with patients when considering surgery with the use of these devices.
- Carefully consider all the available treatment options for women with uterine fibroids.
- Thoroughly discuss the benefits and risks of all treatments with patients. Be certain to inform the small group of patients for whom laparoscopic power morcellation may be an acceptable therapeutic option that their fibroid(s) may contain unexpected cancerous tissue and that laparoscopic power morcellation may spread the cancer, significantly worsening their prognosis. This population might include some younger women who want to maintain their fertility or women not yet peri-menopausal who wish to keep their uterus after being informed of the risks.

Recommendations for Women

- Ask your health care provider to discuss all the options available to treat your condition. There are risks and benefits associated with all medical devices and procedures and you should be aware of them.
- If your doctor recommends laparoscopic hysterectomy or myomectomy, ask him/her if power morcellation will be performed during your procedure, and to explain why he or she believes it is an appropriate treatment option for you.

- If you have already undergone a hysterectomy or myomectomy for fibroids, tissue removed during the procedure is typically tested for the presence of cancer. If you were informed these tests were normal and you have no symptoms, routine follow-up with your physician is recommended. Patients with persistent or recurrent symptoms or questions should consult their health care provider.
- A number of additional surgical treatment options are available for women with symptomatic uterine fibroids including traditional surgical hysterectomy (performed either vaginally or abdominally) and myomectomy, laparoscopic hysterectomy and myomectomy without morcellation, and laparotomy using a smaller incision (minilaparotomy). All treatments carry risk, and you should discuss them thoroughly with your health care provider.

FDA Actions

The FDA has taken the following actions in light of scientific information that suggests that the use of laparoscopic power morcellators may contribute to the spread and upstaging of unsuspected uterine cancer in women undergoing hysterectomy and myomectomy for fibroids:

- The FDA conducted a review of published and unpublished scientific literature, including patients operated on from 1980 to 2011 to estimate the prevalence of unsuspected uterine sarcoma and uterine leiomyosarcoma in patients undergoing hysterectomy or myomectomy for presumed benign fibroids (leiomyoma). This analysis led us to believe that the prevalence of unsuspected uterine sarcoma in patients undergoing hysterectomy or myomectomy for presumed benign leiomyoma is 1 in 352 and the prevalence of unsuspected uterine leiomyosarcoma is 1 in 498. Both of these estimates are higher than the clinical community previously understood.
- Convened a meeting of the Obstetrics and Gynecological Medical Device Advisory Panel in July 2014. The panel discussed patient populations in which laparoscopic power morcellators should not be used, mentioning specifically patients with known or suspected malignancy. The panel also discussed mitigation strategies such as labeling, and suggested that a boxed warning related to the risk of disseminating unsuspected malignancy would be useful.
- Issued an Immediately In Effect (IIE) guidance that asks manufacturers of new and existing laparoscopic power morcellators to include two contraindications and a boxed warning in their product labeling. This information warns against using laparoscopic power morcellators in the majority of women undergoing myomectomy or hysterectomy and recommends doctors share this information with their patients.
- Published safety information related to these devices and alternative treatment options for the treatment of fibroids

available on its website to help people better understand the risks of laparoscopic power morcellators.

In addition to the most recent contraindications and boxed warning, the FDA continues to consider other steps that may further reduce such risk – such as encouraging innovative ways to better detect uterine cancer and containment systems designed specifically for gynecological surgery.

The FDA will continue to review adverse event reports, peer-reviewed scientific literature, and information from patients, health care providers, gynecologic and surgical professional societies, and medical device manufacturers.

Reporting Problems to the FDA

Prompt reporting of adverse events can help the FDA identify and better understand the risks associated with medical devices. If you suspect that a morcellator and/or specimen bag has malfunctioned or contributed to a serious injury or adverse outcome, the FDA encourages you to file a voluntary report through MedWatch, the FDA Safety Information and Adverse Event Reporting program.

Health care professionals employed by facilities that are subject to the FDA's user facility reporting requirements should follow the reporting procedures established by their facilities.

Federal law requires hospitals to report some adverse events related to medical devices. Specifically, federal regulations require user facilities to report a suspected medical device-related death to both the FDA and the manufacturer. User facilities must also report a medical device-related serious injury to the manufacturer or to the FDA if the medical device manufacturer is unknown.

With regard to the spread of unsuspected cancer when using laparoscopic power morcellation for hysterectomy or myomectomy in women with symptomatic uterine fibroids, the FDA considers this to be reportable as a serious injury.

Other Resources

- FDA News Release: FDA warns against using laparoscopic power morcellators to treat uterine fibroids
- Recommended Labeling Statements for Laparoscopic Power Morcellators (PDF - 151KB)
- Immediately in Effect Guidance Document: Product Labeling for Laparoscopic Power Morcellators - Guidance for Industry and Food and Drug Administration Staff
- FDA Obstetrics and Gynecology Panel Meeting Materials- July 10 and 11, 2014
- Society of Gynecologic Oncology (SGO)'s position statement on morcellation published in December 2013
- American Congress of Obstetricians and Gynecologists (ACOG)'s Statement on Choosing the Route of Hysterectomy for Benign Disease November 2009 (Reaffirmed 2011)

- *American Association of Gynecologic Laparoscopists (AAGL)'s AAGL Member Update: Disseminated Leiomyosarcoma With Power Morcellation 2014*

References

1. NIH Fact Sheet on Uterine Fibroids. March 2013. Available at <http://report.nih.gov/nihfactsheets/viewfactsheet.aspx?csid=50>
2. Nieboer TE, Johnson N, Lethaby A, et al. Surgical approach to hysterectomy for benign gynecological disease. Cochrane Database Syst Rev. 2009;(3):CD003677.
3. Ibid.

Contact Information

If you have questions about this communication, please contact the Division of Industry and Consumer Education (DICE) at DICE@FDA.HHS.GOV, 800-638-2041 or 301-796-7100.

<http://www.fda.gov/MedicalDevices/Safety/AlertsandNotices/ucm424443.htm>, (accessed 1/11/2015).

We have witnessed progress in every subspecialty. To highlight but a few accomplishments: in family planning, there has been an expansion of indications for long-acting reversible contraceptives; in genetics, preimplantation genetic diagnosis has extended genetic testing; in reproductive endocrinology and infertility, the pathophysiology associated with polycystic ovarian syndrome has become clearer and we are more aware of the importance of lifestyle and options with regard to ovulation induction, including the use of letrozole. A number of controlled randomized clinical trials have been published (e.g. the Kronos Early Estrogen Prevention [KEEPS] study) and cardiovascular studies have been greatly extended. Across all spectrums of society, the incidence and consequences of obesity, including in teenagers and children, are challenging.

The use of minimally invasive surgery has become extensive in many areas, including gynecologic oncology, urogynecology, reproductive endocrinology, and obstetrics. Less vaginal surgery is occurring, for example to manage problems such as abnormal vaginal bleeding, being replaced in part by minimally invasive surgical techniques and in part by non-surgical options. Robotics and the provision of three-dimensional approaches, with enhanced degrees of freedom of motion, have allowed new ways of accessing surgical problems. Ultrasonography with three- and four-dimensional approaches allows the provision of unprecedented detail in a more cost-effective scenario.

Research has evolved in areas such as stem cell therapy and ovarian, testicular, and oocyte cryopreservation to avoid infertility for patients with cancer. Cord blood banking continues to be a possibility for the future.

The stage is set, the textbook needed to be written and now to be read. In the planning stages, the editors continued to conceptualize a textbook that would be heavily illustrated with tables and figures and designed to facilitate learning. Our textbook stands apart from others, with a format that provides the reader with state of the art information packaged in a

succinct, ready to remember approach. It has been compiled by authorities in virtually every field of gynecology and conveys what is current and built upon a solid foundation. Each chapter is designed to be "stand alone," with authors carefully conveying a panoramic view of subject matter.

The depth and breadth of the current edition has been expanded in an attempt to provide the reader, whether student, resident, attending physician, or allied health professional, with "information pearls" at their finger tips. The editors hope you will reap the benefits of these efforts.

We wish to acknowledge our secretarial staff, including Mary Turner, as well as Dr. Meredith Snook for their assistance with the progression of the textbook. We are indebted for their time and dedication to completion of the textbook. We hope you enjoy the format and information provided.

Eric J. Bieber
Joseph S. Sanfilippo
Ira R. Horowitz
Mahmood I. Shafi

Video Components

Coordinated by: Nicole M. Donnellan, MD in association with Ted Lee, MD and Suketu Mansuria, MD

1. Male Infertility

1.1. Microsurgical Vasectomy Reversal:

Vasovasostomy and Vasoepididymostomy

Matthew G. McIntyre, MD and Larry I. Lipshultz, MD

Vasectomy is one of the most common procedures performed by urologists. Up to 6% of men after vasectomy will request reversal. This video describes the two procedures for vasectomy reversal, the indications for each and outcomes currently in the literature. The cost effectiveness of vasectomy reversal is also discussed.

1.2. The Inguinal Varicocele Repair

Matthew G. McIntyre, MD and Larry I. Lipshultz, MD

Varicoceles are present in up to 40% of infertile men. Here we present a brief overview of varicoceles and then show an operative case of an inguinal varicocelectomy. Varicocelectomy outcomes for fertility are also addressed.

1.3. Combined Laparoscopic and Microsurgical Technique for Vasovasostomy of the Obstructed Inguinal Vas Deferens

Matthew G. McIntyre, MD, Richard E. Link, MD, and Larry I. Lipshultz, MD

The use of mesh for inguinal hernia repairs can result in obstruction of the inguinal vas deferens. This requires mobilization of the intra-abdominal portion of the vas for reconstruction. This video details such a case and includes the surgical technique for both the laparoscopic and microsurgical portions.

2. Domestic Violence

Domestic Violence (associated with Chapter 7) Video Vignettes—Understanding Domestic Violence from Survivor's Stories

Women's Center and Shelter of Greater Pittsburgh (For additional information on the Women's Center and Shelter of Greater Pittsburgh and additional vignettes please visit this website address: <http://www.wcspittsburgh.org>)

2.1. Survivor Story - Andrea

2.2. Survivor Story - Alyce

2.3. Survivor Story - Barbara

2.4. Survivor Story - Dave

It is estimated that 25-30% of women in the United States experience intimate partner violence (IPV). Obstetricians and gynecologists have a unique opportunity to identify, address and assist in patients suffering from IPV. While upwards of 1.5million women experience physical or sexual violence from a current or former intimate partner each year in the U.S., it is important to understand the many more family members that can be affected by IPV. The Women's Center and Shelter of Greater Pittsburgh is a non-profit, community based, victims' advocacy program in Western Pennsylvania. The Women's Center and Shelter not only helps victims but also promotes broader awareness and understanding of IPV in the community and offers educational and support services to law enforcement, medical providers, employers and schools. Here, the shelter shares personal vignettes of victims in hopes of increasing awareness and understanding of the far-reaching consequences of IPV.

3. Laparoscopic Procedures for Endometriosis

3.1. Laparoscopic Excision of Peritoneal Endometriosis and Oophoropexy

Nicole M. Donnellan, MD and Ted Lee, MD

This video illustrates laparoscopic excision of peritoneal endometriosis utilizing traditional monopolar as well as advance bipolar technology. Laparoscopic oophoropexy is also demonstrated, a technique used to minimize recurrent ovarian adhesions when aggressive dissection of the underlying ovarian fossa is performed.

3.2. Laparoscopic Presacral Neurectomy

Linda Yang, MD and Suketu Mansuria, MD

AAGL SurgeryU (www.surgeryu.com)

Randomized controlled trials have demonstrated presacral neurectomy to be an effective adjuvant procedure for pelvic pain associated with endometriosis. Presacral neurectomy can be performed safely and efficiently via the laparoscopic approach. The presacral nerve, or superior hypogastric plexus, typically resides in the midline, or left of midline, as demonstrated in cadaveric dissections. The traditional approach to presacral neurectomy, as reported throughout the literature, utilizes a transverse incision over the sacral promontory. Here an alternate approach utilizing a vertical peritoneal incision is demonstrated, which proves to be a safe, alternative method for complete transection and removal of the nerve.

3.3. Laparoscopic Excision of Bowel Endometrioma

Camran Nezhat, MD

The video demonstrates a patient who presented with pelvic pain and bowel symptoms of alternating diarrhea and constipation. Pelvic ultrasound revealed a pelvic mass. At time of laparoscopy, the pelvic mass was found to be arising from the anterior wall of the rectosigmoid colon. Combination of plasma jet and CO₂ laser are used to safely excise the endometrioma of the bowel. Proctoscopy is performed to check the integrity of the bowel.

3.4. Laparoscopic Excision and Repair of Diaphragm Endometriosis

Camran Nezhat, MD

Video thoracoscopy shows a diaphragmatic defect in a patient with recurrent catamenial pneumothorax. The edges of the defect are re-approximated with clips and permanent Ethibond sutures on an Endoknot are used to repair the defect. Endo GIA Staplers are also used to excise endometriosis of the right hemidiaphragm.

3.5. Laparoscopic Excision of Endometriosis Necessitating Ureterolysis

Camran Nezhat, MD

This video demonstrates excision of endometriosis over the serosa of the right ureter. The CO₂ laser is used with hydrodissection to allow for safe excision of the endometriotic lesion, as the CO₂ laser does not penetrate water.

3.6. Use of Advanced Bipolar Energy and Barbed Suture in Laparoscopic Excision of Bladder Endometriosis

Nicole M. Donnellan, MD and Ted Lee, MD

AAGL SurgeryU (www.surgeryu.com)

Endometriosis of the urinary tract is a rare entity, affecting less than 1% of all women with endometriosis, with bladder endometriosis representing 85% of these cases. Surgical resection has been shown to be effective in eliminating symptoms, although recurrence rates are higher in transurethral procedures as compared to traditional laparotomy. More recently, the laparoscopic approach to excision, in skilled hands, has proven safe and effective. While often done with traditional monopolar and bipolar instruments, excision in these tissue planes is often bloody, leading to an obscured surgical field. Here we demonstrate a safe and effective technique incorporating the use of the advanced bipolar Enseal TRIO and a barbed suture in 2 cases of bladder endometriosis. Through the use of this advanced technology in bladder nodule enucleation, we are able to improve hemostasis and visualization as well as maximize efficiency.

3.7. Systematic Approach to the Obliterated Cul De Sac and Excision of Rectovaginal Endometriosis

Jay Hudgens, MD and Resad P. Pasic, MD, PhD

AAGL SurgeryU (www.surgeryu.com)

The purpose of this video is to present a systematic approach to the obliterated cul de sac and rectovaginal endometriosis. This approach is based on the understanding of fundamental anatomic principles. An emphasis is placed on the surgeon's ability to perform ureterolysis and utilize the avascular spaces in the pelvis in order to safely resect deeply infiltrative disease. Three cases are presented in this video. The first case shows the approach to the dissection of the obliterated cul de sac. The second case demonstrates the excision of a large rectovaginal nodule. The third case shows an incidental entry into the posterior vagina and subsequent repair. By following the systematic approach presented and applying the anatomic principles highlighted, a more efficient dissection and safe resection of rectovaginal endometriosis can be performed.

4. Laparoscopic Gynecologic Procedures

4.1. Difficult Bladder Flaps: Tips and Tricks at Time of Total Laparoscopic Hysterectomy

Nicole M. Donnellan, MD and Suketu Mansuria, MD

Surgeon reluctance to perform a hysterectomy via the laparoscopic approach is often due to a patient's surgical history. Cesarean sections are one such surgery that can create pathology, such as severe adhesive disease and scarred bladder flaps, making the minimally invasive approach more difficult. With a nationwide increase in the rate of cesarean sections, such pathology will become encountered more frequently. In this video we describe tips and techniques to assist in performing a difficult laparoscopic bladder flap in women with prior cesarean sections to assist minimally invasive surgeons in completing even the most advanced of procedures with minimal complications.

4.2. Basic Pearls of Laparoscopic Hysterectomy

Resad P. Pasic, MD, PhD and Michael Traynor, MD, MPH
AAGL SurgeryU (www.surgeryu.com)

More and more gynecologic surgeons are performing laparoscopic hysterectomy despite a lack of formal training. The purpose of this video is to provide a series of basic pearls recognizing key aspects of a laparoscopic approach to hysterectomy. Techniques in port placement, identification of anatomy, exposure, bladder flap dissection, securing the uterine artery, creation of colpotomy and specimen retrieval are all emphasized and reviewed.

4.3. Suturing in Parallel and Perpendicular Planes: A Systematic and Geometric Approach to Laparoscopic Suturing and Intracorporeal Knot Tying

Jay Hudgens, MD and Resad P. Pasic, MD, PhD
AAGL SurgeryU (www.surgeryu.com)

Laparoscopic suturing is a complex task that requires many hours of practice and experience to perform proficiently. The main obstacle in learning to suture laparoscopically is overcoming the perception of a three dimensional operative field presented on a 2 dimensional monitor. The purpose of this video is to present a systematic approach to laparoscopic suturing based on geometric principles. This system highlights the importance of understanding and utilizing perpendicular and parallel planes and can be applied regardless of port configuration. We also highlight visual cues that experienced surgeons utilize to aid in depth perception, which help improve surgical accuracy and efficiency.

4.4. Laparoscopic Supracervical Hysterectomy

Steven McCarus, MD

This sequence of videos demonstrates a 39 year old with a symptomatic fibroid uterus and right hydroureter who elected to undergo laparoscopic supracervical hysterectomy for definitive surgical management.

Video 1: Using the advanced bipolar EnSeal, the anterior board to the uterine vessel on the left side are coagulated and cut.

Video 2: This clip commences with the completion of the right side of the hysterectomy. It also demonstrates the Harmonic Ace reverse cone drilling technique, revealing how the uterus should be transected at the level of the uterosacral cardinal ligaments.

4.5. Laparoscopic Uterine Artery Ligation: An Essential Technique in Advanced Gynecologic Surgery

Nicole M. Donnellan, MD and Ted Lee, MD

Laparoscopic ligation of the uterine artery at its origin is necessary when traditional approaches to securing the ascending uterine are unsafe or impossible. Execution of this

technique improves safety and minimizes conversion. In this video, two lateral, retroperitoneal approaches are demonstrated, both of which are an essential part of the advanced laparoscopic surgeon's armamentarium.

4.6. Laparoscopic Excision of Ovarian Remnant: Two Cases Demonstrating Ligation of the Uterine Artery at Its Origin

Deborah Arden, MD and Ted Lee, MD
AAGL SurgeryU (www.surgeryu.com)

Excision of an ovarian remnant often requires an extensive retroperitoneal dissection. This video presents two cases of laparoscopic excision of ovarian remnants that required ligation of the uterine artery at its origin. These cases clearly demonstrate the retroperitoneal pelvic anatomy, including the internal iliac artery giving rise to the uterine artery, the ureter, and the pararectal and paravesical spaces. This video is intended to review the pertinent anatomy that is vital to successfully completing the retroperitoneal dissection, and to demonstrate the techniques necessary for laparoscopic excision of an ovarian remnant.

4.7. Laparoscopic Repair of an Omental Hernia

Camran Nezhat, MD

This is a video presentation of an omental hernia repair in a morbidly obese patient. The patient underwent a laparoscopic right salpingo-oophorectomy and presented with persistent right-sided pain for 1 week after her surgery. Here we demonstrate the omental herniated sac being removed from the subcutaneous space and the fascial defect closed using a Carter-Thomason device.

5. Robotic Gynecologic Procedures

5.1. Robotic Sacrocolpopexy

Tiffany Jackson, MD and Arnold Advincula, MD, FACOG, FACS

This is a case of a fifty-nine year old gravida two para two with grade three vaginal vault prolapse and cystocle after a previous total abdominal hysterectomy and bilateral salpingo-oophorectomy. A Coloplast Restorelle Y mesh is used to perform a robot assisted laparoscopic sacrocolpopexy. A four Da Vinci robotic arm technique is used. The Cooper Surgical Sacrocolpopexy tip is placed in the vagina on the uterine positioning system to facilitate suturing to the vagina. The anterior and posterior arms of the mesh are sutured with 2-0 gortex suture and the sacral arm of the mesh is sutured to the anterior longitudinal ligament using 2-0 ethibond suture. The total operating time was approximately three hours. The patient was admitted for twenty-three hour observation. The blood loss was minimal. There were no postoperative or intraoperative complications.

5.2. Robotic Myomectomy for an Eleven Centimeter Uterine Fibroid

Tiffany Jackson, MD and Arnold Advincula, MD, FACOG, FACS

This is a case of a 29 year old gravida zero with a symptomatic uterine fibroid. The patient experienced heavy menstrual bleeding resulting in anemia and urinary frequency. Pelvic MRI revealed an 11 x 7.5 x 8.5-centimeter fibroid in the posterior aspect of the uterus. A four arm Da Vinci robotic technique is used. The uterus is injected with diluted vasopressin. The fibroid is debulked and enucleated. The hysterotomy is closed with V-Loc suture. Interceed is placed over the hysterotomy. The estimated blood loss was 100 cc. Pathology revealed three hundred ninety grams of uterine leiomyoma. The operating time was approximately three hours. The patient was discharged to home on the same day of the surgery and experienced no complications.

5.3. Three Arm Robotic Hysterectomy for a 24 Week Size Uterus

Tiffany Jackson, MD and Arnold Advincula, MD, FACOG, FACS

AAGL SurgeryU (www.surgeryu.com)

The large uterus presents a challenge to performing a hysterectomy laparoscopically. This video demonstrates a robot-assisted total laparoscopic hysterectomy for a 24 week size fibroid uterus. Three Da Vinci robotic arms and a 5mm accessory port were used to complete the procedure on a 1200 gram fibroid uterus. An Advincula Arch uterine manipulator is used with a KOH efficient colpotomizer. The operating time was approximately 90 minutes. The estimated blood loss was 75mL and there were no intraoperative or postoperative complications.

6. Hysteroscopy

6.1. Hysteroscopic Adhesiolysis with an Intrauterine Morcellator and Bipolar Loop

Shruti Malik, MD and Joseph S. Sanfilippo, MD

This patient presented after a previous myomectomy with dense intrauterine adhesions. We initiate resection of the adhesions with the intrauterine morcellator. First, we line up the inner rotating barrel with the outer portion of the morcellator. Then we begin to thin out the adhesive bands in the uterine cavity as well as a moderate amount of proliferative endometrium obscuring adequate visualization. We do this by lining up the black lines again the intended area of resection and applying light pressure against the tissue. When the morcellator is activated, the rotating inner barrel acts to morcellate the tissue as well as pull it out with light suction. In the second portion of the video, the bipolar cautery loop is then utilized to continue the adhesiolysis. In a similar fashion to resecting a

uterine septum, light pressure is applied at the base of the adhesion and small bursts of electrocautery are used to help separate the tissue. The loop can then be used to gradually shave down the excess tissue and even out the uterine contour. This hysteroscopy is paired with laparoscopy to aid in prevention and recognition of uterine perforation as well as retraction of the small bowel. At the end of the surgery, the uterine cavity appears within normal limits and the tubal ostia are flush with one another.

6.2. Hysteroscopic Metroplasty

Shruti Malik, MD and Joseph S. Sanfilippo, MD

This patient presented with a complete uterovaginal septum. The vaginal septum was previously resected. At this time, we complete resection of the cervical and uterine portions of the septum. Here you can see the cervical portion of the septum which was dissected under direct visualization with heavy scissors. Once the cervical septum was transected, the hysteroscopic scissors were then used to continue the dissection at the uterocervical junction and lower uterine segment. As you can see, due to the vascularity of this septum, the visualization is suboptimal and the procedure is then continued with a bipolar cautery loop. The loop can be applied at the base of the septum and small burst of electrocautery are used to separate the tissue. This procedure is continued gradually sweeping from side to side along the width of the septum as dissection continues towards the uterine fundus. At the thickest portions of the septum, you can see that the loop is used to gradually shave down the tissue and aid in hemostasis. As we near the end of the procedure, we zoom in to note the appearance of the myometrial fibers indicating that we have reached an endpoint. We use the loop to even out the residual tissue protruding into the uterine cavity and complete the procedure. This hysteroscopy is paired with laparoscopy to aid in prevention and recognition of uterine perforation as well as retraction of the small bowel.

6.3. Hysteroscopic Septolasty

Camran Nezhat, MD

This video demonstrates hysteroscopic septoplasty using hysteroscopic scissors. Simultaneous laparoscopy is performed to help minimize the risk of uterine perforation. An intrauterine catheter and estrogen are used post-operatively to minimize the risk of intrauterine adhesion formation.

7. Vaginoplasty

7.1. Davydov Vaginoplasty

Shweta Nayak, MD, Richard Guido, MD and Joseph Sanfilippo, MD

This video depicts a Davydov vaginoplasty in a 17-year-old, 46, XX female with a history of vaginal agenesis and hypoplastic mullerian structures. The patient herself had no significant