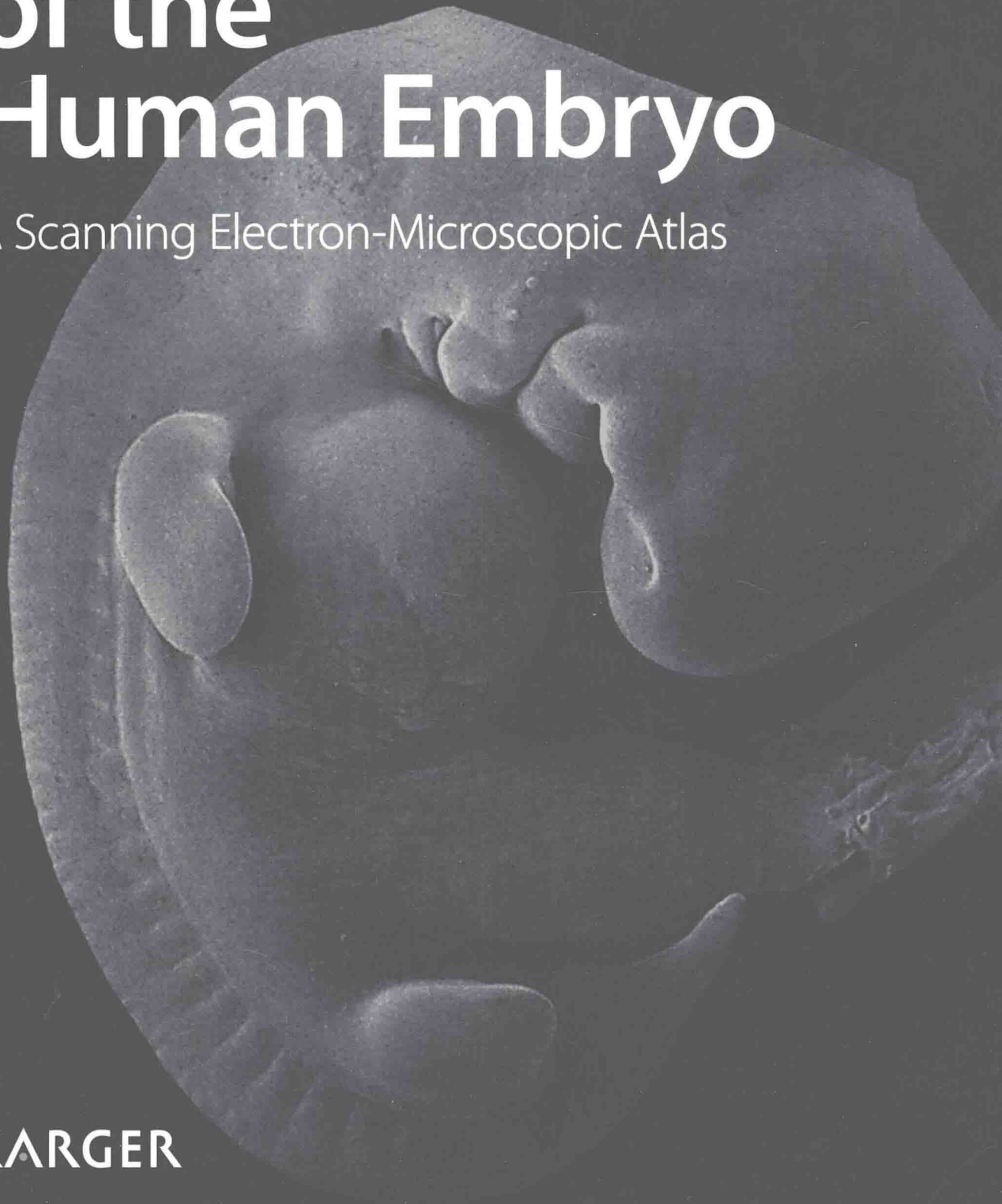


Gerd Steding

# The Anatomy of the Human Embryo

A Scanning Electron-Microscopic Atlas

KARGER



Gerd Steding

# The Anatomy of the Human Embryo

A Scanning Electron-Microscopic Atlas

818 figures, 2009

**KARGER**

Basel • Freiburg • Paris • London • New York • Bangalore •  
Bangkok • Shanghai • Singapore • Tokyo • Sydney

Dr. med. Gerd Steding  
Former Professor of Anatomy and  
Head of the Department of Embryology  
Centre of Anatomy  
University of Göttingen  
Germany

First published 2009  
Second printing 2011

Library of Congress Cataloging-in-Publication Data

Steding, Gerd.

The anatomy of the human embryo : a scanning electron-microscopic atlas /  
Gerd Steding.

p. ; cm.

Includes bibliographical references.

ISBN 978-3-8055-8361-9 (hard cover : alk. paper)

ISBN 978-3-8055-9705-0 (soft cover : alk. paper)

1. Embryology, Human--Atlases. 2. Scanning electron microscopy--Atlases.

I. Title.

[DNLM: 1. Embryo, Mammalian--anatomy & histology--Atlases. 2.

Microscopy, Electron, Scanning--Atlases. QS 617 S812t 2009]

QM602.S738 2009

612.6'40222--dc22

2008026596

Disclaimer. The statements, opinions and data contained in this publication are solely those of the author and not of the publisher. The publisher and the author disclaim responsibility for any injury to persons or property resulting from any ideas, methods, instructions or products referred to in the content or advertisements.

All rights reserved. No part of this publication may be translated into other languages, reproduced or utilized in any form or by any means electronic or mechanical, including photocopying, recording, microcopying, or by any information storage and retrieval system, without permission in writing from the publisher.

© Copyright 2009 by S. Karger AG, P.O. Box, CH-4009 Basel (Switzerland)

[www.karger.com](http://www.karger.com)

Printed in Switzerland on acid-free and non-aging paper (ISO 9706)

by Reinhardt Druck, Basel

ISBN 978-3-8055-8361-9 (hard cover)

ISBN 978-3-8055-9705-0 (soft cover)

# Introduction

In this atlas, the forms of the major human organs during the early weeks of prenatal development are depicted. Illustrations of the external form of human embryos have been published in great numbers and are to be found in numerous textbooks dealing with human embryology. However, we predominantly find a description of organ development with pictures of two-dimensional histological sections or with more or less schematic drawings often made according to historical originals. It is not rare to find in textbooks, even today, pictures of animal embryos as material for human development. Since it has been shown that results for animal embryos cannot always be simply and uncritically applied to human development, in this atlas of human embryology, only original images of the major organs of human embryos during the first few weeks of prenatal development are shown.

For technical reasons, modern developmental biology is almost exclusively concerned with animal embryos. However, it would be somewhat irresponsible to expect that the use of these new procedures could replace the investigation of human embryos with the traditional tools for the description of form. Sometimes, however, it seems that nowadays only molecular biological techniques and methods of developmental biology are considered to be a suitable approach to understanding developmental processes, whereas the classical morphological methods and procedures are increasingly seen as historical and, thereby, as hardly capable of producing good results. Regrettably, with this approach, it is often ignored that reports on the biochemical processes taking place during development can hardly provide a hint as to the ways and means in which they influence form. The fact that the steps taking place at the molecular level during the development of a leg of a mouse or chicken are to a large extent similar, however, offers no explanation as to how the final results of these processes are so different in form. To establish under what circumstances and conditions the arm, for example, of a human being is given its characteristic form, first precise knowledge of the course of development

is necessary. We need to know which steps are involved, from the development of the anlage to the formation of the 'finished' human form.

Only when the course of each individual step in these external changes in form has been understood, can there be a chance of also estimating the molecular incidents in the stages of the development of form.

Therefore, even nowadays, the classical observation, description and analysis of form, its development and change cannot be ignored altogether, neither within the framework of developmental biological nor embryological medical investigations. In this atlas, all that is depicted are those changes in position and form of the organs, which are visible during embryonic development. It is obvious that, together with these visible changes, a succession of processes in submicroscopic molecular dimensions, which are not directly visible, take place.

There has been much conjecture as to the relationship, so to speak, between macroscopic and submicroscopic processes and much has been alleged or even postulated without there having been any success in disproving any one of the hypotheses. Therefore, I restrict myself solely to illustrating phenomena of human organ development which are directly visible and I will keep my views on theories and hypotheses to myself. The reader's concept of human organ development will, on the basis of our specimens, hopefully become more vivid and plastic.

Just as in the anatomical dissection course the organs concealed under the skin are exposed and become visible by dissection, layer for layer, the organs of an embryo can also be exposed and, thereby, made visible in their position and spatial form. As in an anatomical atlas the position and form of human organs are shown, in this atlas the changes in position and form of some of the human organs during prenatal development are seen in photographs of the specimens.

For the selection of the photographs, I made sure that the developmental stages were as close together as possible to make the changes in shapes of the organs clear and comprehensible. To demonstrate the relationships in form and position more reliably than the standard aspects are able to do, images of the same organs photographed from different directions are shown. This cannot, of course, be equally successful for every organ, sim-

ply because the small size of some objects sometimes makes unexpectedly high demands on the patience and dexterity of the author.

It would hardly be surprising if some of the photographs shown here might appear peculiar and strange to the experienced observer of histological and schematic illustrations in textbooks. This could be due to the fact that these specimens also do not appear to be as simple and familiar as the two-dimensional sections and repeatedly drawn schemata so often seen. As in everyday life, also in prenatal development, it is often the inconspicuous events which are most important. Temporally close stages may sometimes appear hardly distinguishable from each other and only upon more exact inspection can a characteristic developmental step be recognized.

Even if it is customary to speak of 'the' human embryo, it must be remembered that, already in his prenatal life, the human being is a unique and unmistakable individual. As far as possible, I have also tried to keep this aspect of the individual development of form in mind. Since the growth of the embryo is precisely in the early weeks a fundamental factor in the development of form, the pictures of all stages of an organ are, in general, shown at the same magnification.

The introductory text to each chapter hardly offers experts anything new. It cannot and should not replace a textbook, but rather explains, only briefly, some of the most significant developmental steps documented in the illustrations. To instruct or teach the readers is not the aim of this atlas, rather it simply offers them an opportunity to develop a more precise conception of the anatomy of the human embryo through the power of their own observations.

In this context, I must accept the fact that the choice of photographs and their number cannot satisfy every reader in equal measure and that unnecessary or even absent aspects may be criticized. However, I have endeavoured to give not only human embryologists but also readers on the periphery of human embryology and interested physicians and also laymen an opportunity to make their own observations.

As expected from an atlas, the pictures of the specimens are what is most important. Some of these pictures offer an unusual aspect and often also only one small detail from a region. In order

to make orientation in the pictures easier for those who are strangers to human embryology, some explanatory terms have been added in small frames with deliberately simple and small line drawings. These should not distract the reader from looking at the photographs and cannot replace the photographs. In a few large format photographs, abbreviations refer to important terms.

To avoid burying the photographs beneath nomenclature, only those illustrations in a chapter have been labelled whose items are not self-explanatory from the previous figure. The nomenclature is oriented on the anatomy of adults as far as possible and on everyday speech and only when unavoidable have technical terms been employed.

## **Materials and Procedures**

The embryos shown here were collected and dissected over a period of more than 25 years. I am very grateful to many colleagues, among them friends in many parts of the world, for their willingness to provide me with their material.

Human beings are not sacrificed especially for the procurement of cadavers for anatomical dissection courses and, for the same reasons, human embryos are neither killed nor bred for the sake of investigation in the field of human embryology. All of the embryos, without exception, were obtained from legal or medically indicated abortions and were all exclusively employed for the investigations described here. For these reasons, the early stages of human development are not depicted since only embryos of at least 4 weeks of age are available.

Following the employment of various techniques, the embryos were fixed in glutaraldehyde or paraformaldehyde, partly post-fixed in Bouin's solution, then dehydrated in an ascending alcohol series and dried with CO<sub>2</sub> using the critical point method. The embryos were mounted on a specimen support and were cool-sputtered with gold or gold-palladium to a thickness of 30 nm.

When the surface layers of a specimen had been photographically documented with the scanning electron microscope (Zeiss Novascan or DSM 960 Zeiss), the deeper layers were exposed with the help of specially made microinstruments, the specimens re-sputtered and re-photographed with the scanning electron mi-

croscope. Dependent on the region under investigation, up to ten layers were exposed and photographed for each embryo.

## Age Determination

It is usually not possible to determine the exact developmental age of an embryo because the time point of fertilization of the egg remains unknown. However, estimation of age based on measurements of the greatest length of the embryo or the crown-rump length was attempted. Since, however, embryos shrink by up to 20% as a result of fixation and the following dehydration dependent upon the techniques employed and, moreover, the extent of shrinkage is dependent on the length of time spent in the various solutions and, of course, just as for adults, there are shorter and taller human embryos, the evaluation of the length cannot be a highly reliable technique for the evaluation of the age.

Streeter's classification of embryos<sup>1</sup> using his term, developmental horizons, was modified by O'Rahilly and Müller<sup>2</sup> who used the term, developmental stages. The disadvantage of this system for the classification into stages is that for the first 8 embryonic weeks only 23 stages are suggested.

Due to the low number of stages in this system, the single stages are not characterized by typical developmental states of all organs, only reached at this stage, but include quite a lot of different maturation states of the organs. Since not all organ systems develop concurrently, but rather, for example, the heart can be somewhat further developed than the stomach, the use of developmental stages seems impractical.

Therefore, only approximate age estimations are given in weeks, estimated from an assumed time point of fertilization of the egg. The classification of the embryo according to developmental weeks is made on the basis of a comparison of the devel-

---

1 Streeter GL: Developmental Horizons in Human Embryos. Carnegie Inst Wash Publ Contrib Embryol 1942;30:211–245; 1945;31:27–63; 1948;32:133–203; 1949;33:149–167; 1951;34:165–196.

2 O'Rahilly R, Müller F: Developmental Stages in Human Embryos, Including a Revision of Streeter's 'Horizons' and a Survey of the Carnegie Collection. Washington, Carnegie Institution of Washington, 1987, Publ No 637.

opmental state of as many embryonic organs as possible with embryos of tolerably exact developmental ages described in the literature.

Since, in obstetrics, for the determination of the age of the embryo the 'first day of the last period' is taken to be the beginning of the pregnancy, the gynaecological age is approximately 2 weeks more than the embryological age given here.

# Acknowledgements

I am very grateful to all the co-workers of my old department for their work in collecting and preparing the material for this atlas.

In particular, Hans-Georg Sydow deserves respect and thanks for his untiring and conscientious efforts in collecting and preparing the samples for the scanning electron microscopy and his unique dexterity in the difficult job of making the microinstruments for the dissection. I am also very grateful for his invaluable help in the solution of difficult technical problems with the scanning electron microscope. Furthermore, in completing the scanning of the negatives, his work proved to be excellent and of inestimable value.

I would also like to thank Kirsten Falk-Stietenroth for her photographic work in the darkroom which she carried out with unsurpassed conscientiousness, great commitment and unique aesthetic competence.

I would like to express my gratitude to Anja Aue for taking on the building up of the archives of the specimens and the photographs with great thoroughness, thus making an important contribution to the maintenance of order.

I am also grateful to Cyrilla Maelicke for translating the text.

And, finally, I would like to thank Dr. Jörg Männer who as acting head of my old department generously made it possible for me to complete this atlas in my old familiar setting after my retirement. Also following the restructuring of the departments, I was able to continue my work calmly and without interruption in the Centre of Anatomy, for which I expressly thank Dr. Viebahn.

Finally, I am highly indebted to the head of the publishing house and all members of staff for their meticulous reproduction of the substantial number of illustrations and the outstanding design of the atlas.

# Contents

|  |      |
|--|------|
| Introduction .....   | VII  |
| Acknowledgements .....   | XIII |
| <hr/>  |      |
| 1. <b>External Aspects</b> .....                               | 1    |
| 1.1 The External Form of the Embryo .....                      | 2    |
| 1.2 The Development of the Face .....                          | 14   |
| 1.3 The Development of the Pharyngeal Arches .....             | 38   |
| 1.4 The Development of the Upper Limb .....                    | 66   |
| 1.5 The Development of the Lower Limb .....                    | 88   |
| 1.6 The Development of the External Genitalia .....            | 108  |
| <hr/>  |      |
| 2. <b>Endodermal Organs in the Head and Neck</b> .....         | 123  |
| 2.1 The Development of the Walls of the Oral Cavity .....      | 124  |
| 2.2 The Development of the Nose .....                          | 146  |
| 2.3 The Development of the Palate .....                        | 166  |
| 2.4 The Development of the Pharynx .....                       | 178  |
| 2.5 The Development of the Larynx .....                        | 188  |
| 2.6 The Position of the Thymus and the Parathyroid Gland ..... | 196  |
| <hr/>  |      |
| 3. <b>Organs in the Thorax</b> .....                           | 203  |
| 3.1 The Development of the Heart .....                         | 204  |
| 3.2 The Development of the Lungs .....                         | 254  |
| <hr/>  |      |
| 4. <b>Organs in the Abdomen</b> .....                          | 285  |
| 4.1 The Development of the Small Intestine .....               | 286  |
| 4.2 The Development of the Liver .....                         | 298  |
| 4.3 The Great Vessels of the Trunk .....                       | 318  |
| 4.4 The Development of the Stomach .....                       | 332  |
| 4.5 The Origin of the Spleen .....                             | 348  |
| 4.6 The Development of the Pancreas .....                      | 356  |
| <hr/>  |      |
| 5. <b>Urogenital Organs</b> .....                              | 369  |
| 5.1–5.4 The Development of the Urinary Organs .....            | 370  |
| 5.5 The Development of the Gonads .....                        | 406  |
| 5.6 The Reproductive Pathways .....                            | 412  |
| <hr/>  |      |
| 6. <b>Brain and Sensory Organs</b> .....                       | 421  |
| 6.1 The Development of the Brain .....                         | 422  |
| 6.2 The Development of the Eye .....                           | 468  |
| 6.3 The Middle and the Internal Ear .....                      | 486  |
| 6.4 The Spinal Cord .....                                      | 500  |
| Index .....  | 506  |

---

1

# External Aspects



---

1.1

## **The External Form of the Embryo**

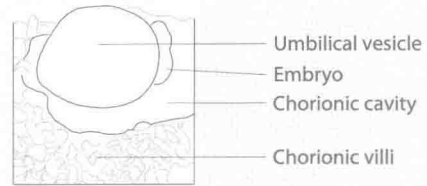
According to the regulations applied here to obtain the specimens, human embryos of the first 3 weeks could not be obtained. Furthermore, the modern techniques of abortion usually do not provide the conditions necessary for obtaining uninjured specimens.

Gaps are consequently inevitable and, therefore, the stages presented here are barely sufficient to give a detailed outlook of the development of the external appearance of human embryos.

## Week 4

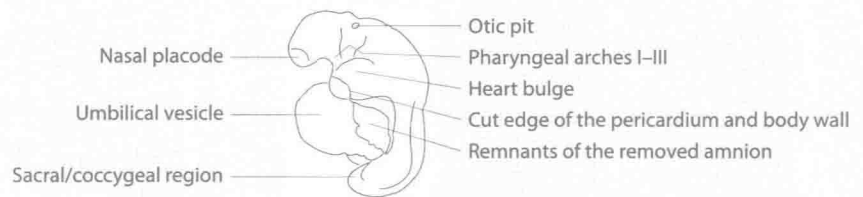
# 1. External Aspects

## 1.1 The External Form of the Embryo

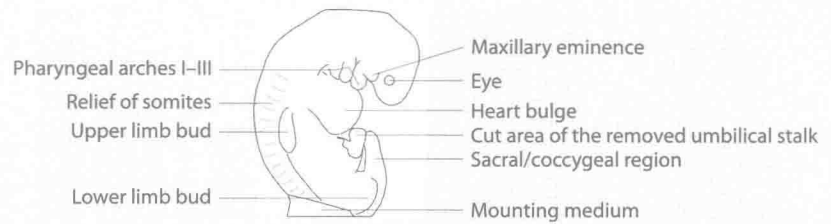


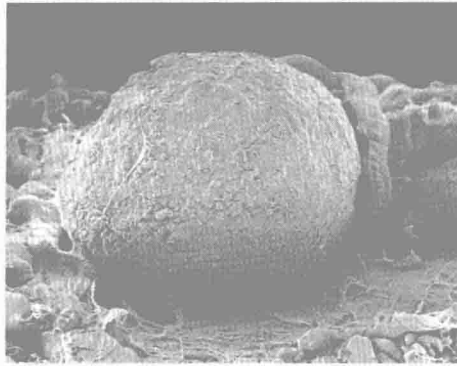
### 1.1.01–1.1.13

## Development of the external form of the embryo. Lateral views.

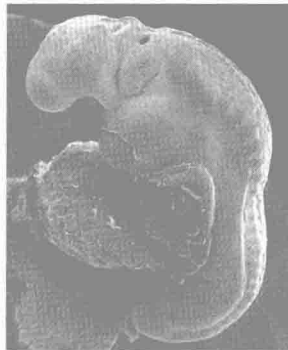


## Week 5

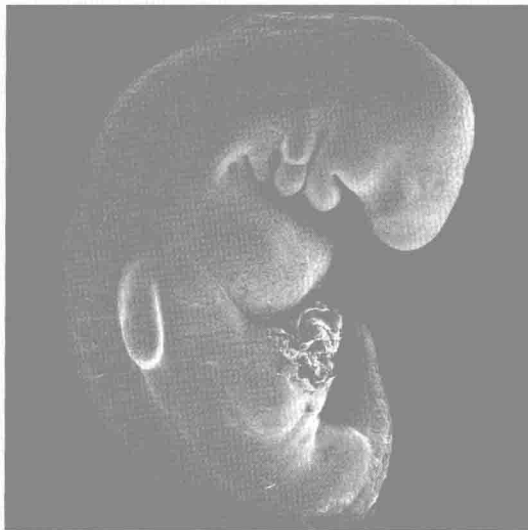




1.1.01 Embryo at the beginning of week 4. The amnion has been removed.



1.1.02 Embryo at the end of week 4. The umbilical vesicle is partly collapsed.



1.1.03 Embryo at week 5.

## Week 5

# 1. External Aspects

## 1.1 The External Form of the Embryo

1.1.01–1.1.13

### Development of the external form of the embryo. Lateral views.

