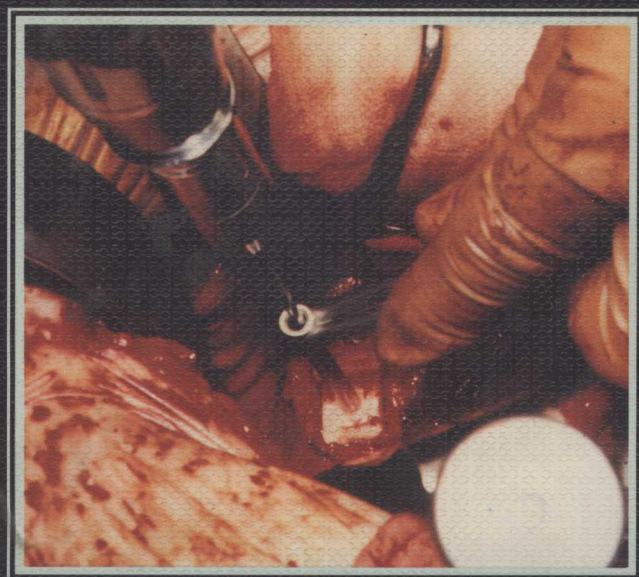
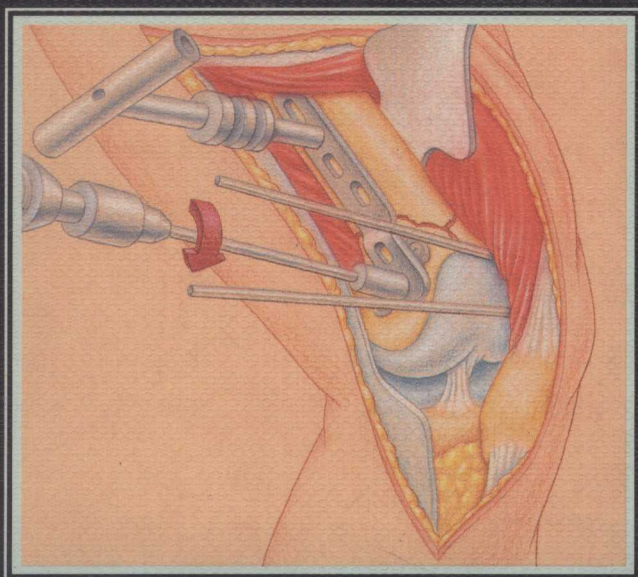


Techniques in

Fracture Fixation

*As Practiced by the
Reno Orthopaedic Clinic*



Editor

Timothy J. Bray

Foreword by Michael W. Chapman

Techniques in

Fracture Fixation

*As Practiced by the Reno Orthopaedic Clinic
Reno, Nevada*

Edited by

Timothy J. Bray, MD

Foreword by

Michael W. Chapman, MD

With illustrations by

Carol Kalafatic, Iris J. Nichols, and Carlyn Iverson

Gower Medical Publishing • New York • London



Distributed in the USA and Canada by:

Raven Press
1185 Avenue of the Americas
New York, NY 10036
USA

Distributed in Japan by:

Nankodo Company, Ltd.
42-6, Hongo 3-Chome
Bunkyo-Ku
Tokyo 113
Japan

Distributed in the rest of the world by:

Gower Medical Publishing
Middlesex House
34-42 Cleveland Street
London W1P 5FB
UK

Library of Congress Cataloging-in-Publication Data

Techniques in fracture fixation / editor, Timothy J. Bray ;
contributors, Richard W. Blakey . . . [et al.] ; foreword by
Michael Chapman.

p. cm.

Includes bibliographical references and index.

ISBN 0-397-44690-X

1. Fracture fixation. I. Bray, Timothy J., 1948-

II. Blakey, Richard W. III. Title: Fracture fixation.

[DNLM: 1. Fracture Fixation—methods. WE 175 T355]

RD103.F58T43 1992

617.1'5—dc20

DNLM/DLC

for Library of Congress 92-1520

CIP

British Library Cataloging-in-Publication Data

A catalogue record for this book is available from the British
Library.

Editor: Leah Kennedy

Art Director: Jill Feltham

Designer: Thomas Tedesco

Illustration Supervisor: Carol Kalafatic

Illustrators: Carol Kalafatic, Iris J. Nichols,
Carlyn Iverson, Ruth Soffer (inking)

Printed in Singapore by Imago Productions (FE)

Pte Ltd.

10 9 8 7 6 5 4 3 2 1

©Copyright 1993 by Gower Medical Publishing, 101 Fifth Avenue, New York, NY 10003. All rights reserved. No part of
this publication may be reproduced, stored in a retrieval system, or transmitted in any form or by any means electronic,
mechanical, photocopying, recording, or otherwise, without prior written permission of the publisher.

Techniques in

Fracture Fixation

Edited by

Timothy J. Bray, MD



Foreword by

Michael W. Chapman, MD

一九九六年十月廿一日

With Illustrations by

Carol Kohnstamm, Iris J. Nichols, and Carolyn Iverson

Gower Medical Publishing • New York • London •

DEDICATION

from the Reno Orthopaedic Clinic

This book is dedicated to the patients, families, and partners of the Reno Orthopaedic Clinic.

During the past several years, a new orthopaedic center has been established in Reno, Nevada. This center is the Reno Orthopaedic Clinic, which is a part of the University of Nevada, Reno. The clinic is a new addition to the medical community in Reno, and it is a place where patients can receive the best possible care for their orthopaedic problems.

The Reno Orthopaedic Clinic is a place where patients can receive the best possible care for their orthopaedic problems. The clinic is a new addition to the medical community in Reno, and it is a place where patients can receive the best possible care for their orthopaedic problems. The clinic is a new addition to the medical community in Reno, and it is a place where patients can receive the best possible care for their orthopaedic problems.

The Reno Orthopaedic Clinic is a place where patients can receive the best possible care for their orthopaedic problems. The clinic is a new addition to the medical community in Reno, and it is a place where patients can receive the best possible care for their orthopaedic problems. The clinic is a new addition to the medical community in Reno, and it is a place where patients can receive the best possible care for their orthopaedic problems.

The Reno Orthopaedic Clinic is a place where patients can receive the best possible care for their orthopaedic problems. The clinic is a new addition to the medical community in Reno, and it is a place where patients can receive the best possible care for their orthopaedic problems. The clinic is a new addition to the medical community in Reno, and it is a place where patients can receive the best possible care for their orthopaedic problems.

The Reno Orthopaedic Clinic is a place where patients can receive the best possible care for their orthopaedic problems. The clinic is a new addition to the medical community in Reno, and it is a place where patients can receive the best possible care for their orthopaedic problems. The clinic is a new addition to the medical community in Reno, and it is a place where patients can receive the best possible care for their orthopaedic problems.

The Reno Orthopaedic Clinic is a place where patients can receive the best possible care for their orthopaedic problems. The clinic is a new addition to the medical community in Reno, and it is a place where patients can receive the best possible care for their orthopaedic problems. The clinic is a new addition to the medical community in Reno, and it is a place where patients can receive the best possible care for their orthopaedic problems.



CONTRIBUTORS

from the Reno Orthopaedic Clinic

ORTHOPEDIC SURGEONS

James R. Herz, MD
Jack P. Sargent, MD
William A. Teipner, MD
Harold E. Halvorson, MD
Stephen D. Dow, MD
E. James Greenwald, MD
James L. Christensen, MD
Patrick S. Herz, MD
Robert J. Parlasca, MD
Lex A. Simpson, MD
Timothy J. Bray, MD
Richard W. Blakey, MD

PHYSIATRIST

E. Gary Starr, MD



PREFACE

The Reno Orthopaedic Clinic was founded by the three senior partners in 1959. The practice began in a converted, small home well away from existing hospitals. As some of our older readers may remember, it started in the days of \$5 office visits and fees of under \$100 for the complete treatment of a fractured hip.

During subsequent years, additional orthopedists were gradually added to our staff. In the course of those additions, our facility expanded. Currently, 13 partners practice in a large, modern office facility with research activities and staffing for three hospitals. A Level II Trauma Center is the mainstay of our fracture practice, requiring each staff member to be adept at handling a variety of injuries.

The Reno Orthopaedic Clinic has always insisted that each partner maintain the skills of a general orthopedist first, and a subspecialist second. Our more recent partners have all had subspecialty training in various areas and are always available for expert advice. Each partner has always attempted to maintain a sense of individuality, but with our frequent office consultations and meetings we feel we have been able to develop a cohesive group that has kept up with the current trends in our specialties.

The major goal for the Reno Orthopaedic Clinic has always been to practice quality orthopedics. The techniques that we describe in this text are not original by any means. They are procedures that have evolved from our exposure to American and European fracture surgeons as well as our continued modification and redefining of accepted practices. We prefer procedures that are workable with a minimum amount of morbidity.

Judgment and compassion are the cornerstones of good orthopedics. These, combined with sound surgical techniques, give us the best chance of good results.

We feel strongly that conservatism plays a great part in our surgical specialty, but we have not discussed that aspect of the practice in this text. We hope that the text will be helpful for residents and solo orthopedists, particularly for those practicing away from a large center. This book might give them immediate pictorial consultation when it otherwise might not be readily available.

William Teipner, MD

Associate, Reno Orthopaedic Clinic, 1959

American Board of Orthopedic Surgery, 1961

American Academy of Orthopedic Surgeons, 1964

American Orthopedic Association, 1983

FOREWORD

The reader picking up this book for the first time might ask, "Why yet another book on fracture fixation?" This excellent text justifies itself in two respects. It is the most lavishly illustrated book yet to be produced on bone fixation techniques. This is consistent with the excellent tradition of Gower Medical Publishing which has focused its efforts on works with high-quality color illustrations. The reader will enjoy the beauty, and benefit from the accuracy and realism of the many excellent surgical photographs in this text. Surgical exposures and techniques are difficult to illustrate and photograph in a way that is easily understood by the reader; this text meets this need better than any I have read before. Second, Dr. Bray and his contributors from the Reno Orthopaedic Clinic have brought to us a unique intellectual property in that this work represents the collected opinions and experience of a group of private-practice-based orthopedic surgeons with an accumulated total experience measured in hundreds of years. This text brings to our attention those surgical approaches and techniques in bone fixation that have worked best in the hands of these experienced, pragmatically minded surgeons. The techniques are based on AO-ASIF techniques and implants, which is understandable considering the background of the editor and authors who have been heavily trained in and remain contributors to the philosophies embodied in the Swiss-German approach to bone fixation. Dr. Bray and his contributors have always kept an open mind and have constantly explored other approaches to and methods for bone fixation; the best of what they have found to work is also presented.

Although the majority of their text focuses on surgical technique, each chapter has a nice introduction to the topic, considers the anatomy of the area, and presents a brief background on the fixation problem of concern, giving fracture classifications, and so on. Their story is told in atlas style rather than descriptive text. Most surgeons will appreciate this visual approach and will find each one of their pictures to be worth a thousand words.

The text is divided into ten chapters which first address fracture and fixation problems in the axial skeletal and then move on to the extremities on an anatomical basis. Chapter 6 is unique in that it addresses the overall issue of intramedullary fixation, a technique unto itself, and Chapter 10 covers nerve injuries in fracture care. Nerve injuries frequently accompany fractures and are deserving of the attention of surgeons involved in fracture fixation. This text focuses on surgical technique. For detail on pitfalls and complications the reader will need to seek out more comprehensive texts that spend less time on the details of surgical technique.

Who should read this text? This atlas of fracture fixation is an excellent practical manual of bone fixation which, because of the excellent illustrative material, will be useful to medical students to better understand the techniques involved. It is an obvious reference for residents in orthopedic surgery who seek more detailed description and illustration of surgical techniques than are available in most other textbooks. Having this text available in the library of operating rooms will be useful for operating room personnel who wish to acquaint themselves with procedures their surgeons are performing. Lastly, it is an excellent resource for mature, practicing orthopedic surgeons who want detailed description and illustration of operative procedure—a large part of their practice if they are involved in general orthopedics or trauma care. To all of these potential readers I commend this superbly illustrated textbook.

Michael W. Chapman, MD
Department of Orthopaedic Surgery
University of California, Davis

ACKNOWLEDGMENTS

Special thanks to Linda Ellenwood and Stephanie Griffith for their compulsive, timely production of professional manuscripts; Steve Young, professional photographer at Washoe Medical Center, for his extra time and effort to produce the late-night photographs of surgical techniques; Washoe Medical Center operating room personnel, for their help in providing instrumentation and implants for models; and, finally to Dr. Jeffrey Mast, for this compulsion for detail in the early development of high standards for modern fracture care in our community.

Thanks also to the people at Gower: Iris J. Nichols, Carlyn Iverson, and especially Carol Kalafatic for the beautiful operative and anatomic schematics; Eric Goldman for starting the project and Leah Kennedy for finishing it; Tom Tedesco for the pleasing design; and the former president of Gower, Abe Krieger, for his support of the book.

CONTENTS

Chapter 1

Fixation of Spinal Disorders

Introduction	1.2
Initial Diagnosis and Management	1.2
Applying the Halo and Halo Vest	1.2
The Myelogram, CT Scan, and MRI	1.4
Decision Making and Methods of Stabilizing	
Various Fracture Types	1.7
Upper Cervical Spine	1.7
C-1 Fracture and Ligamentous Instability C-1 on C-2	1.7
Odontoid Fractures	1.7
Bilateral Fracture of the Pars Interarticularis at C-2 (Hangman's Fracture)	1.13
Mid and Lower Cervical Spine	1.15
Pure Ligamentous Injury	1.15
Flexion Teardrop Fracture Dislocation	1.15
Bilateral Locked Facets	1.18
Hyperextension Injury with Multiple Laminar Fractures	1.21
Burst Fracture	1.22
Unilateral Locked Facet	1.22
Extension Rotation with Lateral Mass Fractures (Pillar Fractures)	1.22
Surgical Technique for C-1, C-2 Posterior Fusion	1.22
Anterior Approach to the Cervical Spine	1.25
Anterior Plating	1.27
Use of the Dowel Graft	1.29
Posterior Approach to the Cervical Spine	1.32
Fixation Techniques: Thoracolumbar Spine	1.35
Posterior Approaches and Fixation Techniques	1.37
Harrington Rod Instrumentation	1.39
Harrington Rods with Decompression	1.40
Harrington-Luque Technique	1.46
Luque Rod Fixation	1.47
Harrington Rods with Wisconsin or Drummond Wire Fixation	1.48
Compression Rod Techniques	1.50
Knodt Rods	1.50
Pedicule Screw Fixation	1.54
Anterior Fixation Techniques—Thoracolumbar Spine	1.59
Zielke Device	1.60
Anterior Lumbar Strut Graft Techniques	1.66
Anterior Vertebrectomy or Corpectomy	1.68
Anterior Lumbar Interbody Fusion	1.70
Conclusions	1.80

Chapter 2

Disruptions of the Pelvic Ring

Introduction	2.2
External Pelvic Fixation: "The Resuscitation Frame"	2.2
Surgical Technique	2.4
Anterior Plate Fixation of the Sacroiliac Joint	2.5

Surgical Technique	2.5
Open Reduction Internal Fixation of the Pubic Symphysis	2.7
Indications	2.7
Surgical Technique	2.7
Posterior Stabilization	2.9
General Principles	2.9
Posterior Sacroiliac Stability	2.9
Posterior Pelvic Plating	2.10
Surgical Procedure	2.10
Plate Selection and Preparation	2.10
Fixation of the Plate	2.15
Advantages and Drawbacks	2.15
Screw Fixation of Sacroiliac Disruptions	2.15
Sacroiliac Fracture Dislocations	2.18
Surgical Technique	2.19
Special Techniques	2.19
Surgical Technique	2.19
CT-Guided Percutaneous Screw Fixation of the Sacroiliac Joint	2.20
Indications	2.20
Preoperative Considerations	2.21
Surgical Procedure	2.21
Summary	2.22

Chapter 3

Fractures of the Acetabulum

Tribute	3.2
Introduction	3.2
Radiographic Evaluation of the Acetabulum	3.2
Judet Views	3.2
Tomography and 3-D Reconstruction	3.2
Classification of Acetabular Fractures	3.5
Surgical Approaches in the Treatment of Acetabular Fractures	3.12
Choice of Surgical Approaches	3.12
Preparing the Patient for Surgery	3.12
Posterior Column Pathology: Positioning, Approach, and Fixation	3.14
Patient Positioning	3.14
The Approach	3.15
Fixation of Posterior Column Pathology	3.16
Treatment of Posterior Wall Fractures	3.16
Treatment of Posterior Column Fractures	3.17
Treatment of Transverse Fractures	3.17
Treatment of T-Shaped Fractures	3.17
Prevention of Reduction Difficulties in Posterior Acetabular Surgery	3.17
Anterior Column Pathology: Positioning, Approach, and Fixation	3.19
Patient Positioning	3.19
The Approach	3.19
Fixation of Anterior Column Pathology	3.20
Treatment of Anterior Column-Anterior Wall Fractures	3.20

Treatment of Both-Column Fractures	3.20
Complications of Acetabular Surgery	3.23
Ectopic Bone Formation	3.23
Infection	3.23
Iatrogenic Nerve Palsy	3.23
Conclusion	3.24

Chapter 4 Hip Fractures

Introduction	4.2
Anatomy	4.3
Vascular Anatomy	4.3
Transcervical Fractures	4.3
Classification	4.3
Operative Techniques	4.4
Patient Preparation	4.4
Alternative Method	4.9
Displaced Femoral Neck Fractures	4.10
Timing of Femoral Neck Fracture Management	4.10
Open Reduction	4.10
Prosthetic Replacement	4.10
Operative Technique	4.11
Preoperative Planning	4.11
Positioning	4.11
Distal Reaming	4.11
Midshaft Area Preparation	4.13
Proximal Metaphyseal Preparation	4.14
Trial Reduction	4.14
Femoral Canal Preparation	4.14
Intertrochanteric Fractures	4.16
Technique	4.19
Subtrochanteric Fractures	4.22
Types of Fixation	4.22
Gamma Nail	4.24
Surgical Technique	4.24
Fixation Implants	4.29
ASIF/AO 95 Degree Blade Plate for a Transverse	
Short Oblique Subtrochanteric Fracture	4.32
Pitfalls Related to Hip Fracture Fixation	4.33
Case 1 Compression Screw Failure	4.33
Case 2 Checking Your Reductions	4.34
Case 3 Center Head, AP & Lateral	4.34
Conclusions	4.34

Chapter 5 Fractures of the Knee

Fractures of the Distal Femur	5.2
General Considerations	5.2
Operative Technique	5.5
Advanced Techniques	5.12
Wound Closure	5.13
Unicondylar Fractures	5.14
Nonunion	5.15
Evaluation	5.15
Technique	5.15
Tibial Plateau Fractures	5.17
Types	5.17
Approach	5.18
Percutaneous Fixation Techniques	5.18
Indications and Technique	5.18
Open Reduction Techniques	5.19
Surgical Technique	5.20

Incision	5.20
Possibility of Iliac Bone Graft	5.21
Reconstruction	5.21
Soft Tissue Repair	5.22
Patella Fractures	5.27
Indications for Fixation	5.27
Approach	5.27
Patient Preparation and Incisions	5.27
Fixation Technique	5.28
Postoperative Plan	5.30

Chapter 6 Intramedullary Fixation

Mechanical Considerations in Intramedullary Nailing	6.2
The Intramedullary Rod	6.2
Femur—The Classic Case	6.2
Indications and Preoperative Planning	6.2
Positioning	6.3
Draping	6.4
Surgical Technique	6.4
Incision	6.4
Reaming the Intramedullary Canal	6.6
Rod Insertion	6.6
Femur: Interlocked Nailing	6.7
Indications	6.7
Surgical Technique	6.8
Proximal Targeting	6.8
Closed, Unlocked Tibial Nailing	6.10
Indications	6.10
Preoperative Planning	6.10
Operative Set-up	6.11
Draping	6.11
Surgical Technique	6.12
Nail Insertion	6.13
Tibia: Interlocked Nailing	6.13
Indications	6.13
Surgical Technique	6.13
Rod Insertion	6.13
Postoperative Care	6.14
Advanced Techniques	6.14
Closed Femoral Osteotomy	6.14
Closed Femoral Bone Grafting	6.16

Chapter 7 Ankle Fractures

Introduction	7.2
Functional Anatomy	7.2
Surgical Anatomy	7.3
Fracture Classification	7.5
Lauge-Hansen and Danis-Weber	7.5
Treatment of Ankle Fractures	7.6
Weber Type A	7.7
Appearance	7.7
Operative Technique	7.8
Postoperative Plan	7.10
Weber Type B	7.10
Appearance	7.10
Operative Technique	7.10
Lag Screw Techniques	7.10
Antiglides	7.13
Weber Type C	7.15

Appearance	7.15
Operative Technique	7.16
Special Fracture Considerations	7.17
Delayed Open Reduction-Internal Fixation of	
Ankle Fractures	7.17
Open Reduction-Internal Fixation in the Open	
Ankle Fracture	7.17
Severe Fracture Dislocations with Bone Loss Around	
the Ankle	7.18
Treatment of Plafond Fractures	7.18
Appearance	7.18
Preoperative Planning	7.19
Surgical Technique	7.19
Prognosis and Rehabilitation	7.24
Ratings	7.24
Methods	7.24
Other Considerations	7.25
Complications	7.25
Infection	7.25
Malunions and Nonunions	7.25
Soft Tissue Damage	7.25

Chapter 8

Arm and Elbow Fixation

Introduction	8.2
Proximal Humerus Fractures	8.3
Treatment	8.3
Surgical Technique	8.3
Postoperative Protocol	8.6
Open Reduction Internal Fixation	8.6
Procedure	8.8
Nonunions and Osteotomies of the Proximal Humerus	8.11
Midshaft Humerus Fractures	8.12
Surgical Technique	8.13
Intermedullary Nailing	8.14
Surgical Technique	8.16
Supracondylar Fracture of the Elbow	8.19
Surgical Technique	8.19
Radial Head Fractures	8.21
Surgical Technique	8.21
Implant Selection	8.21
Olecranon Fractures	8.23
Surgical Techniques	8.23
Both Bone Forearm Fractures	8.26
Surgical Technique	8.26
Conclusion	8.29

Chapter 9

Fracture Fixation of the Hand and Foot

The Foot	9.2
Introduction	9.2
General Principles	9.2
Ankle (Tibial-Talar Joint)	9.2
Treatment: Posttraumatic Arthritis	9.3
Arthroscopic Ankle Debridement	9.4
Instrumentation	9.4
Technique	9.4
Ankle Arthrodesis	9.7
Subtalar Joint	9.9
Routine Subtalar Arthrodesis	9.9
Surgical Technique	9.9
Postoperatively	9.13

Acute Fractures of the Talus	9.14
Surgical Technique—Posterior Screw Placement	9.15
Reduction Tips	9.18
Acute Fracture of the Calcaneus	9.20
Surgical Technique	9.20
Midfoot Fracture Dislocations	9.25
Surgical Technique	9.25
Lis-Franc Fracture Dislocations	9.26
Fifth Metatarsal Fractures	9.26
Surgical Technique	9.26
Conclusions	9.29
The Hand	9.29
Introduction	9.29
Distal Radius	9.29
Treatment Philosophy	9.31
Surgical Techniques for Loss of Reduction	9.31
Postoperatively	9.32
External Fixation	9.33
AO/ASIF External Fixator	9.33
Open Reduction Internal Fixation	9.36
Surgical Technique	9.38
Malreduction of the Distal Radius	9.39
Surgical Technique	9.39
Metacarpal and Phalanx Fractures	9.41
Treatment Principles	9.41
Metacarpal Plate Technique	9.41
Metacarpal Neck Fractures	9.41
Treatment	9.41
Thumb Metacarpal Fractures	9.41
Surgical Technique	9.46
Phalanx Fractures	9.46
Scaphoid Fractures	9.51
Surgical Technique	9.51
Conclusions	9.53

Chapter 10

Nerve Injuries in Fracture Care

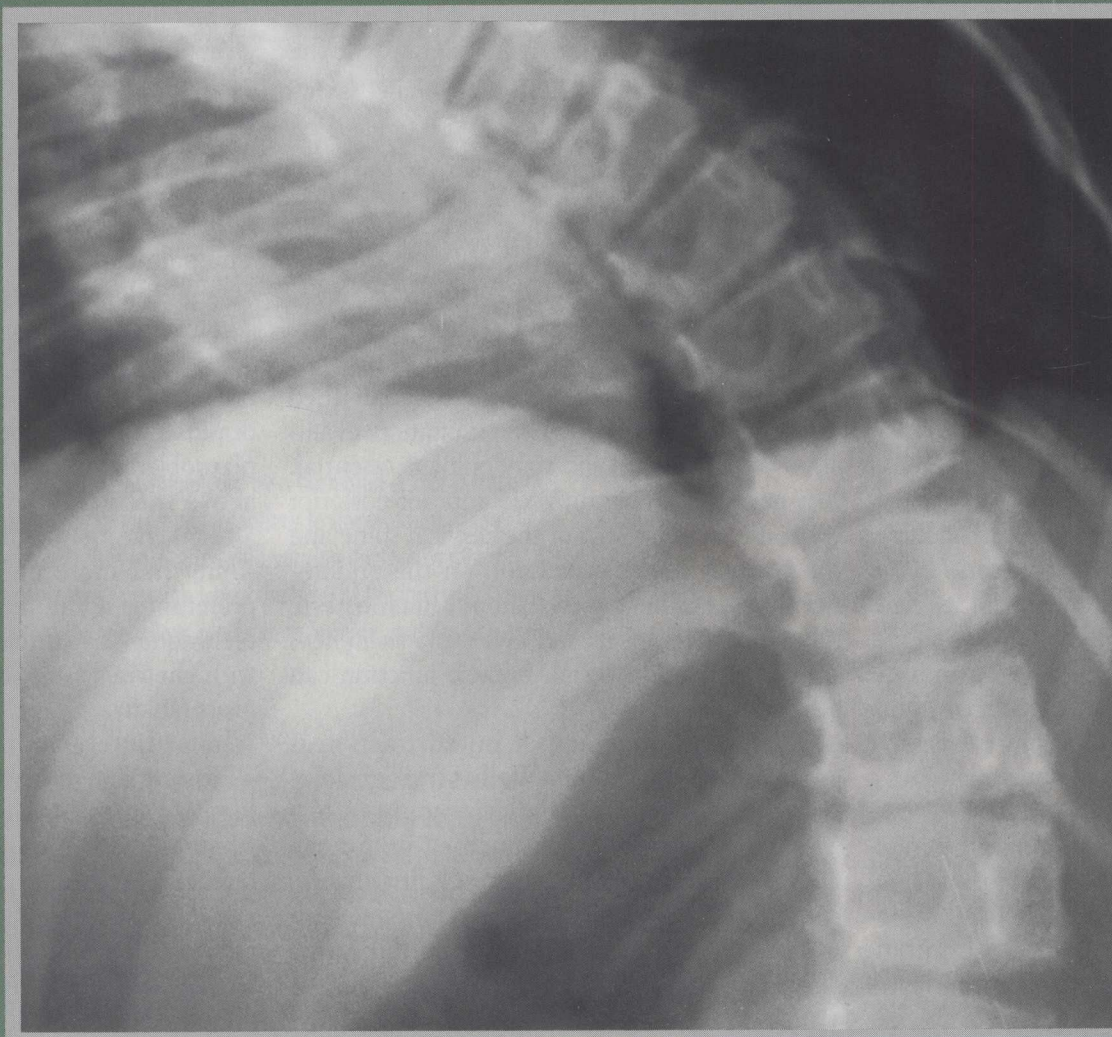
Introduction	10.2
Causalgia and Reflex Sympathetic Dystrophies	10.2
Clinical Profile	10.2
Treatment	10.2
Reflex Sympathetic Dystrophy	10.2
Gradation of Reflex Sympathetic Dystrophy	10.2
Stages of Reflex Sympathetic Dystrophy	10.3
Treatment	10.3
Peripheral Nerve Injuries	10.3
Etiology and Classification of Peripheral Nerve Injuries	10.3
Diagnosis	10.3
Electromyogram Studies	10.3
Specific Nerve Injuries	10.4
Brachial Plexus	10.4
Anatomy	10.4
Injury	10.4
Examination	10.4
Upper Brachial Plexus	10.4
Lower Brachial Plexus	10.4
Supracapsular Nerve	10.4
Anatomy	10.4
Injury	10.4
Examination	10.7
Axillary Nerve	10.7
Anatomy	10.7
Injury	10.7

Examination	10.7	Anatomy	10.15
Radial Nerve	10.7	Injury	10.15
Anatomy	10.7	Sciatic Nerve	10.16
Injury	10.7	Anatomy	10.16
Examination	10.8	Injury	10.16
Median Nerve	10.8	Examination	10.16
Anatomy	10.8	Peroneal Nerve	10.16
Injury	10.8	Anatomy	10.16
Examination	10.9	Injury	10.16
Ulnar Nerve	10.10	Examination	10.17
Anatomy	10.10	Tibial Nerve	10.17
Injury	10.10	Anatomy	10.17
Examination	10.11	Injury	10.17
Sacral Plexus	10.11	Postoperative Problems That Respond Well	
Anatomy	10.11	to Rehabilitation	10.19
Injury	10.11	Swelling and Scar Formation	10.19
Obturator Nerve	10.13	Treatment	10.19
Anatomy	10.13	Functional Fracture Bracing	10.19
Injury	10.13	Conclusions	10.19
Examination	10.13		
Femoral Nerve	10.13		
Anatomy	10.13		
Injury	10.14		
Examination	10.15		
Pudendal Nerve	10.15		

<i>Index</i>	1.6
---------------------	-----

<i>Figure Credits</i>	1.7
------------------------------	-----

FIXATION OF SPINAL DISORDERS



chapter one

ISBN 0-397-44690-X



9 780397 446902

90000

23141