

TUMORS  
of the  
MAJOR SALIVARY GLANDS

9.02-64  
63

016/14

~~T6264~~

~~A.C.T.~~

R739.87

# ATLAS OF TUMOR PATHOLOGY

Second Series  
Fascicle 10

## TUMORS OF THE MAJOR SALIVARY GLANDS

by

**A. C. THACKRAY, M. D.**

Professor of Morbid Histology  
The Bland-Sutton Institute of Pathology  
The Middlesex Hospital Medical School  
London, W1N 8AA, England

and

**R. B. LUCAS, M. D.**

Professor of Oral Pathology  
Royal Dental Hospital of London  
School of Dental Surgery  
London, WC2H 7LJ, England

Published by the  
**ARMED FORCES INSTITUTE OF PATHOLOGY**  
Washington, D. C.

Under the Auspices of  
**UNIVERSITIES ASSOCIATED FOR RESEARCH AND EDUCATION IN PATHOLOGY, INC.**  
Bethesda, Maryland  
1974

Accepted for Publication  
1974

.....  
For sale by the American Registry of Pathology  
Armed Forces Institute of Pathology  
Washington, D. C. 20306



# **ATLAS OF TUMOR PATHOLOGY**

**Sponsored and Supported by**

**AMERICAN CANCER SOCIETY  
NATIONAL CANCER INSTITUTE, NATIONAL INSTITUTES OF HEALTH  
U. S. PUBLIC HEALTH SERVICE**

**and**

**ARMED FORCES INSTITUTE OF PATHOLOGY**

**EDITOR**

**HARLAN I. FIRMINGER, M. D.**

**Professor, Department of Pathology  
University of Maryland School of Medicine  
Baltimore, Maryland 21201**

**and**

**Scientist Associate, Universities Associated for  
Research and Education in Pathology, Inc.  
9650 Rockville Pike  
Bethesda, Maryland 20014**

## **EDITORIAL ADVISORY COMMITTEE**

<b>Lauren V. Ackerman, M.D.</b>	<b>State University of New York Stony Brook, Long Island, New York</b>
<b>David G. Freiman, M.D.</b>	<b>Harvard Medical School Boston, Massachusetts</b>
<b>John K. Frost, M.D.</b>	<b>The Johns Hopkins School of Medicine Baltimore, Maryland</b>
<b>James C. Harkin, M.D.</b>	<b>Tulane University School of Medicine New Orleans, Louisiana</b>
<b>Dante G. Scarpelli, M.D.</b>	<b>University of Kansas Medical Center Kansas City, Kansas</b>
<b>Robert E. Scully, M.D.</b>	<b>The Massachusetts General Hospital Boston, Massachusetts</b>
<b>Philippe Shubik, M.D.</b>	<b>University of Nebraska College of Medicine Omaha, Nebraska</b>
<b>Harlan J. Spjut, M.D.</b>	<b>Baylor University College of Medicine Houston, Texas</b>



## EDITOR'S NOTE

The Atlas of Tumor Pathology was originated by the Committee on Pathology of the National Academy of Sciences—National Research Council in 1947. The form of the Atlas became the brainchild of the Subcommittee on Oncology and was shepherded by a succession of editors. It was supported by a long list of agencies; many of the illustrations were made by the Medical Illustration Service of the Armed Forces Institute of Pathology; the type was set by the Government Printing Office; and the final printing was made by the press at the Armed Forces Institute of Pathology. The American Registry of Pathology purchased the fascicles from the Government Printing Office and sold them at cost, plus a small handling and shipping charge. Over a period of 20 years, 15,000 copies each of 40 fascicles were produced. They provided a system of nomenclature and set standards for histologic diagnosis which received worldwide acclaim. Private contributions by almost 600 pathologists helped to finance the compilation of an index by The Williams & Wilkins Company to complete the original Atlas.

Following the preparation of the final fascicle of the first Atlas, the National Academy of Sciences—National Research Council handed over the task of further pursuit of the project to Universities Associated for Research and Education in Pathology, Inc. Grant support for a second series was generously made available by both the National Cancer Institute and the American Cancer Society. The Armed Forces Institute of Pathology has expanded and improved its press facilities to provide for a more rapid and efficient production of the new series. A new Editor and Editorial Advisory Committee were appointed, and the solicitation and preparation of manuscripts continues.

This second series of the Atlas of Tumor Pathology is not intended as a second edition of the first Atlas and, in general, there will be variation in authorship. The basic purpose remains unchanged in providing an Atlas setting standards of diagnosis and terminology. Throughout the rest of this new series, the term chosen for the World Health Organization's series "International Histological Classification of Tumours" (when available) is shown by an asterisk if it corresponds to the authors' choice, or as the first synonym in bold print if it differs from the authors' heading. Hematoxylin and eosin stained sections still represent the keystone of histologic diagnosis; therefore, most of the photomicrographs will be of sections stained by this technic, and only sections prepared by other technics will be specifically designated in the legends. It is hoped that in many of the new series a broader perspective of tumors may be offered by the inclusion of special stains, histochemical illustrations, electron micrographs, data on biologic behavior, and other pertinent information for better understanding of the disease.

The format of the new series is changed in order to allow better correlation of the illustrations with the text, and a more substantial cover is provided. An index will be included in each fascicle.

It is the hope of the Editor, the Editorial Advisory Committee, and the Sponsors that these changes will be welcomed by the readers. Constructive criticisms and suggestions will be appreciated.

Harlan I. Firminger, M. D.



## PREFACE

Tumors of the salivary glands present a number of problems in histologic diagnosis, nomenclature, and classification. It has been our endeavor, in accordance with the general concept and aims of the fascicles, to comment on and, we hope, elucidate some of these problems in the light of our personal experience. In doing so, we are very conscious of the debt we owe to the authors of the first series of this fascicle. Foote and Frazell's classic work must remain as the foundation on which many others, not least ourselves, have built, and the nomenclature and classification that they collated and set forth in 1954 has very largely stood the test of time and practical usage throughout the world.

In recent years, the World Health Organization (WHO) has sponsored the publication of systems of nomenclature and classification for tumors in different tissues and organs. Groups of pathologists from various parts of the world have been involved in these projects, finally reaching agreed classifications after adjusting their initial differences by discussion and mutual concession. Recently, the "Histological Typing of Salivary Gland Tumours" has been published. Here again, those who had disapproved of some detail or other of the proposals, eventually waived their objections in consideration of the undoubted advantages of a common basis for international comparison of incidence figures and studies of the effectiveness of methods of treatment for various neoplasms. The WHO scheme is used here, and it is our sincere hope that it will commend itself to readers of this fascicle.

In the descriptive text of the fascicle, we have incorporated those advances of the past 20 years that are the most useful and of practical interest to the diagnostic histopathologist. There has been an enormous volume of investigative work on tumors of the salivary tissues during this period, practically all of considerable interest to pathologists. At present, however, much lies outside the immediate field of diagnostic histopathology and is, therefore, not discussed in this fascicle other than by selected references to the literature. For example, fine structure studies have now been made on most types of salivary gland tumors and the conclusions drawn will be incorporated in our account where appropriate, with reference to the relevant sources. However, with a few exceptions, the reproduction of isolated electron micrographs is of limited value and space does not permit anything like a comprehensive coverage. We have elected, therefore, to give preference to illustrations from light microscopy which have more immediate interest to the diagnostic pathologist. Similarly, much histochemical investigation of salivary gland tumors has been carried out in recent years; here again, we have concentrated on reporting those results that have an immediate bearing on the problems of practical diagnosis rather than attempting to cover a large and rapidly expanding field.

Some appropriate preliminary remarks may be useful before we embark on the systematic descriptions of the various types of tumors, and we have, therefore, given a brief account of the normal structure of the salivary glands as well as the changes resulting from inflammatory and obstructive conditions. Awareness of such features is an essential prerequisite for accurate diagnosis, but these short accounts are little more than summaries that may be convenient for the reader of this fascicle. They make no pretense at being full accounts, but are to be regarded merely as reminders.

A. C. Thackray, M. D.  
R. B. Lucas, M. D.

## ACKNOWLEDGMENTS

It is a pleasure to express our gratitude to the many pathologists and clinicians who have helped in the production of this fascicle by their generous provision of material for illustrative and other purposes, and for much valuable and stimulating discussion. As pathologists, we have relied heavily on our surgical colleagues of the Middlesex Hospital and the Royal Dental Hospital for the clinical aspects of this presentation, and for supplying case notes and photographs. We would especially thank Mr. David Patey, F.R.C.S. for many discussions and much helpful guidance on various aspects of diagnosis and treatment, based on his wide experience of salivary gland surgery.

The great majority of the illustrations have been prepared from the collected material of the Middlesex Hospital and the Royal Dental Hospital, and from the collection of the WHO International Reference Centre for Salivary Gland Tumours. For the others, we are indebted to many individual colleagues, including Dr. J. Bradley Arthaud, Washington University School of Medicine, St. Louis, Missouri; Prof. B. Cohen, Royal College of Surgeons, London, England; Dr. K. A. Fleming of the Royal Infirmary, Glasgow, Scotland; Dr. H. J. Harris, Stoke Mandeville Hospital, Aylesbury, England; Dr. D. Lovell, Central Middlesex Hospital, London, England; Dr. W. H. Mathews, Emory University, Atlanta, Georgia; Dr. K. R. Ray, Royal Berkshire Hospital, Reading, England; Prof. G. Seifert, University of Hamburg, Germany; Dr. L. Sikorowa, Oncological Institute, Warsaw, Poland; Prof. H. Spencer, St. Thomas's Hospital, London, England; Dr. A. G. Stansfeld, St. Bartholomew's Hospital, London, England; Dr. A. C. Templeton, University of Minnesota, Minneapolis, Minnesota; and Dr. T. B. Teoh, Government Institute of Pathology, Hong Kong.

For the electron micrographs we are grateful to Dr. Philip S. Feldman, Emory University, Atlanta, Georgia; Prof. I. Friedmann, Institute of Laryngology & Otology, University of London, England; and Dr. R. A. Erlandson, New York, New York.

We must also record our grateful thanks to our secretarial and technical staffs, who have so cheerfully borne a heavy burden of preparatory work. In particular, Miss Eileen Moss made many of the microscopic preparations and Mr. John Mercer assisted with some of the illustrative work.

Last, but by no means least, it is with great pleasure that we record our thanks to Dr. Harlan Firminger and his editorial staff for their unfailing cordiality and inexhaustible patience.

Permission to use copyrighted illustrations has been granted by:

American Medical Association:

Arch. Pathol. 93:130-140, 1972. For our figure 96.

A. C. Thackray, M. D.

R. B. Lucas, M. D.

# TUMORS OF THE MAJOR SALIVARY GLANDS

## Contents

	Page No.
Introduction .....	1
Development of the Salivary Glands .....	1
Intraparotid Lymph Nodes and Ectopic Salivary Tissue .....	1
Normal Structure .....	2
Oncocytes .....	5
Sebaceous Glands .....	5
Metaplasia .....	6
Salivary Secretion .....	7
Effect of Obstruction .....	7
Regeneration .....	9
Crystalloids .....	9
Nomenclature and Classification .....	11
Incidence .....	12
The Role of Biopsy in Diagnosis and Classification .....	15
Adenomas .....	16
Pleomorphic Adenoma (Mixed Tumor) .....	16
Recurrent Pleomorphic Adenoma .....	35
Monomorphic Adenomas .....	40
Adenolymphoma .....	40
Oxyphilic Adenoma .....	56
Other Types of Adenoma .....	59
Tubular Adenoma .....	62
Clear Cell Adenoma .....	62
Basal Cell Adenoma .....	64
Trabecular Adenoma .....	64
Sebaceous Adenoma and Sebaceous Lymphadenoma .....	66
Mucoepidermoid Tumor .....	69
Acinic Cell Tumor .....	81
Carcinomas .....	91
Adenoid Cystic Carcinoma .....	91
Adenocarcinoma, Epidermoid Carcinoma, and Undifferentiated Carcinoma ....	100
Adenocarcinoma .....	101
Epidermoid Carcinoma .....	103
Undifferentiated Carcinoma .....	104

	Page No.
Carcinoma in Pleomorphic Adenoma .....	107
Connective Tissue Tumors and Other Primary Tumors .....	119
Metastatic Tumors in the Salivary Glands .....	123
Salivary Gland Tumors in Children .....	125
Other Tumors and Tumor-like Conditions .....	127
Benign Lymphoepithelial Lesion .....	127
Malignant Lymphoepithelial Lesion .....	130
Sialosis .....	133
Oncocytosis .....	134
Cysts .....	135
Other Nonneoplastic Enlargements .....	135
Index .....	137





# TUMORS OF THE MAJOR SALIVARY GLANDS

## INTRODUCTION

In this preliminary chapter, after a brief summary of the development and structure of the salivary glands, the emphasis will be on those histologic features, both normal variants and those resulting from disease, that are significant in connection with the descriptions of tumors which follow.

There are two categories of salivary gland, major and minor. The major salivary glands comprise the paired parotid, submandibular, and sublingual glands. The minor salivary glands, large in number although individually small in size, are situated in the palate, tongue, lips, cheek, and floor of the mouth. They are subject to many of the same tumor types that are seen in the major salivary glands, but are dealt with in other fascicles; we are concerned here only with the major salivary glands.

The composition of the saliva produced by the three major salivary glands varies.

\* Sublingual gland saliva is mainly mucus, parotid saliva has the consistency of serum, and submandibular saliva is of intermediate character. Correspondingly, the three glands show differences in the microscopic structure of their secretory units.

## DEVELOPMENT OF THE SALIVARY GLANDS

The salivary glands develop from ingrowths of the embryonic oral epithelium (Orban). The epithelial buds that form the parotid and submandibular glands appear during the sixth week of embryonic life,

and those for the sublingual glands appear during the seventh to eighth week. The epithelial buds enlarge and form branching structures which will become the future ducts. At first solid, the branches become hollowed out and develop lumina, and the terminal portions then differentiate to form the secretory elements.

The parotid gland primordium is the first to appear, opposite each area which will ultimately be occupied by the maxillary second molar tooth; from here the epithelial bud grows toward the region of the ear, finally forming the ramifying branches of the duct system and the secretory cells themselves. The proximal portion of the primordium remains as a simple tubular structure, forming the parotid duct. A complete capsule for the gland organizes from the mesenchyme, and septa and stroma are also derived from this source. The primordial epithelial bud for the submandibular gland appears in the region of the future sublingual sulcus, as does that for the sublingual gland, and the duct systems and secretory cells develop in the same way as the parotid gland. A capsule is formed from the mesenchyme for the submandibular gland, but there is no definite capsule for the sublingual gland.

## INTRAPAROTID LYMPH NODES AND ECTOPIC SALIVARY TISSUE

Small lymph nodes are normally found within the confines of the parotid gland, usually near its surface, but not in the sub-

mandibular or sublingual glands. Approximately 5 to 10 of these nodes are usually present, having salivary ducts and often some acini in their medullary regions; otherwise, they resemble normal lymph nodes (fig. 1). The proportions of lymphoid and salivary tissue vary; lymphoid tissue may sometimes appear as no more than a shell surrounding a parotid lobule of normal size. Lymph nodes in the upper part of the neck near, but distinctly separated from the parotid gland may similarly contain salivary glandular tissue in their medullary areas (fig. 2).

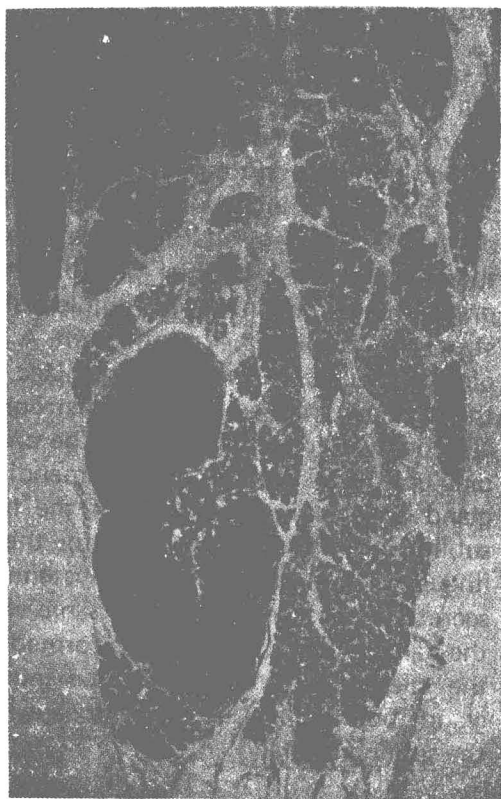

Figure 1

**LYMPH NODE IN PAROTID GLAND\***

One of several lymph nodes incorporated in its substance is seen in this cross section of the lower pole of a parotid gland. There is mild chronic parotitis and the node is hyperplastic. X6.

\*All illustrations are from the parotid gland unless otherwise indicated.

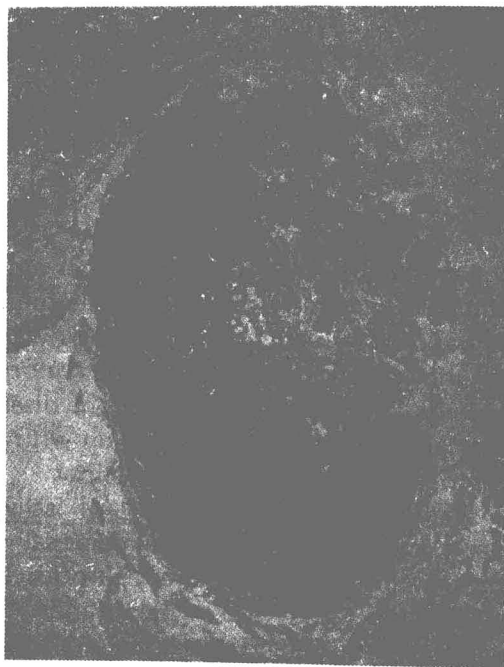

Figure 2

**LYMPH NODE CONTAINING SALIVARY TISSUE**

This cervical lymph node found near the lower pole of the parotid gland reveals salivary tissue in its medulla. X20.

In addition to salivary tissue included in the upper cervical lymph nodes, ectopic salivary tissue has been reported from a number of other locations in the head and neck, mainly in the vicinity of a line running from the ear by way of the parathyroids to the inner end of the clavicle. This distribution suggests some association with the branchial apparatus, more particularly the precervical sinus (Youngs and Scofield). The salivary tissue above the inner end of the clavicle occasionally forms a palpable swelling which discharges saliva through a duct onto the skin surface.

**NORMAL STRUCTURE**

The major salivary glands consist of numerous discrete polygonal lobules separated from one another by loose areolar

tissue within which the larger ducts are situated (Copenhaver et al.). Each lobule consists of many acini and their draining duct systems. Individual parotid acini consist of compact, rounded or ovoid groups of epithelial cells with their cytoplasm packed with basophilic zymogen granules, sometimes so densely that the nucleus is obscured. The acini have a central lumen, so small as to be scarcely visible by light microscopy, through which the secretion drains into the narrow intercalated ducts which are lined by flattened or cubical cells (fig. 3). These converge, join with others, and lead into the larger striated ducts

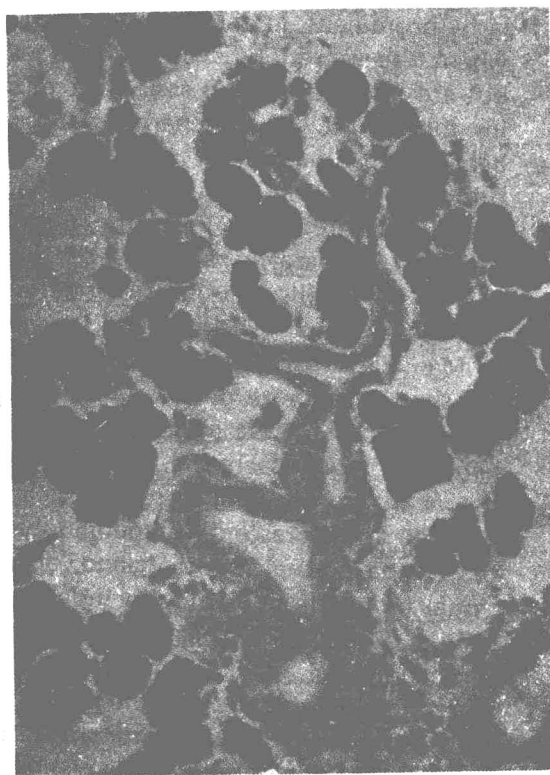


Figure 3

## INTERCALATED AND STRIATED DUCTS

Intercalated ducts lined by cubical epithelium are shown uniting and running into a striated duct at the lower end of the field. The acinar cells are packed with deeply staining granules obscuring the nuclei so that the acini appear as solid black, lobulated structures. X250.

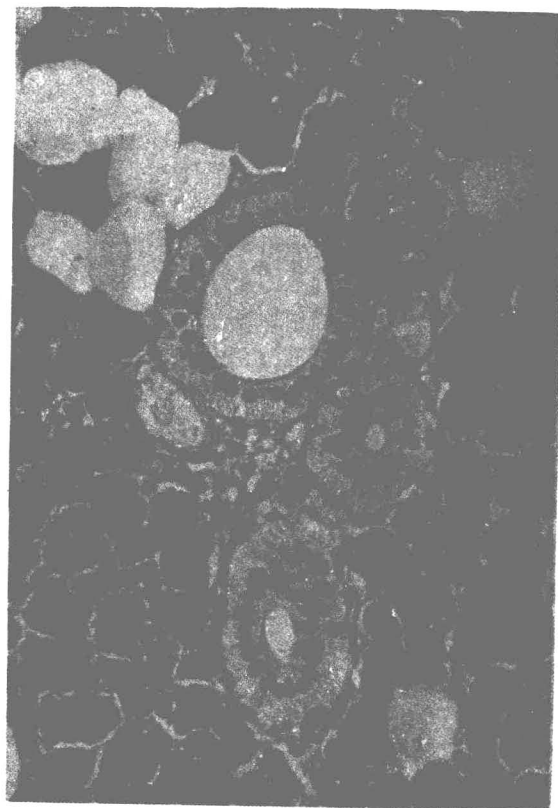


Figure 4

## STRIATED DUCTS OF PAROTID GLAND

At the center of the field, there are three cross-sectioned striated ducts. Note the radial striations in the cytoplasm of the tall, eosinophilic columnar, secretory cells, and the occasional flattened myoepithelial cell nuclei at their bases. X300.

whose tall, eosinophilic, columnar lining cells have striking radial striations in their cytoplasm (fig. 4). Finally, the striated ducts lead into excretory ducts (fig. 5). These are lined initially by pseudostratified columnar epithelium that becomes squamous as it approaches the terminal portion of the duct. The number and nature of their organelles clearly indicate that the epithelial cells lining the ducts are metabolically active, concentrating the saliva and modifying its composition, and adding to it various substances. The concentration of iodides, for example, is more than 20

times higher in saliva than in plasma, due to the activity of the cells of the striated ducts.



Figure 5

**INTERLOBULAR DUCT WITH PSEUDOSTRATIFIED COLUMNAR EPITHELIUM**

This medium-sized interlobular duct is cut in longitudinal section to illustrate its relatively simple pseudostratified low columnar epithelium. X250.

Myoepithelial cells form an outer layer to the acini and ducts. These cells by virtue of their contractility, are believed to assist in the expression of secretion from the secretory cells and its progress along the ducts. They lie directly on the basement membrane deep to the secretory cells and apparently play a part in its formation. The myoepithelial cells of the acini are flattened and stellate, their radiating cytoplasmic processes forming a basket-like network embracing the secretory cells, they are thus sometimes called basket cells. They are very inconspicuous in routine hematoxylin and eosin sections although the deeply staining and flattened nucleus can usually be recognized. However, phos-

photungstic acid hematoxylin or Heidenhain's hematoxylin more readily demonstrate the cytoplasm (Mylius). Histochemical methods may also aid in identification of the cells (Shear). Electron microscopic and immunochemical methods may also be useful. Electron microscopy demonstrates characteristic myofibrils and focal densities similar to those seen in smooth muscle cells (Ellis; Tandler). Antisera to actomyosin and myosin prepared from human colon and uterus can be used to demonstrate myoepithelial cells by immunofluorescence technics (Archer et al.). These myoepithelial cells are found in many glands of the body; they are particularly prominent in the ceruminous glands where the secretion is difficult to expel, but are also present and easily recognizable in the breast. Their characteristics and behavior in a variety of organs have been fully reviewed by Hamperl, who suggests they be called myoethelia. Although inconspicuous in paraffin sections of salivary glands, these cells play a major role in salivary gland tumors (Hübner et al.).

Many acini of the submandibular gland are similar to those of the parotid, but in some the cells of the intercalated ducts are large and mucus-secreting and extend into the acini, displacing the serous cells outward to form crescents or demilunes (fig. 6). In the normal parotid gland, an occasional group of acini may include mucous cells and appear identical to one of these submandibular acini.\* Very rarely, such areas are so numerous that the parotid may be histologically almost indistinguishable from the submandibular salivary gland. It must be remembered that the two glands come close together at one point, separated only by a layer of fascia; consequently, the surgeon may occasionally have some question as to the gland of origin of the tumor.

The sublingual gland acini are predominantly mucous.

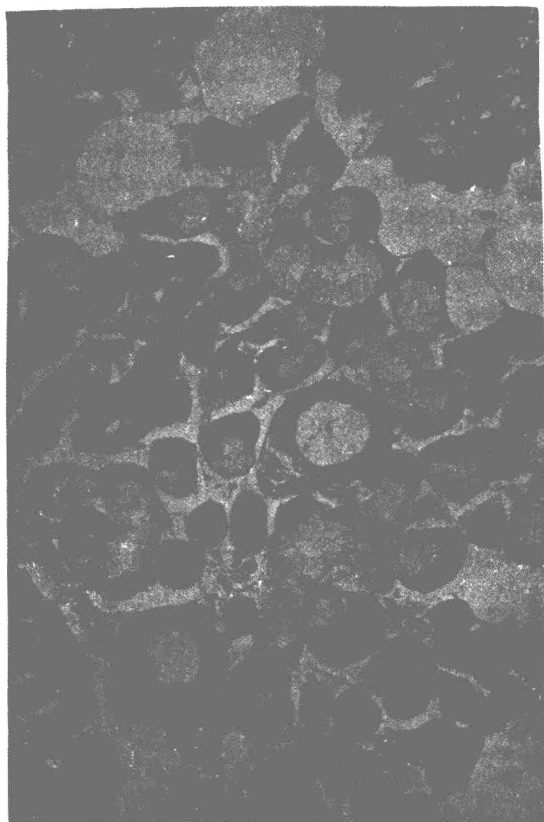


Figure 6

#### NORMAL SUBMANDIBULAR GLAND

Part of a lobule of a normal submandibular gland illustrates that a few of the acini are serous, but the majority are composed of mucous goblet cells with the serous cells displaced outward as demilunes. X160.

#### Oncocytes

Oncocytes are parenchymal cells that have undergone a peculiar change characterized by enlargement of the cell with eosinophilic granularity of the cytoplasm and striking electron microscopic appearances. They may be identified in many glands throughout the body after middle age and increase in frequency with advancing years (Hamperl). In the salivary glands, the duct epithelial cells most often undergo

this change, but groups of acini may also lose their zymogen granules and become swollen and eosinophilic (fig. 7).




Figure 7

#### ONCOCYTIC PAROTID ACINAR CELLS

The secretory cells of a group of acini (upper right) have become transformed into oncocytes; the eosinophilic cytoplasm contrasts with the basophil granulation of the normal acinar cells in the rest of the field. Adenolymphoma was present elsewhere in this parotid gland from a 77 year old man. X175.

#### Sebaceous Glands

Sebaceous glands, unassociated with hair follicles, are sometimes found in the mucosa of the cheek along a line between the angle of the mouth and the opening of Stensen's duct. The presence of occasional typical sebaceous glands in the parotid gland (fig. 8) has often been reported (Hartz; Rawson and Horn). It was concluded from an examination of a series of parotid glands by serial section that sebaceous glands are common and, that it is



exceptional to find a gland without any sebaceous glands present (Patey and Thackray). However, they vary greatly in number. In some parotid glands, one or more sebaceous glands may be found in the majority of sections taken at random; in other cases, only one or two may appear in the whole gland. In a serial section study of a child's parotid gland that contained literally hundreds of sebaceous elements, they could be seen to vary from a group of fatty duct epithelial cells to fully formed sebaceous glands, usually situated near the junction of intercalated and striated ducts. The glands appear as diverticula to the ducts into which they shed groups of fatty cells that are carried away in the saliva.

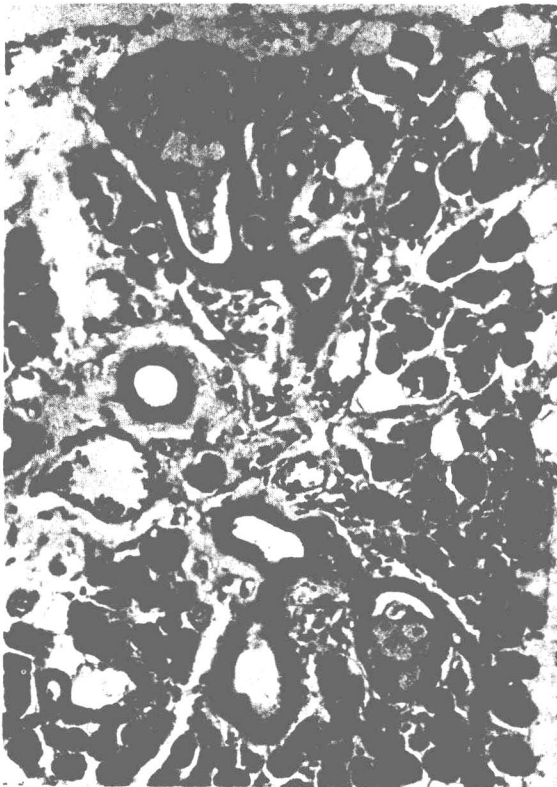


Figure 8

**SEBACEOUS GLANDS IN NORMAL PAROTID GLAND**

The two sebaceous glands seen in this field are from a normal parotid salivary gland. X160.

Often squamous metaplasia of the duct is present close to the gland. Similar sebaceous glands do occur, but rarely, in the submandibular salivary gland.

**Metaplasia**

The occasional presence of mucous acini in the parotid gland has been mentioned. The larger ducts may normally contain a few isolated mucous goblet cells, but they may become numerous in chronic inflammation of the gland (fig. 9). If there is an element of obstruction, the ducts may become distended with mucus, or even rupture with its extravasation. When there is abundant production of mucus, ciliated lining cells may be a prominent feature. The larger salivary ducts may also show squamous metaplasia in chronic inflammation, particularly in the presence of calculi. A

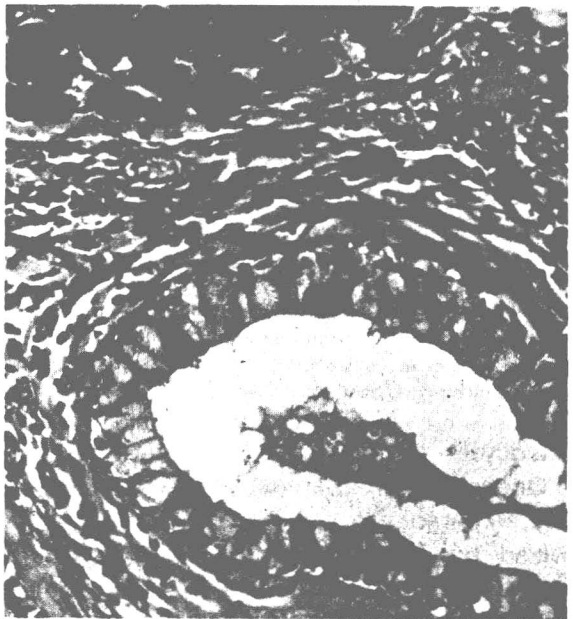


Figure 9

**GOBLET CELLS IN PAROTID DUCT  
(CHRONIC PAROTITIS)**

This photomicrograph of an interlobular duct from a patient with chronic parotitis shows numerous mucous goblet cells in the thickened duct lining. There is interstitial chronic inflammatory cell infiltration. X250.



similar change is rarely seen in the smaller ducts (fig. 10).

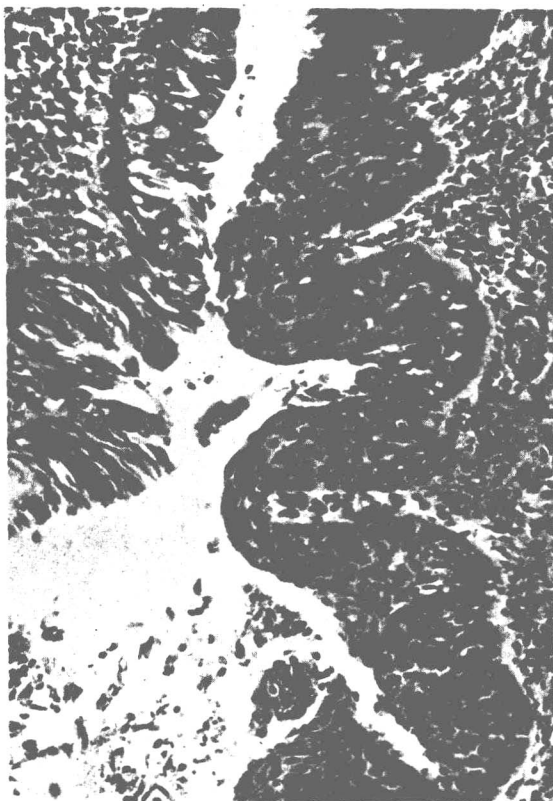


Figure 10  
SQUAMOUS METAPLASIA  
OF SUBMANDIBULAR GLAND

This major duct from the submandibular gland shows squamous metaplasia. There is chronic inflammatory infiltration in the subepithelial tissue. X160.

### Salivary Secretion

The normal adult secretes between 1 and 1.5 liters of saliva per day. The total protein content, consisting mainly of mucoids, is about 0.3 percent. Other organic substances of lower molecular weight are also present. Inorganic constituents account for about 0.2 percent; the major ones are phosphate and carbonate which are also the principal buffering agents. Investigations such as estimation of the volume and composition of the saliva, sia-


扫描

lography, and radioisotope scanning can be of considerable diagnostic help, particularly in nonneoplastic salivary gland enlargements (Maynard; Banks). Where neoplasms are concerned, investigative studies have not developed sufficiently to provide the diagnostic pathologist with the same ancillary aid that he obtains, for example, from radiograms as an adjunct to his microscopic study of bone tumors. However, among a few positive findings concerning neoplasms is the selective concentration of pertechnetate by adenolymphomas.

### EFFECT OF OBSTRUCTION

As already noted, the normal parotid acinus is a compact spherical or ovoid cluster of secretory cells with a central lumen which is scarcely visible in ordinary sections. If the duct system is artificially distended by injection of excessive contrast medium in sialography while the patient is alive, or by injection of fixative into the duct system after death, the tubules dilate and the acini distend, the appearances then being similar to those of some acinic cell tumors. The lumens of the acini also become visible, at first from distension and later from shrinkage and atrophy of the acinic cells, if an interlobular duct is obstructed by a calculus, pressure of a tumor, or by other means. The acinic cells gradually lose their granules and resemble intercalated duct epithelium before finally disappearing (fig. 11). The cells lose their zymogen granules from the periphery first so that at one stage they look like duct cells with a narrow zone of granules adjacent to the lumen. The atrophied acini are replaced by adipose tissue and only the atrophic ducts remain, presenting an appearance that should not be mistaken for a neoplasm (fig. 12). When there has been

partial obstruction of a main duct, the myoepithelial cells may become unusually prominent not only because the cells themselves are enlarged but also because hyalinization of the periductal connective tissue may occur (fig. 13).



**Figure 11**


**OBSTRUCTIVE DILATATION OF DUCT AND ACINI**

This portion of a lobule reveals dilatation of its intercalated duct and acini as a result of chronic parotitis with duct obstruction. The acinar cells are losing their granules and shrinking. X300.

**Figure 13**

**CHRONIC PAROTITIS**


These interlobular ducts are from a patient with chronic parotitis with partial obstruction of the main duct. There are mucous goblet cells present and many of the epithelial cells are ciliated. The myoepithelial layer is prominent. The hyalin basement membrane is thickened. X250.



**Figure 12**

**POSTOBSTRUCTIVE ATROPHY**

Normal parotid tissue is shown outlining an atrophic lobule which has been largely replaced by adipose tissue. The intralobular duct was blocked proximally by a microcalculus. X35.



**Figure 13**

## REGENERATION

Histologic examination of the surrounding area in the salivary gland a few weeks after partial parotidectomy may reveal signs of regeneration. Masses of proliferating small, darkly staining, epithelial cells are arranged in budding and branching solid columns with club-shaped extremities, appearances reminiscent of basal cell adenoma (figs. 14, 15).

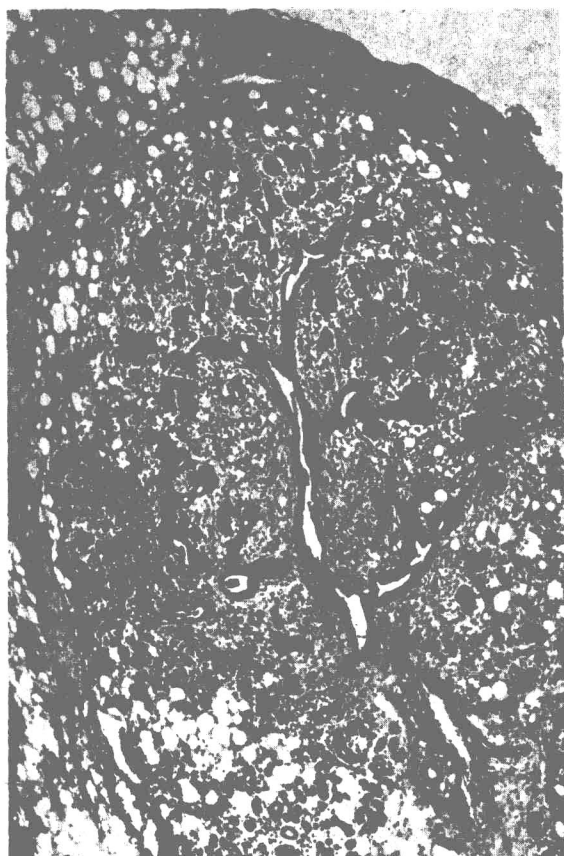


Figure 14

LOBULE REGENERATION OF PAROTID GLAND  
(Figures 14 and 15 from same case)

The free edge above is the line of incision of a partial parotidectomy which had been performed a few weeks previously. Regeneration is occurring in a damaged lobule, the intact part of which is seen toward the bottom of the field. X40.

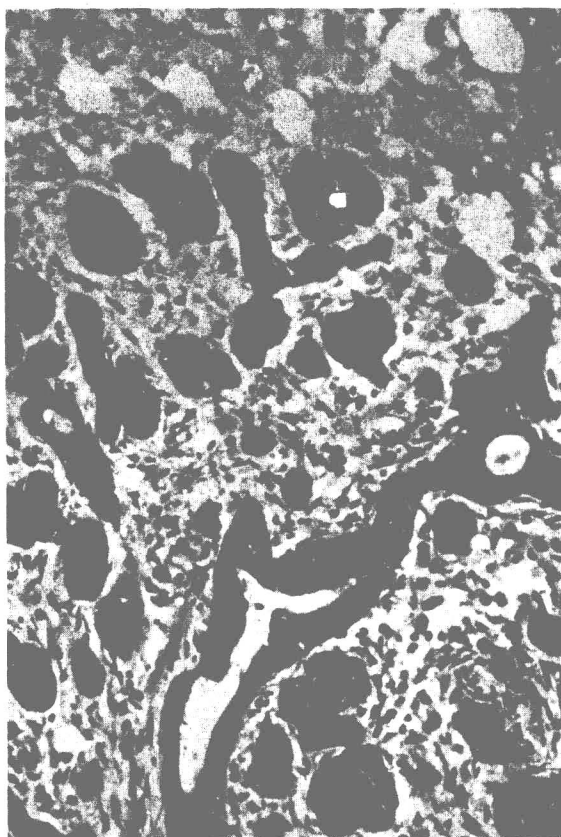


Figure 15

LOBULE REGENERATION OF PAROTID GLAND  
(Figures 14 and 15 from same case)

Higher magnification of a portion of figure 14 shows solid buds and columns of epithelial cells growing out into fibro-fatty tissue from the duct of the damaged lobule. X160.

## CRYSTALLOIDS

An occasional duct containing crystalline structures, usually referred to as crystalloids, will be found in about 5 percent of routine postmortem sections of the parotid glands. These crystalloids are eosinophilic and variable in shape and size, forming needles, rods, and plates. Their presence may evoke an inflammatory reaction with polymorphonuclear leukocytes around