

CARD

MODERN TRENDS IN GASTRO-ENT

MODERN TRENDS
IN
GASTRO-ENTEROLOGY
3

Edited by

W. I. CARD, M.D., F.R.C.P.(Ed.), F.R.C.P.(Lond.)

*Physician-in-Charge, Gastro-intestinal Unit, Western
General Hospital, Edinburgh; Reader in the Depart-
ment of Medicine, University of Edinburgh*

LONDON
BUTTERWORTHS

1961

©

The several Contributors listed on pages v-vii
1961

*Made and printed in Great Britain by
William Clowes and Sons, Limited, London and Beccles*

INTRODUCTION

It is curious that in Great Britain the alimentary tract has taken so long to be considered even a proper subject for specialized study, and as a result gastro-enterology has become the Cinderella of the specialties. Partly for this reason it is one of the most backward, but the most backward subject, as Sir Thomas Lewis reminded us, is the one ripe for the most rapid advance. One reason for the lack of advancement has been the poverty of suitable investigative techniques, but this is being remedied, in particular by new developments in instrumentation. In a volume of the *Modern Trends* series we have to note not only new techniques, such as the telemetering capsule and new ideas such as those on bilirubin metabolism, but also to review existing knowledge in a particular field in order to speculate and plan the next step forward; both these aspects are covered in the following chapters.

Gastro-enterology is no narrow specialty but one which embraces a wide field of interest of concern to both physician and surgeon. The close collaboration now essential for effective clinical management is rapidly diminishing any difference in approach between physician and surgeon, and surgery is now seen as a highly specialized form of therapy. The choice of subjects tries to reflect this catholicity of interest.

Many years ago anatomy stood almost alone on the frontier of medical science, and it is possible in the next decades that the study will once more become one of the growing points of medicine. The ultimate aim is to visualize the molecular arrangement which is at present a logical structure in the thinking of the biochemist and physicist. Professor Wyburn and Dr. Hally describe the first steps towards this goal in their account of electron microscopy of the alimentary tract, an instrument that has opened up a new dimension of thought.

In the aetiology of disease it has been thought valuable information could be gleaned from a study of the same disease in different countries or in different parts of the same country: such study has now been given the descriptive word of geomedicine. Though it is clear that at present many statistical data are inadequate, and frequently unreliable, the method as a whole is promising and the introduction of reliable morbidity statistics in this and other

countries will make it a most valuable mode of investigation. Dr. Watkinson provides a critical review of the present position of the geographical pathology of peptic ulcer. Another disease with a global incidence that should be susceptible to this kind of attack is nutritional disease of the liver. Dr. Waterlow and Professor Bras critically review the evidence for various forms of liver disease being caused by malnutrition, and suggest the lines for future inquiry. One of the ways in which geographical variations in incidence of disease might conceivably occur lies in the inheritance of blood groups, and the association of certain blood groups with various forms of gastro-intestinal disease is covered in the chapter by Professor Ian Aird, one of the pioneers in this field. Though certain associations seem undoubted, the explanation of their mode of action remains an intriguing mystery.

Though microbiology has not completely exhausted the goldmine of nineteenth-century bacteriology, the law of diminishing returns has set in, and in the development of virology we expect the most striking advances in the future. The aetiology of many alimentary diseases is still uncertain and an infective origin cannot always be excluded. Dr. Grist, in summarizing our general knowledge of this subject, and in particular of those viruses known to cause alimentary disease, focuses attention on a subject of growing importance to any thoughtful gastro-enterologist.

The van den Bergh reaction has for a generation been one of the classic pillars in the understanding of jaundice, but its foundations have always been shaky and have now been completely undermined. Dr. Butt and his colleagues give an account of the newer knowledge of bilirubin metabolism which may well represent one of the great advances in our knowledge of liver physiology. Though much is now clear, much still remains unanswered, and a better understanding of the mechanisms of jaundice will undoubtedly be built on this new knowledge. One of the less accessible parts of the alimentary tract is the small intestine, and diagnostic radiology, which can achieve results of almost mathematical accuracy in other parts of the tract, is here acknowledged to be very defective. It is, therefore, useful to have a review by Drs. Cummack and Copland of what can at present be achieved, if only to provide a springboard for a new advance. One modern technique which radiology has increasingly used in recent years is the image intensifier, a technique which makes cinefluorography possible without excessive radiation. When cinefluorography is combined with accurate manometry of the gut, it is not difficult to see how new knowledge may

INTRODUCTION

accrue. Dr. Clinton Texter has applied this technique to the lower oesophageal sphincter whose mechanism has proved irritatingly difficult to analyse and elucidate. A further research technique that shows considerable promise is recording outside the body changes transmitted as radio waves from a transducer which has been swallowed and is sensitive to pressure changes within the alimentary tract. Dr. Farrar, one of the pioneers, gives us a review of some of the technical possibilities. Others remain to be explored, and such a transmitter could be made sensitive to other stimuli besides changes of pressure.

Drs. French and Sircus describe the new and striking syndrome, named after Zollinger and Ellison, of intractable peptic ulceration associated with islet-cell tumours of the pancreas. Though this is a rarity it is a very exciting rarity, and its importance lies in the possibility that the hormonal substance which has now been extracted from a tumour plays a part in the normal mechanism for gastric secretion. It is possible for this to be one of those gastrointestinal hormones which control so much of alimentary tract function and of which we shall hear increasingly during the next decade.

Four chapters of this book deal with some aspects of therapy. We are apt to think that the combination of modern surgery and chemotherapy is steadily reducing the dangers of peritonitis, and it may come as something of a shock to find the mortality from peritonitis in Great Britain has risen, after showing a dramatic reduction in the period up to 1949. This finding gives no grounds for complacency, and Mr. Menzies discusses fully the management he advises. Though all may not agree with his recommendations, we should all be considering what better management should be taken to reduce this hazard. In many conditions encountered in gastroenterological practice the problem of parenteral feeding arises. Some of the enthusiasm that always accompanies any new therapy has now evaporated, and the time is ripe to reconsider the place of this method of feeding. This is provided in a highly critical review by Professor Wilkinson. There are two purely surgical chapters. The liver, it may be said, is the last of the abdominal viscera to be attacked surgically, and it is only in recent years problems posed by hepatic surgery have been considered seriously and some attempt made to solve them. Mr. Rodney Smith discusses the difficulties and indicates some of the solutions, and also hints at the tantalizing opportunities offered by the extraordinary capacity of the liver to regenerate. The pancreas has long been an organ of some mystery,

INTRODUCTION

not readily accessible to investigative methods, and diagnosis has been difficult and treatment hesitant. It is fitting to conclude this volume with an authoritative exposition of pancreatic surgery by Dr. Warren with his quite unrivalled experience in this special field.

W. I. CARD

Edinburgh
June, 1961

CONTENTS

Introduction	Page ix
<i>Chapter</i>	
<p>1. ELECTRON MICROSCOPY OF THE ALIMENTARY TRACT</p> <p style="padding-left: 40px;">G. M. Wyburn, M.B., D.Sc., F.R.F.P.S.G., F.R.S.E., <i>Regius Professor of Anatomy, University of Glasgow;</i> and A. D. Hally, M.D., <i>Lecturer in Anatomy, University of Glasgow; formerly visiting Assistant Professor in Anatomy, University of Minnesota, U.S.A.</i></p>	1
<p>2. GEOGRAPHICAL ASPECTS OF PEPTIC ULCER</p> <p style="padding-left: 40px;">Geoffrey Watkinson, M.D., M.R.C.P., <i>Consultant Physician to the York Hospitals; Late Senior Lecturer, in Medicine, University of Leeds; and Late Honorary Consultant Physician, United Leeds Hospitals</i></p>	23
<p>3. ABO BLOOD GROUPS AND GASTRO-INTESTINAL DISEASE</p> <p style="padding-left: 40px;">Ian Aird, Ch.M., F.R.C.S., F.R.C.S.(Ed.), F.A.C.S. (Hon.), <i>Professor of Surgery in the University of London; Director of the Department of Surgery, Postgraduate Medical School of London, Hammersmith Hospital</i></p>	49
<p>4. VIRUS INFECTIONS OF THE GASTRO-INTESTINAL TRACT</p> <p style="padding-left: 40px;">N. R. Grist, B.Sc., M.B., Ch.B., F.R.C.P.(Ed.), <i>Lecturer in Virology, Department of Virology and Virus Laboratory, Glasgow University; Regional Adviser in Virology, Western Regional Hospital Board, Scotland</i></p>	64
<p>5. BILIRUBIN METABOLISM</p> <p style="padding-left: 40px;">Hugh R. Butt, M.D., M.S., <i>Consultant, Section of Medicine, Mayo Clinic; Professor of Medicine, Mayo Foundation, Graduate School, University of Minnesota;</i> William T. Foulk, M.D., B.A., M.S., <i>Consultant, Section of Medicine, Mayo Clinic, Assistant Professor of Medicine, Mayo Foundation, Graduate School, University of Minnesota;</i> and Harry N. Hoffman, II, M.D., M.S., <i>Consultant, Section of Medicine, Mayo Clinic; Medical Instructor of Medicine; Mayo Foundation, Graduate School, University of Minnesota, U.S.A.</i></p>	86

CONTENTS

Chapter		Page
6.	THE PRESENT POSITION IN RADIOLOGY OF THE SMALL INTESTINE . D. H. Cummack, M.B., Ch.B., F.R.C.S. (Ed.), D.M.R., <i>Senior Consultant Radiologist, Western General Hospital, Edinburgh;</i> and W. A. Copland, M.B., Ch.B., D.M.R.D., F.F.R., <i>Consultant Radiologist, Western General Hospital, Edinburgh</i>	102
7.	THE MANAGEMENT OF PERITONITIS . T. Menzies, M.B., Ch.B., F.R.C.S. (Ed.), <i>Senior Surgical Registrar, Hammersmith Hospital and the Postgraduate Medical School of London</i>	127
8.	NUTRITIONAL LIVER DISEASE IN MAN . J. C. Waterlow, M.A., M.D., <i>Director of the Medical Research Council's Tropical Metabolism Research Unit; Honorary Professor of Experimental Medicine, University College of the West Indies;</i> and G. Bras, M.D. (Batavia), <i>Professor of Pathology, University College of the West Indies, Jamaica, W.I.</i>	158
9.	THE ZOLLINGER-ELLISON SYNDROME . Jack M. French, M.D., Ph.D., M.R.C.P., <i>Member of External Scientific Staff, Medical Research Council; Honorary Reader in Medicine, Department of Medicine, University of Birmingham; Honorary Senior Associate in Medicine, Queen Elizabeth Hospital, Birmingham;</i> and Wilfred Sircus, M.D., Ph.D., M.R.C.P., M.R.C.P.(Ed.), <i>Member of the External Scientific Staff, Medical Research Council; Lecturer in the Department of Medicine, University of Edinburgh; Physician to the Gastro-intestinal Unit, Western General Hospital, Edinburgh</i>	178
10.	IMAGE INTENSIFIER AND MANOMETRIC TECHNIQUES— LOWER END OF THE OESOPHAGUS . E. Clinton Texter, Jnr., M.D., F.A.C.P., <i>Associate Professor of Medicine and Director of the Training Program in Gastroenterology, Northwestern University Medical School; Attending Physician, Passavant Memorial Hospital; Chief of Gastroenterology Section, Veterans' Administration Research Hospital, Chicago, Illinois, U.S.A.</i>	199

CONTENTS

Chapter		Page
11.	TELEMETERING OF GASTRO-INTESTINAL MOTILITY John T. Farrar, M.D., <i>Chief, Gastroenterology Section of the Medical Service, Veterans' Administration Hospital, New York City; Assistant Professor of Clinical Medicine, Cornell University Medical College, New York, U.S.A.</i>	223
12.	PARENTERAL FEEDING A. W. Wilkinson, Ch.M., F.R.C.S.(Ed.), F.R.C.S., <i>Nuffield Professor of Paediatric Surgery at the Institute of Child Health and the Hospital for Sick Children, Great Ormond Street, London</i>	234
13.	SOME RECENT ASPECTS OF HEPATIC SURGERY Rodney Smith, M.S., F.R.C.S., <i>Surgeon, St. George's Hospital, London</i>	252
14.	SURGERY OF PANCREATIC DISEASE Kenneth W. Warren, M.D., <i>Surgeon, Lahey Clinic; Surgeon, New England Baptist and New England Deaconess Hospitals, Boston, Mass., U.S.A.</i>	264
	INDEX	301

CHAPTER 1

ELECTRON MICROSCOPY OF THE ALIMENTARY TRACT

G. M. WYBURN AND A. D. HALLY

The aim of the biologist is to resolve structure down to its functioning units and to link up his observations with those of the physical chemist who is building small molecules into large molecules, and for both the target is the macromolecules of living tissue. As a biological tool the electron microscope has displayed in detail the organized fibrous or membranous structure of living tissue but we have as yet no means of direct observation of the three-dimensional intramolecular morphology determined by the short range forces of the valency bond. Much of the electron microscopic examination of tissues and organs is still of the nature of surveys assigning descriptive terms to fine structure, whose contribution to cell activity is only partially understood, but here and there it has been possible to define a unit structure recognized by biologist and chemist alike.

Many intracellular systems are organized as membranes and commonly seen in electron micrographs of osmium fixed tissue sections as adielectronic* lines representing membranes cut edge on. Such is the appearance of the bounding membrane of cells, of the framework of mitochondria, of the nuclear membrane, and of the covering membranes of the cytoplasmic vacuolated system known as the endoplasmic reticulum. The basic structure of these membranes is an arrangement of lipoprotein molecules, and their special biological property as cell membranes, and presumably also as intracellular systems, is selective permeability. They are labile structures, not static textures, and the regulation of the kind of particle—ion or molecule—which can pass through different membranes and the same membrane at different times is likely to depend on active processes within the fabric itself. One recent suggestion is that semi-permeable membranes function as ionic exchangers and produce reversible hydration with consequent changes in membrane polarization. The intracellular membranes also provide the necessary large

* Adielectronic: lines which appear dense in electron micrographs because their substance scatters the 'electrons' in the same way as opaque material scatters light.

surfaces and floor space for the enzymes which are an essential part of the cell's metabolic machinery.

In the past few years electron microscopic observations of secreting cells, including those of the epithelium of the stomach, have provided a knowledge of intracellular structure which could be a prelude to a more complete understanding of their normal and abnormal functional activity.

THE STOMACH

The gastric epithelial cells are classified as the parietal or acid-secreting cell, the body chief or zymogenic cell, the mucous neck cells which secrete mucus into the glands, and the surface epithelial cells which also secrete mucus. Electron microscopic studies of the gastric mucous membrane have been concerned mainly with the parietal and zymogenic cells (Sedar, 1955; Kurosumi and colleagues, 1958; Helander and Ekholm, 1959; Hally, 1959; Lawn, 1960).

The Parietal Cell

The parietal cells are most numerous in the upper third of the secreting portion of the gastric glands where, along with the mucous neck cells they have a free surface abutting on the gland lumen. Towards the bottom of the gland they are situated more peripherally, and separated from the lumen by the zymogenic cells. The parietal cell is pyramidal with the apex towards the lumen, it is larger than the other glandular cells, and its light microscopic characteristic is oxyntic granules which can be recognized by the electron microscope as mitochondria arranged in peripheral and perinuclear groups (Plate Ia). The framework of mitochondria consists of a pair of limiting membranes, and internal 'cristae' which are shelf-like folds of the inner limiting membrane lying transverse to the long axis of the mitochondria (Plate IIa; *Figure 2*). The abundant mitochondria of the parietal cell have a high electron density, are ovoid with a mean thickness of 0.57μ as compared to 0.25μ for those of the intestinal epithelium, and the cristae are characteristically close-packed (Plate IIa), giving the parietal cell an unusually extensive area of cristae. The most readily available source of energy in the human body is glucose which, when oxidized through a series of complex reactions, releases labile energy in the form of the high energy phosphate bonds of adenosinetriphosphate (ATP). By the application of suitable histochemical methods to

electron microscopic studies, it has been possible to demonstrate that the succinic dehydrogenase system of enzymes involved in the oxidation of glucose and the liberation of the high energy phosphate bonds of ATP are located on or within the cristae of the mitochondria (Barnett, 1959a), and Green, Lester, and Ziegler (1957) have shown that structurally intact cristae are necessary for oxidative phosphorylation. The gastric mucosa of mammals is capable of concentrating hydrogen ions some million times, and this requires a vast expenditure of energy. Most experimental evidence (Davenport, 1957) suggests that the efficiency of the mucosa is less than 4, that is, fewer than 4 hydrogen ions are produced as acid for every oxygen molecule consumed, and several theories of hydrochloric acid formation have been proposed which are compatible with this ratio of 4. If the efficiency is less than 4, then calculations reveal that the parietal cell has a relatively enormous rate of oxygen consumption compared to other mammalian cells. Davies (1957) considered this to be unlikely, and therefore rejected theories based on this figure. The fine structure of the parietal cell, however, indicates an unusually high metabolic rate, which would support the views of Davenport amongst others.

Intracellular Canaliculi

A branching system of intracellular canaliculi is visible in most electron micrographs of the parietal cell (*Figure 1*). These intracellular canaliculi open at the free apical surface of the cell and communicate either directly or, in the peripherally situated cells, indirectly via an intercellular canaliculus, with the lumen of the gland. The canaliculi are tubular and therefore appear circular in cross section (*Plate IIc*). Large numbers of microvilli project into the lumen from the walls of the canaliculi and in starved animals, where the canaliculi are collapsed, the lumen is filled with a complex system of membranes (*Plate Ia*) which at high magnification are found to be microvilli cut at random (*Plate IIIa; Figure 2*). The system of intracellular canaliculi that, amongst mammalian cells at any rate, is found only in the parietal cell, must have some special significance. The parietal cell is pyramidal with a broad basal surface for the exchange of materials with the underlying capillaries. Towards the lumen, at the apex of the cell, the secretory surface would be small were it not greatly increased by the intracellular canaliculi which can be regarded as invaginations of its secretory surface. Assuming certain measurements which, if anything, are underestimates, it has been shown that the secretory surface area

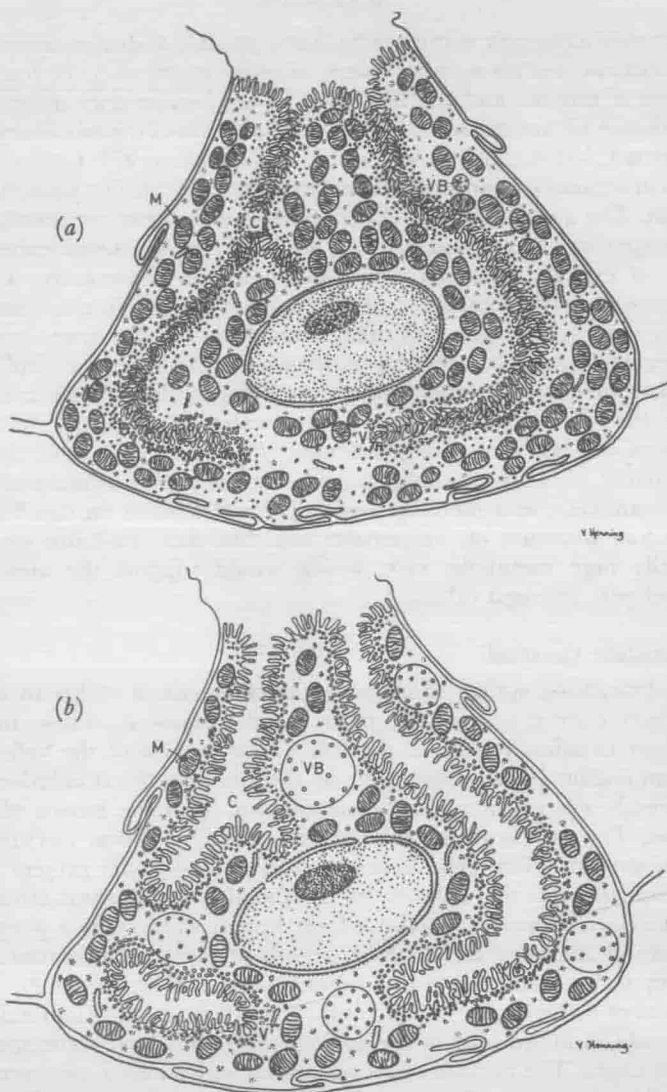


Figure 1. Diagram of a parietal cell (a) in a starved animal with dense mitochondria (M), collapsed intracellular canaliculi (C) opening into the lumen, cytoplasmic vacuoles (V), and a small vacuole-containing body (VB); (b) in pilocarpine-treated animal showing prominent distended canaliculi (C) in which the microvilli are now clearly seen, and enlarged vacuole-containing bodies (VB)

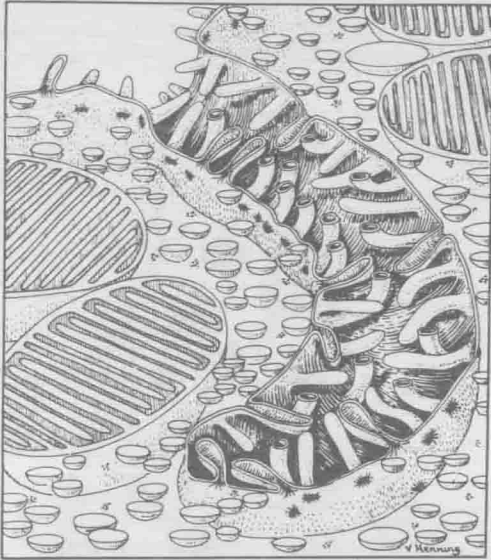


Figure 2. Diagram of apical portion of parietal cell with canaliculus extending upwards to open into the gland lumen. Microvilli line the walls of the canaliculus

provided by the canaliculi and further increased by the microvilli is approximately $500 \mu^2$ for each cell, which compares very favourably with other secretory cells (Hally, 1959). In addition, the canaliculi provide ready and easy access for the transit of cell secretions to the lumen of the gland.

Vacuole-containing Body

In any cross section of a parietal cell there are one or two vacuoles which contain much smaller vacuoles and these so-called vacuole-containing bodies have now been observed in many animal cells.

The Endoplasmic Reticulum

The term endoplasmic reticulum was introduced in the early days of electron microscopy to describe a network of membrane-lined interconnected tubular and vacuolar spaces first observed in the cytoplasm of fibroblasts, and since found in some form or another in all animal cells with the exception of the adult mammalian red blood

cell. The endoplasmic reticulum permeates the cytoplasm from the cell membrane to the nuclear membrane and may show in section as rounded or oval profiles, but commonly there are broad flattened sacs which appear in section as pairs of parallel dense lines continuous with one another at the ends (Plates IV and VIIIa; Figure 3). The membranes lining the flattened sacs may be studded with small

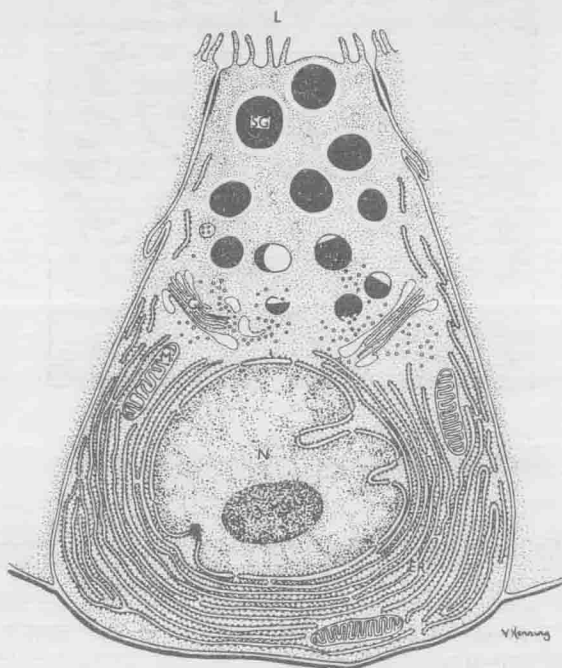


Figure 3. Diagram of Paneth cell, which is similar to other zymogenic cells. The membrane pairs, studded with RNA granules, forming the endoplasmic reticulum (ER) are arranged in concentric layers around the nucleus. A Golgi complex (G) lies above the nucleus in close relation to small secretory granules. Mature secretory granules (SG) fill the apical third of the cell.

granules to form a granular endoplasmic reticulum as compared to the smooth-faced membranes forming an agranular endoplasmic reticulum. The endoplasmic reticulum of the parietal cell is represented by vacuoles or tubules bounded by smooth membranes. In the rat and the mouse vacuoles predominate (Plate Ib), but in the human (Lilliebridge, 1960) tubules are prominent. Further, Lilliebridge found that these tubules occasionally open on to the luminal

surface between the bases of microvilli, an arrangement which would allow the contents of the spaces of the endoplasmic reticulum to empty into the lumen.

Secretory Changes

Following injections of pilocarpine into starved animals (Hally, 1960) changes occur in the parietal cells (*Figures 1a and b*). There is dilatation of the intracellular canalicular system and more numerous vacuole-containing bodies increased in size from less than $0.5\ \mu$ up to $3\ \mu$ (Plates IIc and IIIb). Sedar (1959) demonstrated an increase in the number of cytoplasmic vacuoles around the canaliculi, with a significant rise in the succinic dehydrogenase activity of parietal cells after the administration of histamine. Histamine acts directly on the parietal cells (Plate Ib) and one theory suggested (Alivisatos, 1960) is that the production of hydrochloric acid may be a catalysed histaminolysis of diphosphopyridine nucleotide (DPN) yielding as one of the end products a hydrogen ion, and it is argued by analogy that the responsible enzyme may be located on the secreting side of the cell membrane. It would appear, therefore, that both the cytoplasmic vacuoles and the vacuole-containing bodies are in some way concerned in the secretory activity of the parietal cell.

The Zymogenic Cell

The characteristic light microscopic features of the zymogenic or body chief cell are the basophil substance in its basal zone and the secretory granules in the apical cytoplasm. In electron micrographs of osmium-fixed sections the basophil substance shows as arrays of parallel dense lines studded on one face with small granules and arranged with their long axes perpendicular to the basal cell surface. As already stated, these dense lines are the elongated profiles of the flattened sacs of the endoplasmic reticulum cut edge on. Typically, the sacs are stacked and orientated one on top of the other with small granules adherent to the outer surfaces of the bounding membranes, that is, a granular endoplasmic reticulum. The granules, which are nucleoprotein (RNA), show a rapid uptake of radioactive amino acids, indicating their concern with protein synthesis, and some enzymes, notably DPNH-cytochrome C reductase, are localized on the membranes. The granular endoplasmic reticulum is prominent in cells elaborating secretions with a high protein content (*Figure 3*). In the intermediate cell zones the profiles tend to become tubules (Plate IV). The cytoplasm of the apical zone is packed with granules