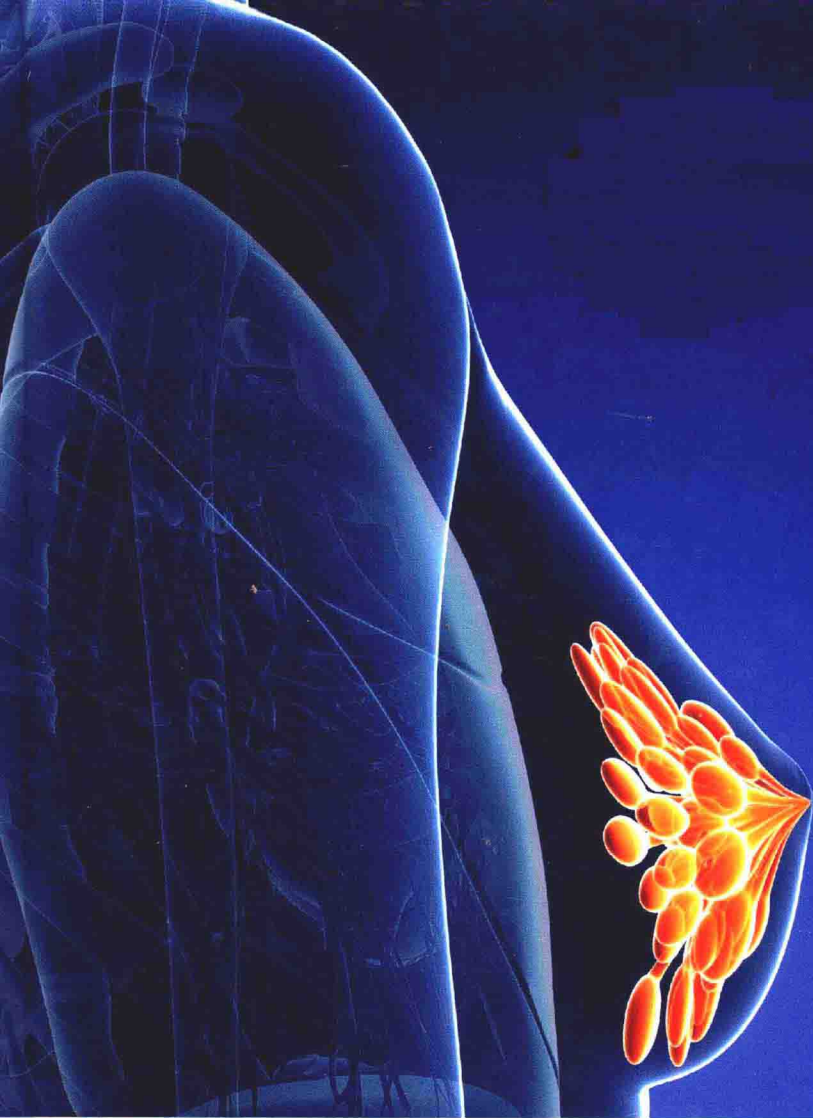


New Aspects and
▪ Techniques of
Breast
▪ **Reconstruction**

Sandra Legin

New Aspects and Techniques of Breast Reconstruction

Edited by Sandra Legin



hayle
medical

New York

Published by Hayle Medical,
30 West, 37th Street, Suite 612,
New York, NY 10018, USA
www.haylemedical.com

New Aspects and Techniques of Breast Reconstruction

Edited by Sandra Lakin

© 2015 Hayle Medical

International Standard Book Number: 978-1-63241-289-8 (Hardback)

This book contains information obtained from authentic and highly regarded sources. Copyright for all individual chapters remain with the respective authors as indicated. A wide variety of references are listed. Permission and sources are indicated; for detailed attributions, please refer to the permissions page. Reasonable efforts have been made to publish reliable data and information, but the authors, editors and publisher cannot assume any responsibility for the validity of all materials or the consequences of their use.

The publisher's policy is to use permanent paper from mills that operate a sustainable forestry policy. Furthermore, the publisher ensures that the text paper and cover boards used have met acceptable environmental accreditation standards.

Trademark Notice: Registered trademark of products or corporate names are used only for explanation and identification without intent to infringe.

Printed in China.

Preface

The main aim of this book is to educate learners and enhance their research focus by presenting diverse topics covering this vast field. This is an advanced book which compiles significant studies by distinguished experts in the area of analysis. This book addresses successive solutions to the challenges arising in the area of application, along with it; the book provides scope for future developments.

This book presents a broad overview on the various aspects of surgical methods used for breast reconstruction. The reconstruction procedures for breast cancer patients have seen the rise of flap-based and implant-based surgeries as the two primary methods. Both these procedures have been undergoing evolution and advancements for improving outcomes and patient satisfaction. This book sheds light on options in mastectomy, growing significance of fat grafting, recent advancements in robotic latissimus flap harvesting, as well as criteria for selecting the optimum procedure in difficult situations. There is also special focus on current progresses in the field of lymphedema surgery which is rapidly growing in significance as an aiding technique for breast surgery.

It was a great honour to edit this book, though there were challenges, as it involved a lot of communication and networking between me and the editorial team. However, the end result was this all-inclusive book covering diverse themes in the field.

Finally, it is important to acknowledge the efforts of the contributors for their excellent chapters, through which a wide variety of issues have been addressed. I would also like to thank my colleagues for their valuable feedback during the making of this book.

Editor

Contents

	Preface	VII
Section 1	Oncology and Breast Reconstruction	1
Chapter 1	Selection of an Appropriate Method of Breast Reconstruction: Factors Involved in Customizing Breast Restoration Zachary Menn and Aldona Spiegel	3
Chapter 2	Oncoplastic Surgery Rachel Wellner	14
Section 2	Non Microsurgical Reconstruction	32
Chapter 3	Prosthetic Breast Reconstruction with Acellular Dermal Matrix Katie Weichman and Joseph Disa	34
Chapter 4	Implant-Based Dual-Plane Reconstruction of the Breast Following Sparing Mastectomy Egidio Riggio and Maurizio B. Nava	48
Chapter 5	Fat Grafting in Breast Reconstruction with Expanders and Prostheses in Patients Who Have Received Radiotherapy Jose Ma Serra-Renom, Jose Ma Serra-Mestre and Francesco D'Andrea	79
Chapter 6	Robotic Harvest of the Latissimus Dorsi Muscle for Breast Reconstruction Jesse Selber	96
Section 3	Microsurgical Reconstruction	110
Chapter 7	Mastering the Deep Inferior Epigastric Artery Perforator Flap (DIEP): Refining Techniques and Improving Efficiency Joshua L. Levine, Julie V. Vasile, Hakan Usal, Heather A. Erhard and John J. Ho	112

Chapter 8	Septocutaneous Gluteal Artery Perforator (Sc-GAP) Flap for Breast Reconstruction: How We Do It	123
	Stefania Tuinder, Rene Van Der Hulst, Marc Lobbes, Bas Versluis and Arno Lataster	
Chapter 9	Double Venous System Drainage in Deep Inferior Epigastric Artery Perforator Flap Breast Reconstruction	149
	Scott Reis, Jules Walters, Jason Hall and Sean Boutros	
Chapter 10	Profunda Artery Perforator (PAP) Flap for Breast Reconstruction	157
	Constance M. Chen, Maria LoTempio and Robert J. Allen	
Chapter 11	The Use of Proximal and Distal Ends of Internal Mammary Arteries and Veins as the Recipient Vessels for Combined Breast and Chest Wall Reconstruction with Free Bipedicled TRAM or DIEP Flap	168
	Lan Mu and Senkai Li	
Chapter 12	Getting Out of a Tight Spot in Breast Reconstruction – Salvage and Saving Techniques for DIEP, SIEA, and Lymphatic Flaps	180
	Rebecca Studinger	
Section 4	Lymphedema	221
Chapter 13	Treatment of Breast Cancer-Related Lymphedema Using Combined Autologous Breast Reconstruction and Autologous Lymph Node Transplantation	223
	Corinne Becker	

Permissions

List of Contributors

Oncology and Breast Reconstruction

Selection of an Appropriate Method of Breast Reconstruction: Factors Involved in Customizing Breast Restoration

Zachary Menn and Aldona Spiegel

Additional information is available at the end of the chapter

1. Introduction

When considering breast reconstruction, the patient's perception essentially determines the success, or failure, of the reconstruction. It is important for the surgeon to ask questions and listen to the patient to determine what expectations the patient has for the final results. In the past, the goal of breast reconstruction was to help a patient look "normal" in clothing. With the advancements in technique and technology, we have raised the bar so that patients look good not only in clothing, but also when they see themselves undressed in the mirror. In this chapter we will discuss how to match a breast reconstruction candidate with the procedure that will provide the best result.

2. The defect

As with any reconstructive procedure, the first step is the evaluation of the defect to be reconstructed. The size, shape, and quality of the defect are all important factors and are resultant from the type of mastectomy performed. Radical, modified radical, skin sparing, areolar sparing, and nipple sparing mastectomies all create a different defect with different requirements for reconstruction. It is important to determine if the defect simply requires volume replacement or if there is a component of skin that needs to be replaced. It is vital to examine the skin flaps remaining after the mastectomy for any damage from radiation or the surgery. If the skin is not viable or has radiation damage it may be unusable in the reconstruction and require resection. The amount and type of volume replacement needs to be estimated by determining the final preference for breast size of the patient.

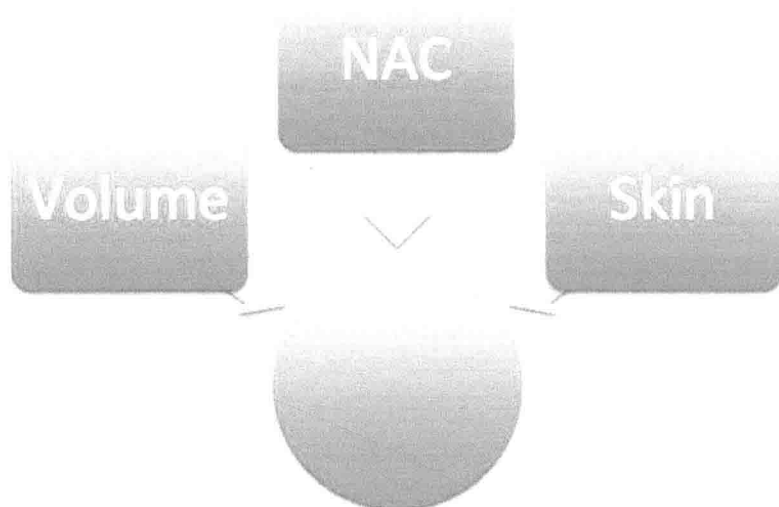


Figure 1. The type of reconstruction should be chosen based upon what is missing following mastectomy including breast volume, nipple-areolar complex and/or skin.

3. The patient

3.1. Patient assessment

During the patient assessment at the initial visit, there are many important pieces of information that should be gathered during the history and physical.

Physical Exam: The size of the breast(s) to be reconstructed needs to be considered in your planning, as well as whether the reconstruction will be unilateral or bilateral. Bilateral reconstruction and larger breasts will require a larger volume of donor site tissue which may limit some reconstructive options. Examine the breasts for scars, asymmetry, ptosis, nipple position and skin quality making sure to point out any irregularities to the patient. The distribution and amount of excess soft tissue should also be noted. First, examine the abdomen for adipose tissue volume. Next examine the back, buttocks and inner thighs for laxity and soft tissue volume.

Oncologic status: The patient's oncologic status should be requested to determine what prior treatments they already completed and if there is a future need for radiation. It is also important to determine if the prior treatment was adequate, particularly if the patient was referred from an outside facility. Additional radiologic studies may be necessary to make this determination. If the patient has not received adequate treatment, there may be future need for radiation, which might change the approach to reconstruction.

Medical history: A thorough medical history is important before considering a type of reconstruction because some medical and social issues may be contraindications to certain reconstructive procedures. Some contraindications to free flaps include: smoking, diabetes, obesity, peripheral vascular disease, clotting disorders, and advanced age. Breast implant manufacturers caution that the safety and effectiveness of these devices have not been established in patients with autoimmune diseases (such as lupus and scleroderma), a compromised immune system (receiving immunosuppressive therapy) or patients with conditions or medications which interfere with wound healing ability (such as corticosteroid therapy or poorly controlled diabetes) or blood clotting (such as coumadin therapy).¹ Each of these factors should be inquired about, as they have an impact on procedure selection.

Surgical history: Surgical and obstetric history should be taken. All C-sections, abdominoplasties, liposuction procedures, traumas, abdominal surgeries, and any scar severing the blood supply to specific areas of excess soft tissue (abdomen, buttock, back and thigh) should be noted as this will determine which body areas are available as a donor site for reconstruction.

Family and Social history: Age, marital status, family history and social support may greatly impact the decision of which type of reconstruction best fits a specific patient. A young, thin patient with a strong family history of breast cancer, BRCA positive, having prophylactic nipple sparing mastectomies, may be more suited for an implant only reconstruction due to possible lack of excess soft tissue that may be seen more prominently in an older individual. Social support is also important to consider as well as activity level requirements in employment, allotted time off work, and home responsibilities. This is why it is important to discuss the patient's social situation and support network before deciding on a type of breast reconstruction.

3.2. Patient expectations and goals

A conversation with the patient should be had to determine the size of the breast(s) to be reconstructed and decide whether it will be a unilateral or a bilateral reconstruction. At this time, it is also important to assess the patient's perception of the contralateral breast. Some patients may need bilateral reconstruction due to the spread of the disease and require a mastectomy, while others may opt for a prophylactic mastectomy due to a genetic predisposition for breast cancer. Others may not need a mastectomy on the contralateral breast, but some symmetry surgery may still be necessary. Autologous reconstruction can typically match the contralateral breast, while implant only reconstruction makes matching the native breast more difficult. The patient should be counseled at the initial visit about the possibility of surgery on the contralateral breast even though it is unaffected by the cancer. Another patient factor, possibly the most important to consider, is the patient's preference of reconstruction. It is the surgeon's job, as the expert, to explain the reconstructive options, educate the patient as to the best option for their specific situation, and ultimately let the patient decide upon the option with which they are most comfortable.

3.3. Patient commitment

It is vital that patients who expect to undergo autologous reconstruction commit to a healthy lifestyle and prepare their body for the major surgery that is breast reconstruction. Smoking secession and weight loss are important, if necessary. There is also a commitment after the surgery to follow up at least once and restrict activities for four to six weeks after autologous reconstruction.

4. The surgeon

The surgeon plays the major role in the success of the surgery. As the choices for breast reconstruction have evolved, it has been noted that specialized microsurgical procedures have a “learning curve” and are more successful when performed by a surgeon or team with a higher volume of cases.²

4.1. Types of reconstruction

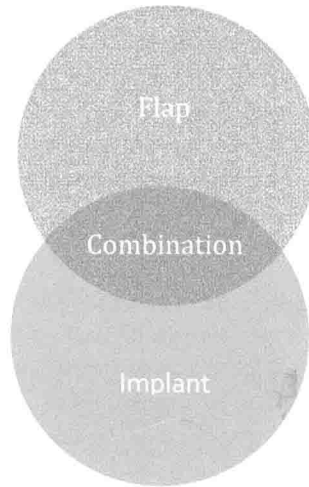


Figure 2. Breast reconstruction can be broken down into two categories: autologous flap reconstruction and implant-based reconstruction. However, in some cases, a combination of the two may provide the best result.

4.2. Tissue expanders/implants

This is a popular choice for breast reconstruction; it involves no donor site incision and minimal recovery time. There is no need for a donor site, so this type of reconstruction is suitable for patients who may have been ruled out for other reconstructions due to an insufficient donor site. This type of reconstruction is also preferable for older and less healthy patients who may not be able to tolerate a lengthier, flap-based reconstructive procedure. The surgeon needs to

consider the timing of implant placement if future radiation therapy is required. The sequence and timing of implant placement after radiotherapy influences the complication rate. Reconstructive failure is significantly higher if the time between completion of radiotherapy and implant exchange is less than 6 months.³ In many cases where the mastectomy has been radiated, implant only reconstruction is not an option due to higher complication rates and the need for skin replacement. The use of acellular dermal matrices can be helpful with implant only reconstruction, but in the end it is the surgeon's preference. With this option, the patient needs to be counseled about the risk and benefit of implants versus autologous flap reconstruction. The short term risks are reduced since the recovery does not involve a donor site. However, long term risks are higher as inherent to the implant device.

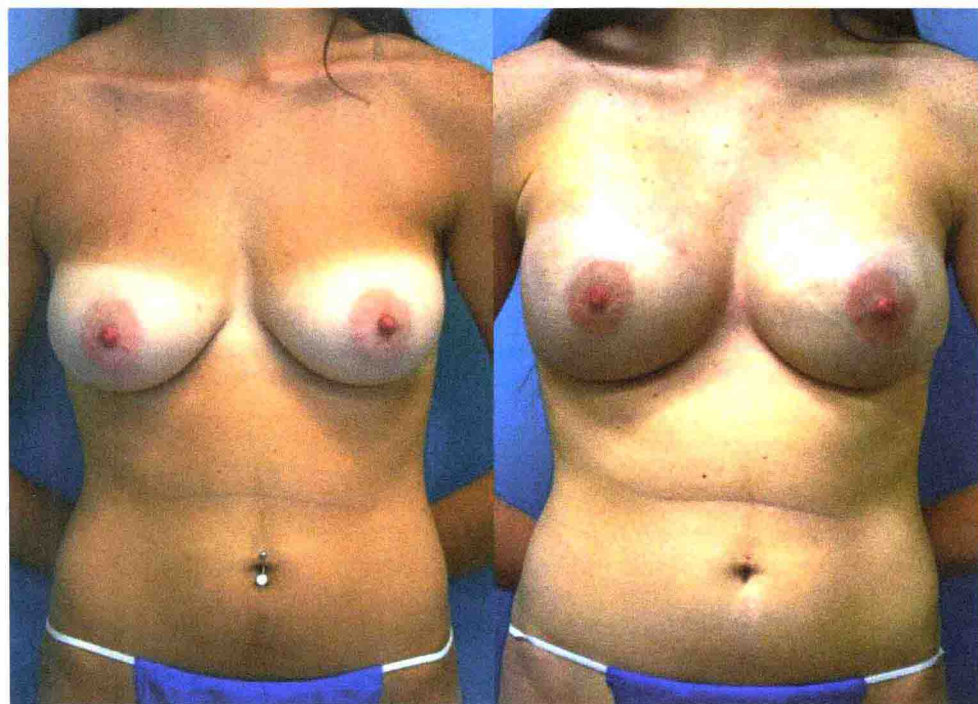


Figure 3. Preoperative and postoperative views of a bilateral tissue expander and implant based breast reconstruction.

4.3. Autologous flaps

4.3.1. Abdominal flaps

When examining a patient for breast reconstruction, a pinch test will help to estimate the amount of excess tissue available. In general, an average patient with a BMI greater than 20

and a history of at least one pregnancy should have enough abdominal tissue for a unilateral B to C cup breast reconstruction. The most important requirement for this flap is patent vessels in the lower abdomen. Previous abdominoplasty and extensive liposuction are contraindications to these flaps due to the disruption of the underlying blood supply. On examination, look for any abdominal scars. Scars may indicate a previous severance of the subcutaneous vasculature. Vessel patency can be determined by CTA or use of Doppler ultrasound.

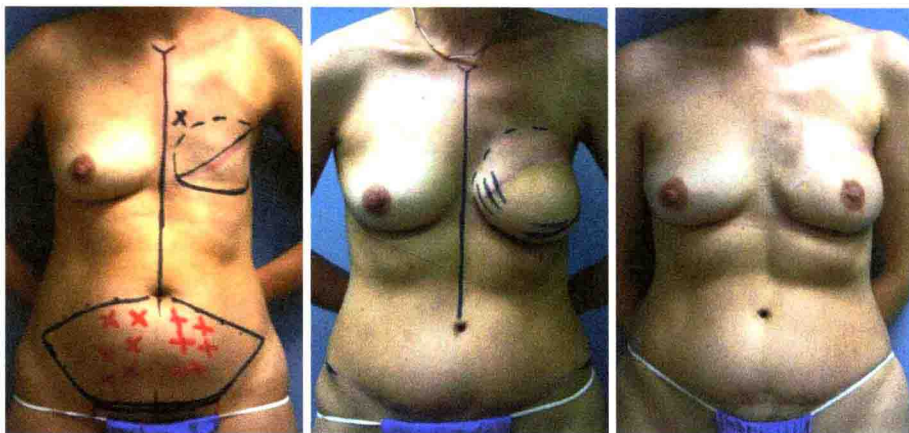


Figure 4. Preoperative markings and postoperative views of an abdominal perforator-based free flap breast reconstruction.

4.3.1.1. DIEP

This is the first choice for autologous reconstruction in our Center. The indications for the DIEP are similar to the indications for SIEA and TRAM as far as the need for excess lower abdominal tissue. Optimal perforator selection is key, as it impacts flap perfusion and muscle preservation. Imaging is helpful to determine if blood supply is patent and to map out the best perforator vessels. The DIEP flap may be combined with an implant to increase volume for a better size match with the contralateral breast or to improve the aesthetic outcome.

4.3.1.2. SIEA

Much like the DIEP flap, the SIEA flap requires excess lower abdominal tissue but is not a perforator flap. The difference between the two flaps is the blood supply with the SIEA using the superficial inferior epigastric artery to perfuse the flap. The availability of the SIEA has been shown to be variable. Drs Taylor and Daniel demonstrate that the SIEA was not present in 35% of their 100 cadaveric dissection specimens.⁴ More recent literature by Stern and Nahai showed that 87% of subjects had an identifiable SIEA, while Reardon et al found the SIEA in 90% of subjects.⁵⁻⁷ Specific to the survival of the SIEA flap is the need for a donor artery of 1.5 mm diameter or greater described by Spiegel et al.⁸ This study found that in 278 clinical

dissections over a 3 year period, approximately 31% of cases had identifiable superficial inferior epigastric arteries that were larger than 1.5 mm in diameter. The infrequent availability of a sufficiently sized artery limits the use of this type of reconstruction.

4.3.1.3. TRAM

The TRAM flap can be used as a pedicled or free flap. The use of this flap depends on the surgeon and the situation. Preserving the muscle has become more ubiquitous. The DIEP flap has become more of the standard of care as more residents are being taught this procedure. The use of a pedicled TRAM flap may be appropriate if a free flap is not possible in the selected patient.

4.3.2. Latissimus flap

The latissimus dorsi flap is a good second choice flap if the lower abdomen is inadequate, unavailable, or if the patient is opposed to an abdominally-based reconstruction. The volume of this flap is dependent upon the amount of soft tissue available on the back and skin laxity. Skin laxity is important for creating a skin island with the flap to replace skin deficit left from the mastectomy.

The latissimus dorsi flap may be muscle and soft tissue alone, or if skin is needed, it can be taken as a musculocutaneous flap. If a large amount of soft tissue is needed, an extended latissimus myocutaneous flap can be used in order to include more fat with the flap. Due to the limited volume that is provided, even with the extended latissimus dorsi myocutaneous

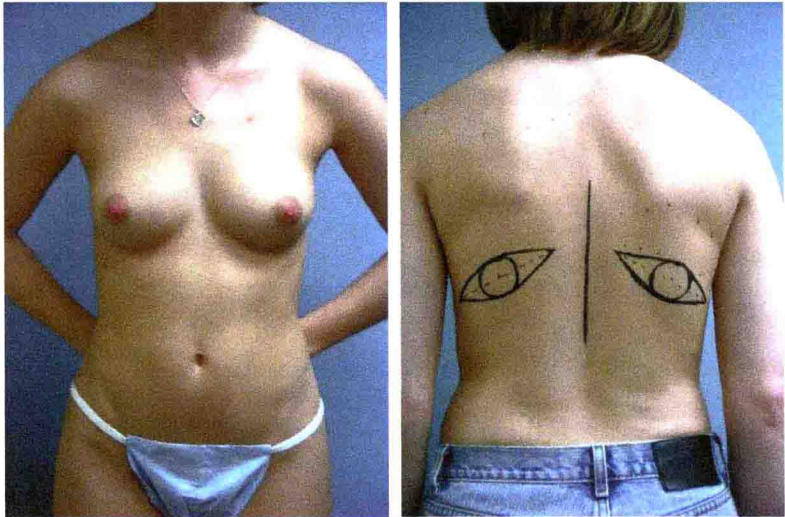


Figure 5. Anterior and posterior views of a preoperative bilateral latissimus dorsi breast reconstruction patient with markings.

flap, these flaps are usually combined with an implant to produce an adequate breast size. This flap generally provides donor site scars that are easily hidden in clothing.

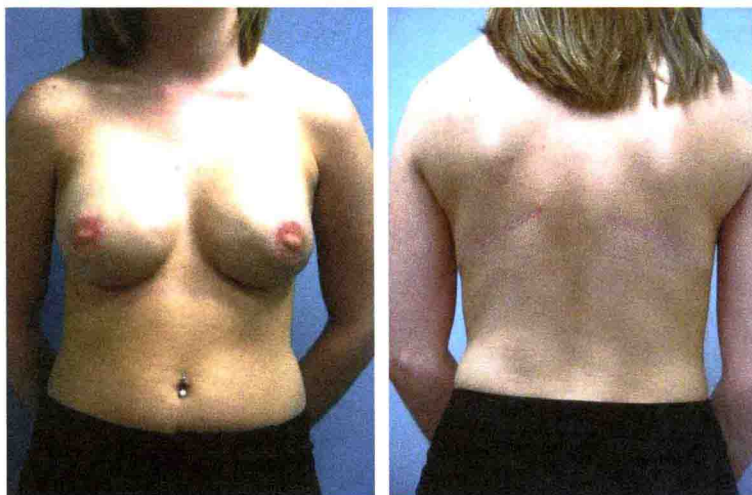


Figure 6. Anterior and posterior views of a postoperative bilateral latissimus dorsi breast reconstruction patient.

4.3.3. Gluteal flaps

Gluteal flaps are an alternative choice for autologous reconstruction when an abdominal donor site has been ruled out due to insufficient tissue or compromised blood supply from previous surgery or scarring. Another reason for choosing this flap is simply an excess amount of available soft tissue in the gluteal region. Patient preference plays a significant role in the selection of this flap because even if the patient has enough gluteal tissue to create a breast, they may like their current gluteal shape and may not be willing to change it.

The gluteal myocutaneous flap was described for breast reconstruction by Fujino in 1981.⁹ Since that time, the gluteal flap has evolved into the SGAP, IGAP, and scGAP flaps. These perforator flaps are far more popular now due to the decreased donor site morbidity. Gluteal artery perforator flaps have become a well-liked alternative when the first line abdominal flaps are not available.

The choice of the SGAP and IGAP flaps depend on the patient and surgeon. Patients who wish to get rid of “saddlebags” while maintaining superior fullness of the buttocks may benefit from the IGAP which hides its scar in the inferior gluteal fold; however some reports state that the lateral edge of the scar may be visible in a bathing suit. The SGAP on the other hand, conceals its scar within most bathing suit bottoms at the expense of removing some of the superior fullness of the buttocks. The surgeon must decide which area has sufficient tissue to reconstruct the breast. The patient must also decide which scar/volume deformity they prefer. Working together the surgeon and patient must come to an agreement as to what would be best for the patient.

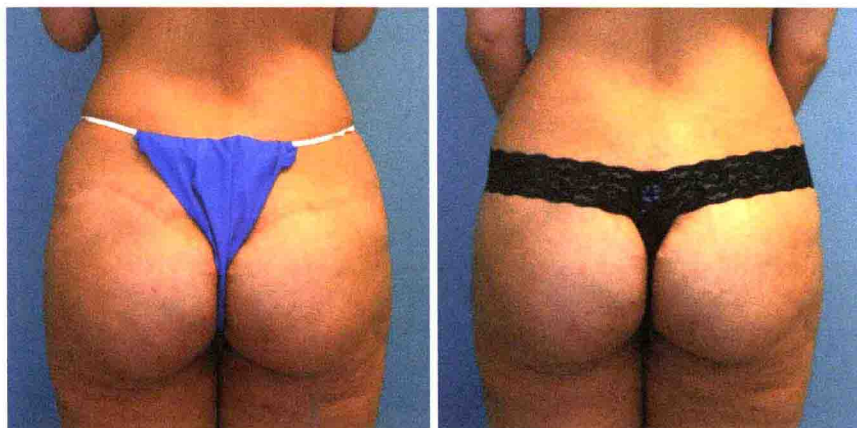

Figure 7. Postoperative view of the donor site scar from a superior gluteal artery perforator (SGAP) flap and a view showing the scar easily concealed by the patient's underwear.

4.3.4. Other flaps

4.3.4.1. TUG Flap

The TUG flap is best for patients with excess soft tissue in the medial thigh. This flap is indicated when other, more popular, flap donor sites have been ruled out due to insufficient tissue, compromised blood supply from previous surgery or scarring, or patient preference. This flap provides a well hidden donor site scar in the groin crease. This flap requires a surgeon familiar with this procedure.

4.3.4.2. PAP Flap

The PAP flap uses excess soft tissue of the medial thigh. This flap provides a well hidden donor site scar in the infragluteal fold. This flap is indicated when other donor sites have been ruled out due to insufficient tissue, compromised blood supply from previous surgery or scarring, or patient preference. Patient preference for this site is not the overall deciding factor as this flap also requires a surgeon who is familiar with this relatively new technique.

5. Other breast reconstruction techniques

5.1. Lipomodeling

Lipomodeling can be a sole mode of reconstruction for some surgeons who perform total breast reconstruction with ATF (autologous fat transfer) with or without the addition of an external tissue expander device; however, most surgeons use lipomodeling as an adjunct. It is useful