

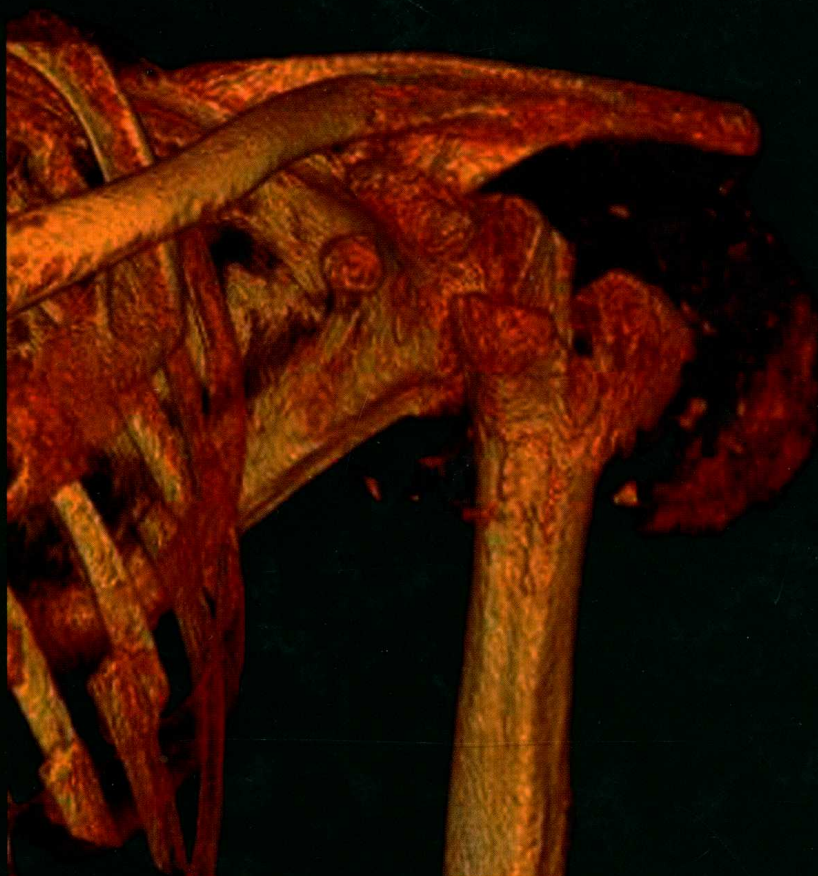
Get Full Access and More at

ExpertConsult.com

POPE | BLOEM | BELTRAN
MORRISON | WILSON

MUSCULOSKELETAL IMAGING

SECOND EDITION



ExpertRadiology

MUSCULOSKELETAL IMAGING

Copyright © 2015, 2008 by Saunders, an imprint of Elsevier Inc.

No part of this publication may be reproduced or transmitted in any form or by any means, electronic or mechanical, including photocopying, recording, or any information storage and retrieval system, without permission in writing from the publisher. Details on how to seek permission, further information about the Publisher's permissions policies and our arrangements with organizations such as the Copyright Clearance Center and the Copyright Licensing Agency, can be found at our website: www.elsevier.com/permissions.

This book and the individual contributions contained in it are protected under copyright by the Publisher (other than as may be noted herein).

Notices

Knowledge and best practice in this field are constantly changing. As new research and experience broaden our understanding, changes in research methods, professional practices, or medical treatment may become necessary.

Practitioners and researchers must always rely on their own experience and knowledge in evaluating and using any information, methods, compounds, or experiments described herein. In using such information or methods they should be mindful of their own safety and the safety of others, including parties for whom they have a professional responsibility.

With respect to any drug or pharmaceutical products identified, readers are advised to check the most current information provided (i) on procedures featured or (ii) by the manufacturer of each product to be administered, to verify the recommended dose or formula, the method and duration of administration, and contraindications. It is the responsibility of practitioners, relying on their own experience and knowledge of their patients, to make diagnoses, to determine dosages and the best treatment for each individual patient, and to take all appropriate safety precautions.

To the fullest extent of the law, neither the Publisher nor the authors, contributors, or editors, assume any liability for any injury and/or damage to persons or property as a matter of products liability, negligence or otherwise, or from any use or operation of any methods, products, instructions, or ideas contained in the material herein.

Library of Congress Cataloging-in-Publication Data

Imaging of the musculoskeletal system.

Musculoskeletal imaging / [edited by] Thomas L. Pope, Hans L. Bloem, Javier Beltran, William B. Morrison, David J. Wilson.—2nd edition.

p. ; cm.—(Expert radiology)

Preceded by: Imaging of the musculoskeletal system / [edited by] Thomas Lee Pope Jr. ... [et al.]. c2008.

Includes bibliographical references and index.

ISBN 978-1-4557-0813-0 (hardcover : alk. paper)

I. Pope, Thomas Lee, Jr., editor. II. Bloem, Hans L., editor. III. Beltran, Javier (Professor of radiology), editor. IV. Morrison, William B., editor. V. Wilson, David J. (David John), 1952- , editor. VI. Title. VII.

Series: Expert radiology series.

[DNLM: 1. Musculoskeletal Diseases—diagnosis. 2. Diagnostic Imaging—methods. 3. Musculoskeletal Diseases—radiography. 4. Musculoskeletal System—injuries. WE 141]

RC925.7

616.7'0754—dc23

2014027626

Senior Content Strategist: Don Scholz

Senior Content Development Specialist: Jennifer Shreiner

Publishing Services Manager: Patricia Tannian

Project Manager: Amanda Mincher

Manager, Art and Design: Steven Stave

Printed in China

Last digit is the print number: 9 8 7 6 5 4 3 2 1



Working together
to grow libraries in
developing countries

www.elsevier.com • www.bookaid.org

OTHER VOLUMES IN THE EXPERT RADIOLOGY SERIES

Abdominal Imaging

Imaging of the Brain

Breast Imaging

Cardiovascular Imaging

Imaging of the Chest

Gynecologic Imaging

Image-Guided Interventions

Obstetric Imaging

Imaging of the Spine

MUSCULOSKELETAL IMAGING

2nd EDITION

THOMAS L. POPE, Jr., MD, FACR

Consultant Radiologist and Vice Chairman
Radisphere National Radiology Group
Isle of Palms, South Carolina

HANS L. BLOEM, MD, PhD

Professor and Chairman
Department of Radiology
Leiden University Medical Center
Leiden, The Netherlands

JAVIER BELTRAN, MD, FACR

Chairman
Department of Radiology
Maimonides Medical Center
Brooklyn, New York
Clinical Director of Musculoskeletal Radiology
Radisphere National Radiology Group
Beachwood, Ohio

WILLIAM B. MORRISON, MD

Professor
Department of Radiology
Thomas Jefferson University
Director, Division of Musculoskeletal and General Diagnostic
Radiology
Thomas Jefferson University Hospital
Philadelphia, Pennsylvania

**DAVID J. WILSON, MBBS, BSc, MFSEM,
FRCR, FRCR**

Honorary Consultant Radiologist
Oxford University Hospitals
Senior Clinical Lecturer
University of Oxford
Consultant Radiologist
St. Lukes Hospital
Oxford, United Kingdom

ELSEVIER
SAUNDERS

Contributors

Faustino A. Abascal, MD

Department of Radiology
Diagnóstico Médico Cantabria
Santander, Spain
18 Soft Tissue Injuries of the Hand and Wrist

Judith E. Adams, MBBS, FRCR, FRCP

Clinical Radiology
Manchester Royal Infirmary & Manchester Academic Health
Science Centre
Manchester, Great Britain
77 Osteoporosis

Ronald S. Adler, MD, PhD

Professor of Radiology
NYU Langone Medical Center
Department of Radiology
New York, New York
12 Soft Tissue Injury to the Elbow
*35 Compressive and Entrapment Neuropathies of the Lower
Extremity*

Joong Mo Ahn, MD

Associate Professor
Department of Radiology
University of Pittsburgh Medical Center
Pittsburgh, Pennsylvania
40 Stress Injury

Jorge Albareda Albareda, MD

Jefe de Servicio de Traumatología y Ortopedia
Hospital Clínico Universitario
Zaragoza, Spain
22 Acute Osseous Injury to the Hip and Proximal Femur

Sana Ali, MD

Resident in Diagnostic Radiology
Department of Diagnostic Imaging
Maimonides Medical Center
Brooklyn, New York
13 Normal Wrist
82 Storage Diseases (Mucopolysaccharidoses and Glycogenoses)

Gina M. Allen, BM, MFSEM, MSc (SEM), MRCP, MRCP, FRCR

Consultant Radiologist
Oxford University Hospitals
Consultant Radiologist
St Lukes Radiology
St Lukes Hospital
Oxford, United Kingdom
73 Hemophilia and Related Disorders
91 The Patient with a Soft-Tissue Lump

Arash Anavim, MD

Assistant Clinical Professor and Residency Program Director
Radiological Sciences
University of California, Irvine
Orange, California
122 Discography

Mark W. Anderson, MD

Professor of Radiology and Orthopaedic Surgery
Department of Radiology
University of Virginia
Charlottesville, Virginia
116 Normal Variants

Suzanne E. Anderson, MD, PhD

Honorary Professor, Musculoskeletal Radiology
Department of Diagnostic, Interventional and Paediatric
Radiology
Inselpital, University of Berne
Berne, Switzerland
Associate Professor
Department of Radiology
University of Melbourne
Associate Professor
Department of Medicine
Royal Melbourne Hospital
Melbourne, Australia
42 Complications of Osseous Trauma

Francisco Aparisi, MD

Department of Radiology
Hospital Nueve de Octubre
Valencia, Spain
19 The Normal Pelvis and Hip
20 Acute Osseous Injury to the Pelvis and Acetabulum

Pilar Aparisi Gómez, MBChB, PQS Radiology, EFRANZCR

Consultant Radiologist
Department of Radiology
Hospital Nueve de Octubre
Valencia, Spain
Consultant Radiologist
Department of Radiology
Auckland Hospital
Auckland, New Zealand
20 Acute Osseous Injury to the Pelvis and Acetabulum

CONTRIBUTORS

Derek R. Armfield

Co-Founder, Vice Chairman, and President of Clinical Services
 Foundation Radiology, Inc.
 Vice Chairperson
 Department of Diagnostic Imaging
 Jefferson Regional Medical Center
 Pittsburgh, Pennsylvania
109 Postoperative Hip

Bridget Atkins, MA, MBBS, MSc, FRCPath, FRCP

Consultant, Infectious Diseases and Microbiology
 Oxford University Hospitals NHS Trust
 Consultant ID Physician (Hon), Bone Infection Unit
 Nuffield Orthopaedic Centre
 Senior Lecturer (Hon)
 The University of Oxford
 Training Programme Director
 Infectious Diseases and Microbiology
 Oxford Deanery
 Oxford, United Kingdom
64 Soft Tissue Infection: Cellulitis, Pyomyositis, Abscess, Septic Arthritis

Jonathan C. Baker, MD

Assistant Professor of Radiology
 Mallinckrodt Institute of Radiology
 Washington University School of Medicine
 St. Louis, Missouri
111 Postoperative Ankle and Foot

Lisa O. Ballehr, DO

Diagnostic Radiologist
 Arizona Advanced Imaging Center
 Mesa, Arizona
30 The Normal Ankle and Foot

Romulo Baltazar, MD

Attending Radiologist
 Imaging Subspecialists of North Jersey
 St. Joseph's Regional Medical Center
 Paterson, New Jersey
89 Drug-Related Bone and Soft Tissue Disorders

Laura Bancroft, MD

Chief of MSK Radiology
 Department of Radiology
 Florida Hospital
 Orlando, Florida
 Adjunct Professor
 University of Central Florida School of Medicine
 Orlando, Florida
 Clinical Professor
 Florida State University School of Medicine
 Tallahassee, Florida
113 Complications of Infection

Chad H. Barker, MD

Musculoskeletal Radiology Fellow
 Department of Radiology
 University of Kentucky
 Lexington, Kentucky
113 Complications of Infection

Michelle A. Barr, MD

Associate Professor of Radiology
 Department of Radiology
 University of Virginia
 Charlottesville, Virginia
121 Spinal Injections

Andrea Baur-Melnyk, MD

Associate Professor of Radiology
 Section Chief of Department of Clinical Radiology
 Ludwig Maximilian University of Munich-Grosshadern
 Munich, Germany
93 Myeloma

Francesca Beaman, MD

Assistant Professor of Radiology, Division Chief
 Musculoskeletal Radiology, Program Director
 Musculoskeletal Radiology Fellowship, Assistant Program
 Director Radiology Residency
 Department of Radiology
 University of Kentucky
 Lexington, Kentucky
113 Complications of Infection

Javier Beltran, MD, FACR

Chairman
 Department of Radiology
 Maimonides Medical Center
 Brooklyn, New York
 Clinical Director of Musculoskeletal Radiology
 Radisphere National Radiology Group
 Beachwood, Ohio
6 Normal Shoulder
12 Soft Tissue Injury to the Elbow
17 Compressive and Entrapment Neuropathies of the Upper Extremities
35 Compressive and Entrapment Neuropathies of the Lower Extremity
89 Drug-Related Bone and Soft Tissue Disorders

Luis S. Beltran, MD

Assistant Professor of Radiology
 Department of Radiology
 New York University Langone Medical Center
 New York, New York
17 Compressive and Entrapment Neuropathies of the Upper Extremity
35 Compressive and Entrapment Neuropathies of the Lower Extremity
88 Tuberos Sclerosus

Jenny T. Bencardino, MD

Associate Professor of Radiology
 New York University School of Medicine
 New York, New York
12 Soft Tissue Injury to the Elbow
17 Compressive and Entrapment Neuropathies of the Upper Extremity

Donna G. Blankenbaker, MD

Professor
Department of Radiology
University of Wisconsin School of Medicine and Public Health
Madison, Wisconsin
4 Cervical Spine Injuries

Hans L. Bloem, MD, PhD

Professor and Chairman
Department of Radiology
Leiden University Medical Center
Leiden, The Netherlands
65 Appendicular Infection
90 The Patient with a Tumor or a Tumor-Like Lesion of Bone
99 Staging Bone and Soft Tissue Tumors
100 Monitoring Therapy in Bone and Soft Tissue Tumors

Marcy B. Bolster, MD

Associate Professor of Medicine
Harvard Medical School
Division of Rheumatology
Massachusetts General Hospital
Boston, Massachusetts
48 Rheumatoid Arthritis

Peyman Borghei

Research Fellow
Diagnostic Radiology
University of California Irvine
Orange, California
122 Discography

Cedric Boulet, MD

Department of Radiology
Universitair Ziekenhuis Brussel
Brussels, Belgium
10 Normal Elbow

Patrick A. Brouwer, MD, MSc

Neurovascular Network NorthSea
Department of Radiology
Leiden University Medical Center
Leiden, The Netherlands
124 Percutaneous Intradiscal Therapies

Elliott Brown, MD

Assistant Professor
Department of Diagnostic Radiology
Yale University School of Medicine
New Haven, Connecticut
15 Internal Derangement of the Wrist

Ángel Bueno, MD

Hospital Universitario Fundación Alcorcón
Madrid, Spain
Appendix 3 Fractures with Names

Michele Calleja, MD, FRCR

Consultant Musculoskeletal Radiologist
Radiology Department
Royal National Orthopaedic Hospital
Stanmore, United Kingdom
103 Coalitions

Ana Canga, MD

Departments of Radiology and of Anatomy and Cellular
Biology
University of Cantabria
Marqués de Valdecilla University Hospital
Santander, Spain
18 Soft Tissue Injuries of the Hand and Wrist
34 Soft Tissue Injuries to the Ankle: Osteochondral Injuries and Impingement
103 Coalitions

Fabiano Nassar Cardoso, MD

Musculoskeletal Radiology Assistant
Department of Diagnostic Imaging
Universidade Federal de São Paulo—UNIFESP
São Paulo, Brazil
44 Complex Regional Pain Syndrome
71 General Principles of Magnetic Resonance Imaging of the Bone Marrow
72 Ischemic Bone Lesions

Victor Cassar-Pullicino, FRCR

Consultant Radiologist
Robert Jones and Agnes Hunt Orthopaedic Hospital
Oswestry, Shropshire
United Kingdom
66 Spinal Infection

Conrado Furtado de Albuquerque Cavalcanti, MD

Section Chief, MRI Imaging
Hospital Sírio-Libanês
São Paulo, Brazil
44 Complex Regional Pain Syndrome

Luis Cerezal, MD

Head
Radiology Department
Diagnóstico Médico Cantabria (DMC)
Santander, Spain
18 Soft Tissue Injuries of the Hand and Wrist
34 Soft Tissue Injury to the Ankle: Osteochondral Injuries and Impingement

Russell W. Chapin, MD

Assistant Professor
Department of Radiology and Radiological Sciences
Medical University of South Carolina
Charleston, South Carolina
37 Lower Extremity Injuries in Children

Qi Chen, MD

Department of Radiology
SUNY Downstate Medical Center
Brooklyn, New York
6 Normal Shoulder

Yvonne Y. Cheung, MD, MS

Associate Professor of Radiology
Dartmouth Hitchcock Medical Center
Dartmouth Medical School
Lebanon, New Hampshire
32 Soft Tissue Injury to the Ankle: Ligament Injuries

Aaron Cho, MD

Staff Neuroradiologist
 Department of Radiology
 Naval Medical Center San Diego
 San Diego, California
Appendix 2 Orthopedic Devices

Kishore K. Chundru, MD candidate

Radiology Resident
 St. Luke's-Roosevelt Hospital
 New York, New York
80 Pituitary and Thyroid Disorders

Usha Chundru, MD, MBA

Staff Radiologist
 Department of Radiology
 Maimonides Medical Center
 Brooklyn, New York
28 Internal Derangement of the Knee: Tendon Injuries

Christine B. Chung, MD

Associate Professor of Radiology
 University of California School of Medicine
 Professor of Radiology
 Veterans Affairs Medicine Center
 San Diego, California
108 Postoperative Elbow, Wrist, and Hand

Claire Coggins, MD

Owner
 Claire Coggins, MD P.A.
 Subspecialty Musculoskeletal Radiology
 Wilmington, DE
58 Ochronosis
59 Diffuse Idiopathic Skeletal Hyperostosis and Ossification of the Posterior Longitudinal Ligament

Antonio Cruz, MD

Department of Arthroscopic Surgery
 Hospital Mutua Montañesa
 Santander, Spain
34 Soft Tissue Injury to the Ankle: Osteochondral Injuries and Impingement

Christian Czerny, MD

Department of Radiology
 General Hospital and Medical University of Vienna
 Vienna, Austria
23 Internal Derangement of the Hip and Proximal Femur

Richard H. Daffner, MD, FACR

Emeritus Clinical Professor of Radiology
 Temple University School of Medicine
 Department of Diagnostic Radiology
 Allegheny General Hospital
 Pittsburgh, Pennsylvania
4 Cervical Spine Injuries

Melvin D'Anastasi, MD

Institute for Clinical Radiology
 Ludwig Maximilian University of Munich-Grosshadern
 Munich, Germany
93 Myeloma

A. Mark Davies, MBChB, DMRD, FRCR

Consultant Radiologist
 Department of Imaging
 Royal Orthopaedic Hospital,
 Birmingham, United Kingdom
92 Primary Bone Tumors
94 Tumor-Like Lesions of Bone

Kirkland W. Davis, MD

Section Chief
 Musculoskeletal Imaging and Intervention
 Department of Radiology
 University of Wisconsin School of Medicine and Public Health
 Madison, Wisconsin
4 Cervical Spine Injuries
106 Principles and Complications of Orthopedic Hardware

Milko C. de Jonge, MD, BSc

Department of Radiology
 Zuwe Hofpoort Hospital
 Woerden, The Netherlands
 Department of Plastic, Reconstructive, and Hand Surgery
 Academic Medical Center
 University of Amsterdam
 Amsterdam, The Netherlands
5 Injury of the Thoracic Cage and Thoracolumbar Spine

Michel O. De Maeseneer, MD, PhD

Professor of Radiology
 University Hospital Brussels
 Brussels, Belgium
24 Normal Knee

†Arthur De Schepper, Sr., MD, PhD

Professor of Radiology
 University Hospital Antwerp
 Antwerp University
 Antwerp, Belgium
 Department of Radiology
 Leiden University Medical Center
 The Netherlands
95 Soft Tissue Tumors
96 Tumor-Like Soft Tissue Lesions

José Luis del Cura, MD, PhD

Associate Professor
 Surgery, Radiology, and Physical Medicine
 Basque Country University
 Department of Radiology
 Hospital de Baurto-Basurtoko Ospitalea
 Bilbao, Spain
Appendix 1 Measurements Most Frequently Used in Orthopedic Imaging

Bradley N. Delman, MD

Associate Professor
 Department of Radiology
 Icahn School of Medicine at Mount Sinai
 New York, New York
3 Imaging of Facial and Skull Trauma

†Deceased.

Sachin Dheer, MD

Director, Musculoskeletal Imaging and Intervention
 Department of Radiology
 Kennedy Health System
 Cherry Hill, New Jersey
60 Gout

Grégory Dieudonné, MD

Assistant Professor
 Departments of Imaging Sciences and Orthopedics
 University of Rochester School of Medicine and Dentistry
 Strong Memorial Hospital
 Rochester, New York
9 Glenohumeral Instability

Joseph Dobtsis, MD

Director of Neuroradiology and Musculoskeletal Radiology
 21st Century Radiology
 Brooklyn, New York
80 Pituitary and Thyroid Disorders
118 Percutaneous Biopsy of the Appendicular Skeleton
119 Percutaneous Biopsy of the Spine

Brendan T. Doherty, MD

Division of Musculoskeletal and General Diagnostic Radiology
 Thomas Jefferson Hospital
 Philadelphia, Pennsylvania
1 General Imaging Principles
63 Non-Inflammatory Intraarticular Pathology

Rodrigo Dominguez, MD

Professor of Radiology, Retired
 Maimonides Medical Center
 Brooklyn, New York
80 Pituitary and Thyroid Disorders
82 Storage Diseases (Mucopolysaccharidoses and Glycogenoses)

Davide Maria Donati, MD

Professor
 University of Bologna
 Head of the III Clinic Unit
 Rizzoli Orthopaedic Institute
 Bologna, Italy
98 Treatment Strategies for Musculoskeletal Tumors and Tumor-Like Lesions

Seema Döring, MD

Department of Radiology
 Universitair Ziekenhuis Brussel
 Brussels, Belgium
10 Normal Elbow

Nimisha Dorshi, MD

Resident of Diagnostic Radiology
 Department of Diagnostic Imaging
 Maimonides Medical Center
 Brooklyn, New York
82 Storage Diseases (Mucopolysaccharidoses and Glycogenoses)

Hassan Douis, MD, MRCP

Clinical Fellow in Musculoskeletal Radiology
 Department of Radiology
 The Royal National Orthopaedic Hospital NHS Trust
 Stanmore, United Kingdom
92 Primary Bone Tumors
94 Tumor-Like Lesions of Bone

Aija Dzirkale, MD

Radiology Center
 Riga East University Hospital
 Riga, Latvia
107 Postoperative Shoulder

Georges Y. El-Khoury, MD, FACR

Professor of Radiology and Orthopaedics
 University of Iowa Carver College of Medicine
 Director, Section of Musculoskeletal Radiology
 University of Iowa Hospitals and Clinics
 Iowa City, Iowa
40 Stress Injury

Ilze Enģele, MD

Department of Radiology
 Riga Stradins University
 Riga East University Hospital
 Riga, Latvia
57 Hemochromatosis
85 Paget Disease

Ana M. Hualde Enguita, MD

Servicio de Traumatología y Ortopedia
 Hospital Universitario Miguel Servet
 Zaragoza, Spain
22 Acute Osseous Injury to the Hip and Proximal Femur

Mara Epermane, MD

Chief
 Radiology Center
 Riga East University Hospital
 Riga, Latvia
85 Paget Disease

Christopher J. Fang, MBBCh, FRCR

Musculoskeletal Radiologist
 Department of Clinical Radiology
 Royal Derby Hospital
 Derby, United Kingdom
73 Hemophilia and Related Disorders

Laura M. Fayad, MD

Associate Professor of Radiology, Orthopaedic Surgery, and Oncology
 Director of Translational Research for Advanced Imaging
 The Russell H. Morgan Department of Radiology and Radiological Science
 Johns Hopkins University School of Medicine
 Baltimore, Maryland
112 Imaging of the Residual Limb after Amputation

CONTRIBUTORS

Steven Finden, MD, DDS

Department of Radiology
Thomas Jefferson University Hospital
Philadelphia, Pennsylvania
114 Temporomandibular Joint

Donald J. Flemming, MD

G. Victor Rohrer Professor of Radiology Education
Professor of Radiology and Orthopedics
Penn State Hershey Medical Center
Hershey, Pennsylvania
97 Metastatic Disease

Jürgen Freyschmidt, MD

Professor
Consulting Center for Skeletal Radiology
Central Hospital Bremen-Mitte
Bremen, Germany
49 Psoriatic Arthritis and Psoriatic Spondyloarthropathy
52 Progressive Scleroderma

Jan L. Gielen, MD

Department of Radiology
Antwerp University Hospital
Antwerp, Belgium
96 Tumor-Like Soft Tissue Lesions

Angela Gessner Gopez, MD, BS

Assistant Professor of Radiology
Department of Radiology
Jefferson Medical College
Thomas Jefferson University Hospital
Philadelphia, Pennsylvania
Appendix 2 Orthopedic Devices

Tetyana Gorbachova, MD

Clinical Assistant Professor
Department of Radiology
Albert Einstein Medical Center
Philadelphia, Pennsylvania
81 Gaucher Disease

Andrew J. Grainger, BM BS, MRCP, FRCR

Consultant and Honorary Senior Lecturer
Department of Musculoskeletal Radiology
Leeds Teaching Hospitals
Leeds, United Kingdom
43 Muscle Injury and Sequelae

Andrew H. Haims, MD

Associate Professor
Departments of Diagnostic Radiology and Orthopaedics and
Rehabilitation
Co-Director, Musculoskeletal Imaging
Yale University School of Medicine
New Haven, Connecticut
15 Internal Derangement of the Wrist

Joseph Hanono, MD

Radiology Resident
Maimonides Medical Center
Brooklyn, New York
118 Percutaneous Biopsy of the Appendicular Skeleton
119 Percutaneous Biopsy of the Spine

Faye N. Hant, DO, MSCR

Assistant Professor of Medicine
Division of Rheumatology and Immunology
Medical University of South Carolina
Charleston, South Carolina
48 Rheumatoid Arthritis

John H. Harris, Jr., MD, DSc

Professor Emeritus
Department of Diagnostic and Interventional Radiology
The University of Texas Medical School at Houston
Houston, Texas
2 General Principles of Osseous Injury

Curtis W. Hayes, MD, FACR

Professor of Radiology and Orthopedic Surgery
Department of Radiology
Virginia Commonwealth University Health System
Richmond, Virginia
58 Ochronosis
59 Diffuse Idiopathic Skeletal Hyperostosis and Ossification of the Posterior Longitudinal Ligament

Tamara Miner Haygood, PhD, MD

Associate Professor
Department of Diagnostic Radiology
University of Texas M.D. Anderson Cancer Center
Houston, Texas
41 Radiation Effects in the Musculoskeletal System

Victoria Higuera, MD

Department of Radiology
Hospital de la Ribera
Alzira, Valencia
Spain
20 Acute Osseous Injury to the Pelvis and Acetabulum

Siegfried Hofmann, MD, PhD

Associate Professor of Orthopaedic Surgery
General and Orthopedic Clinic–Stolzalpe
Stolzalpe, Austria
23 Internal Derangement of the Hip and Proximal Femur

Peter Hrehorovich, MD

Radiologist
Florida Hospital Heartland Medical Center
Sebring, Florida
14 Acute Osseous Injury to the Wrist
16 Acute Osseous Trauma to the Hand

Maya Sardjono Hsieh, BS, MD

Department of Radiology
Maimonides Medical Center
Brooklyn, New York
28 Internal Derangement of the Knee: Tendon Injuries

Wouter C.J. Huyse, MD

Musculoskeletal Radiologist
 Department of Radiology
 Ghent University Hospital
 Ghent, Belgium
29 Internal Derangement of the Knee: Cartilage and Osteochondral Injuries

Hakan Ilaslan, MD

Associate Professor
 Department of Radiology
 Cleveland Clinic Lerner College of Medicine
 Cleveland, Ohio
87 Sarcoidosis

Karsten Jablonka, MD

Department of Pediatric Radiology
 University of Giessen
 Giessen, Germany
 Head, Department of Pediatric Radiology
 Klinikum Bremen-Mitte
 Bremen, Germany
49 Psoriatic Arthritis and Psoriatic Spondyloarthropathy
52 Progressive Scleroderma

Neda Jafarian, MD

Resident Physician
 Department of Radiology
 Maimonides Medical Center
 Brooklyn, New York
8 Shoulder Impingement Syndromes

Steven L.J. James, MBChB, FRCR

Consultant Musculoskeletal Radiologist
 Department of Imaging
 The Royal National Orthopaedic Hospital NHS Trust
 Birmingham, United Kingdom
92 Primary Bone Tumors
94 Tumor-Like Lesions of Bone

Ann M. Johnson, MD

Associate Professor of Clinical Radiology
 Perelman School of Medicine at the University of Pennsylvania
 Children's Hospital of Philadelphia
 Philadelphia, Pennsylvania
38 Upper Extremity Injuries in Children

Karl Johnson, BSC, MB ChB, MRCP, FRCR

Radiologist
 Birmingham Children's Hospital
 Birmingham, United Kingdom
55 Juvenile Idiopathic Arthritis

Maria Bernadette Johnson, MBChB, FRCR

Consultant Musculoskeletal Radiologist
 Ealing Hospital
 London, United Kingdom
43 Muscle Injury and Sequelae

Apostolos Karantanas, MD, PhD

Associate Professor of Radiology
 University of Crete
 Chairman
 Department of Medical Imaging
 University Hospital
 Heraklion, Greece
75 Thalassemia

Theodoros F. Katsivas, MD

Assistant Professor
 Department of Medicine
 Division of Infectious Diseases
 San Diego, California
69 HIV Infection and AIDS

Eoin C. Kavanagh, FRR, RCSI, FRCPI

UCD Associate Clinical Professor
 Consultant Radiologist
 Mater Misericordiae University Hospital
 Cappagh National Orthopaedic Hospital
 Dublin, Ireland
76 Myelofibrosis
109 Postoperative Hip

[†]Theodore E. Keats, MD

Alumni Professor
 Department of Radiology
 University of Virginia
 Professor of Radiology
 University of Virginia Health Sciences
 Charlottesville, Virginia
116 Normal Variants

Shah H.M. Khan, MB BS, FRCR, MSK DIP (ESSR)

Consultant Radiologist
 Department of Radiology
 East Lancashire Hospitals NHS Trust, Blackburn
 Senior Clinical Lecturer
 Department of Radiology
 University of Central Lancashire
 Preston, United Kingdom
65 Appendicular Infection

Valeriy Kheyfits, MD

Assistant Professor
 Department of Imaging Sciences
 University of Rochester School of Medicine and Dentistry
 Strong Memorial Hospital
 Rochester, New York
9 Glenohumeral Instability

Gabrielle P. Konin, MD

Assistant Professor
 Department of Radiology and Imaging
 Weill Cornell Medical College
 Assistant Attending Radiologist
 Hospital for Special Surgery
 New York, New York
67 Diabetic Pedal Infection

[†]Deceased.

CONTRIBUTORS

George Koulouris, MBBS, GrCertSpMed, MMed(Radiology), FRANZCR
 Radiologist
 Melbourne Radiology Clinic
 Melbourne, Australia
109 Postoperative Hip

Josef Kramer, MD, PhD, MSc
 Roentgeninstitut am Schillerpark
 Linz, Austria
23 Internal Derangement of the Hip and Proximal Femur

Mark J. Kransdorf, MD
 Department of Radiology
 Mayo Clinic
 Phoenix, Arizona
117 Biopsy: Soft Tissue

Herman M. Kroon, MD
 Radiologist, Department of Radiology
 Department of Radiology
 Leiden University Medical Center
 Leiden, The Netherlands
90 The Patient with a Tumor or a Tumor-Like Lesion of Bone
99 Staging Bone and Soft Tissue Tumors

Dylan C. Kwait, MD
 Radiologist
 Department of Diagnostic Imaging
 Maimonides Medical Center
 Brooklyn, New York
13 Normal Wrist

Radhesh Lalam, MBBS, MRCS, FRCR
 Consultant Radiologist
 Department of Diagnostic Radiology
 The Robert Jones and Agnes Hunt Orthopaedic and District Hospital NHS Foundation Trust
 Oswestry, Shropshire
 United Kingdom
45 Degenerative Disorders of the Spine

Susanne W.Y. Lardenoije, MD
 Department of Radiology
 Radboud University Medical Center
 Nijmegen, the Netherlands
39 Skeletal Manifestations of Pediatric Nonaccidental Injury

Hans P. Ledermann, MD
 IMAMED Radiologie Nordwest
 Basel, Switzerland
67 Diabetic Pedal Infection

Scott S. Lenobel, MD
 Clinical Instructor
 Department of Radiology
 The Ohio State University Wexner Medical Center
 Columbus, Ohio
7 Osseous Injuries of the Shoulder Girdle

Brandon Y. Liu, MD
 Diagnostic Radiologist
 Department of Medical Imaging
 Swedish Medical Center
 Radia Medical Imaging, Inc.
 Everett, Washington
11 Acute Osseous Injury of the Elbow and Forearm

Eva Llopis, MD
 Coordinator, Musculoskeletal Section
 Servicio de Radiología
 Hospital Universitario de la Ribera
 Valencia, Spain
18 Soft Tissue Injuries of the Hand and Wrist
19 The Normal Pelvis and Hip
20 Acute Osseous Injury to the Pelvis and Acetabulum
22 Acute Osseous Injury to the Hip and Proximal Femur

Bart Loeys, MD, PhD
 Professor of Clinical Genetics
 Center for Medical Genetics
 Antwerp University Hospital/University of Antwerp,
 Antwerp, Belgium
84 Marfan Syndrome

Chika Iloanusi Logie, MD
 Senior Scientist and Associate Editor
 Musculoskeletal Imaging
 American Institute for Radiologic Pathology
 Silver Spring, Maryland
 Adjunct Assistant Professor
 Departments of Radiology and Radiological Sciences
 Uniformed Services University of the Health Sciences
 Bethesda, Maryland
79 Amyloidosis
86 Hypertrophic Osteoarthropathy

Niamh M. Long, MB, BCh, BAO
 Department of Radiology
 Mater Misericordiae University Hospital
 Dublin, Ireland
76 Myelofibrosis
109 Postoperative Hip

Calvin Ma, MD
 Staff Radiologist
 Sutter Imaging, Musculoskeletal Section
 Sutter Health Systems
 Sacramento, California
17 Compressive and Entrapment Neuropathies of the Upper Extremity
35 Compressive and Entrapment Neuropathies of the Lower Extremity
80 Pituitary and Thyroid Disorders
82 Storage Diseases (Mucopolysaccharidoses and Glycogenoses)

Jacques Malghem, MD
 Professor of Radiology
 Université Catholique Louvain
 Cliniques Universitaires Saint-Luc
 Brussels, Belgium
72 Ischemic Bone Lesions

Natalia Marks, MD

Radiologist
Department of Diagnostic Imaging
Maimonides Medical Center
Brooklyn, New York
13 Normal Wrist

José Martel, MD, PhD

Diagnóstico por Imagen
Hospital Universitario Fundación Alcorcón
Madrid, Spain
Appendix 3 Fractures with Names

Manesh Mathew, MD

Attending Radiologist
Altoona Regional Medical Center
Altoona, Pennsylvania
14 Acute Osseous Injury to the Wrist
16 Acute Osseous Trauma to the Hand

Iain W. McCall, MD, NIB, ChB, FRCR

Professor of Radiologic Sciences (retired)
Keele University
Honorary Consultant Radiologist
Department of Radiology
University Hospital of North Staffordshire
Stoke on Trent, North Staffordshire
Consultant Radiologist
Department of Radiology
The Robert Jones and Agnes Hunt Orthopaedic Hospital NHS
Foundation Trust
Shropshire, United Kingdom
45 Degenerative Disorders of the Spine

Eugene McNally, MD, BCh, BAO, FRCR, FRCPI

Consultant Musculoskeletal Radiologist
Department of Radiology
Nuffield Orthopaedic Centre
Honorary Senior Lecturer
Nuffield Department of Orthopaedic Surgery
Oxford University Hospital
Oxford, United Kingdom
27 Internal Derangement of the Knee: Ligament Injuries

José M. Mellado Santos, MD

Servicio de Radiología
Hospital Reina Sofía
Tudela, Navarra
Spain
20 Acute Osseous Injury to the Pelvis and Acetabulum
22 Acute Osseous Injury to the Hip and Proximal Femur

Kirsten A. Menn, MD

Clinical Fellow
Division of Pediatric Radiology
Yale New Haven Hospital
New Haven, Connecticut
68 Pediatric Infections

Theodore T. Miller, MD, FACR

Professor of Radiology
Weill Medical College of Cornell University
Attending Radiologist
Department of Radiology and Imaging
Hospital for Special Surgery
New York, New York
6 Normal Shoulder
10 Normal Elbow
28 Internal Derangement of the Knee: Tendon Injuries

Douglas N. Mintz, MD

Associate Attending Radiologist
Hospital for Special Surgery
Associate Professor of Clinical Radiology
Weill College of Medicine
Cornell University
New York, New York
110 Postoperative Knee

Johnny U.V. Monu, MBBS, MSc

Professor of Imaging Sciences and Orthopedics
Department of Imaging Sciences
University of Rochester
Rochester, New York
46 Aging
48 Rheumatoid Arthritis
55 Juvenile Idiopathic Arthritis
61 Crystal-Related Arthritis

Sandra Moore, MD

Assistant Professor
Department of Radiology
New York University School of Medicine
NYU Langone Medical Center
New York, New York
62 Neuropathic Osteoarthropathy
69 HIV Infection and AIDS

Morcos Morcos, MD

Diagnostic Radiologist
Department of Radiology
Maimonides Medical Center
Brooklyn, New York
13 Normal Wrist

William B. Morrison, MD

Professor of Radiology
Thomas Jefferson University
Director, Division of Musculoskeletal and General Diagnostic
Radiology
Thomas Jefferson University Hospital
Philadelphia, Pennsylvania
1 General Imaging Principles
63 Non-Inflammatory Intraarticular Pathology
67 Diabetic Pedal Infection

Geert R. Mortier, MD

Professor of Clinical Genetics
University Hospital Antwerp
University Antwerp and Ghent, Belgium
101 Focal Growth Disturbances

Timothy J. Mosher, MD, MS

Distinguished Professor of Radiology and Orthopaedics
Kenneth L. Miller Chair of Radiology
Department of Radiology
Penn State University College of Medicine
Department of Radiology
Penn State University Hospital
Hershey, Pennsylvania
47 Degenerative Disease: Physiology and Advanced Imaging

Michael E. Mulligan, MD

Professor of Diagnostic Radiology and Nuclear Medicine
University of Maryland School of Medicine
Baltimore, Maryland
97 Metastatic Disease

Mark D. Murphey, MD, FACR

Professor of Radiology
Uniformed Services University of the Health Sciences
Staff Radiologist
Musculoskeletal Section
Department of Radiology
Walter Reed National Military Medical Center
Bethesda, Maryland
79 Amyloidosis
86 Hypertrophic Osteoarthropathy
97 Metastatic Disease

William A. Murphy, Jr., MD

Professor of Diagnostic Radiology
University of Texas M.D. Anderson Cancer Center
Houston, Texas
41 Radiation Effects in the Musculoskeletal System

Anna Nazarenko, MD

Staff Radiologist
Department of Radiology
Maimonides Medical Center
Brooklyn, New York
8 Shoulder Impingement Syndromes

Elina Neilande, MD

Radiology Center
Riga East University Hospital
Riga, Latvia
31 Acute Osseous Injury to the Ankle and Foot

Daniel B. Nissman, MD, MPH, MSEE

Clinical Assistant Professor
Department of Radiology
University of North Carolina School of Medicine
Chapel Hill, North Carolina
50 Reactive Arthritis

Amaka C. Offiah, BSc, MBBS, PhD

HEFCE Clinical Senior Lecturer
Academic Unit of Child Health
University of Sheffield
Honorary Consultant Paediatric Radiologist
Radiology
Sheffield Children's Hospital
Sheffield, United Kingdom
104 Dysplasias

Richard Oh, MD

Diagnostic Radiologist
University of Colorado Hospital
Anschutz Medical Campus
Aurora, Colorado
16 Acute Osseous Trauma to the Hand

Imran M. Omar, MD

Chief, Musculoskeletal Radiology
Department of Radiology
Northwestern University Feinberg School of Medicine
Chicago, Illinois
Appendix 5 Classic Signs and Findings in Musculoskeletal Radiology

Patrick Omoumi, MD

Department of Radiology
Cliniques Universitaires Saint-Luc
Université Catholique de Louvain
Brussels, Belgium
Department of Radiology
Centre Hospitalo-Universitaire de Tours
Tours, France
71 General Principles of Magnetic Resonance Imaging of the Bone Marrow
72 Ischemic Bone Lesions

Oleg Opsha, MD

Chief of Musculoskeletal Division
Department of Radiology
Maimonides Medical Center
Brooklyn, New York
8 Shoulder Impingement Syndromes
Appendix 4 Diseases with Names

Simon Ostlere, FRCR

Consultant Radiologist
Department of Radiology
Nuffield Orthopaedic Centre
Oxford, United Kingdom
103 Coalitions

Joshua Owen, MD

Assistant Professor of Radiology
Division of Musculoskeletal Radiology
Saint Louis University School of Medicine
St. Louis, Missouri
16 Acute Osseous Trauma to the Hand

Mario Padron, MD

Chief
Department of Radiology
Clinica CEMTRO
Madrid, Spain
6 Normal Shoulder

Narayan Babu Paruchuri, MD

Radiology Attending
Doshi Diagnostics
New York, New York
107 Postoperative Shoulder

Christian W.A. Pfirrmann, MD, MBA

Chief, Department of Radiology
 Deputy Medical Director
 Orthopedic University Hospital Balgrist
 Director Quality Management
 University Hospital Balgrist
 Zurich, Switzerland
23 Internal Derangement of the Hip and Proximal Femur

Michael J. Pharoah, DDS, MSc, FRCD(C)

Professor and Head of Oral Radiology
 Faculty of Dentistry
 University of Toronto
 Staff Radiologist
 Department of Dentistry
 Princess Margaret Hospital
 Consultant
 Department of Diagnostic Imaging
 Toronto General Hospital
 Toronto, Ontario, Canada
115 Dental Imaging

Marc J. Philippon, MD

Orthopedic Surgeon
 Steadman Hawkins Clinic
 Vail, Colorado
109 Postoperative Hip

Thomas L. Pope, Jr., MD, FACR

Consultant Radiologist and Vice Chairman
 Radisphere National Radiology Group
 Isle of Palms, South Carolina
2 General Principles of Osseous Injury
50 Reactive Arthritis
74 Sickle Cell Anemia
110 Postoperative Knee
116 Normal Variants

Linda Probyn, BScPT, MD, FRCPC

Assistant Professor and Vice-Chair Education
 Department of Medical Imaging
 University of Toronto
 Division of Musculoskeletal Imaging
 Sunnybrook Health Sciences Centre
 Toronto, Ontario, Canada
26 Internal Derangement of the Knee: Meniscal Injuries

Steven Raeymaeckers, MD

Department of Radiology
 Universitair Ziekenhuis Brussel
 Brussels, Belgium
10 Normal Elbow

James J. Rankine, MB ChB, MRCP, MRaD, FRCR, MD

Consultant Radiologist and Honorary Clinical Associate
 Professor
 Department of Radiology
 Leeds General Infirmary
 Leeds, United Kingdom
105 Spinal Deformity

Anil G. Rao, MD

Assistant Professor of Pediatric Radiology
 Department of Radiology and Radiological Science
 Medical University of South Carolina
 Charleston, South Carolina
37 Lower Extremity Injuries in Children

Nisha Rao, MD

Assistant Professor
 Departments of Radiology and Orthopedics
 University of South Florida College of Medicine
 Tampa, Florida
14 Acute Osseous Injury to the Wrist

Lisa G. Rider, MD

Deputy Chief
 Environmental Autoimmunity Group
 National Institute of Environmental Health Sciences
 National Institutes of Health
 Bethesda, Maryland
56 Idiopathic Inflammatory Myopathy

Catherine C. Roberts, MD

Professor of Radiology
 Mayo Clinic
 Phoenix, Arizona
117 Biopsy: Soft Tissue

Philip Robinson, MB, ChB, MRCP FRCR

Physician
 Chapel Allerton X-Ray
 Leeds Teaching Hospitals
 Leeds, United Kingdom
21 Pubalgia

Lee F. Rogers, MD

Professor
 Department of Medical Imaging
 University of Arizona College of Medicine
 Diagnostic Radiologist
 Musculoskeletal Section
 University Medical Center
 Tucson, Arizona
Foreword
60 Gout

Alejandro U. Rolón, MD

Department of Radiology
 Centro Diagnóstico Imaxe
 Buenos Aires, Argentina
18 Soft Tissue Injuries of the Hand and Wrist
34 Soft Tissue Injury to the Ankle: Osteochondral Injuries and Impingement

Lorne Rosenbloom, MDCM, FRCP(C)

Assistant Professor
 Department of Diagnostic Radiology
 McGill University Faculty of Medicine
 Montreal, Quebec
 Canada
3 Imaging of Facial and Skull Trauma

Daniel I. Rosenthal, MD

Professor of Radiology
Harvard Medical School
Chairman and Division Head
Department of Radiology
Massachusetts General Hospital
Boston, Massachusetts
81 Gaucher Disease

David A. Rubin, MD, FACP

Professor of Radiology
Washington University School of Medicine
Section Head
Musculoskeletal Radiology
Mallinckrodt Institute of Radiology
St. Louis, Missouri
111 Postoperative Ankle and Foot

Rodrigo A. Salgado, MD

Department of Radiology
Antwerp University Hospital
Antwerp, Belgium
96 Tumor-Like Soft Tissue Lesions

Barry Schenk, MD

Radiologist
Slingeland Ziekenhuis
Doetinchem, The Netherlands
124 Percutaneous Intradiscal Therapies

Anna Scheurecker, MD

Roentgeninstitut am Schillerpark
Linz, Austria
23 Internal Derangement of the Hip and Proximal Femur

Jean Schils, MD

Section Head, Musculoskeletal Radiology
Department of Diagnostic Radiology
Cleveland Clinic Lerner College of Medicine
Cleveland, Ohio
78 Hyperparathyroidism, Renal Osteodystrophy, Osteomalacia, and Rickets

Corinna Schorn, MD

Leitung Roentgeninstitut
Acura Kliniken Rheumakrankenhaus
Bad Kreuznach, Germany
51 Ankylosing Spondylitis
53 Systemic Lupus Erythematosus
54 Mixed Connective Tissue Disease

Andreas Schwarting, MD

Director of Rheumatology and Clinical Immunology
First Medical Clinic
Johannes Gutenberg University
Mainz, Germany
Medical Director
Sana Rheumazentrum Rhineland-Palatinate
Bad Kreuznach, Germany
53 Systemic Lupus Erythematosus
54 Mixed Connective Tissue Disease

Mark E. Schweitzer, MD, FRCPC

Professor and Chair
Department of Radiology
Stony Brook University School of Medicine
Stony Brook, New York
44 Complex Regional Pain Syndrome

Jon K. Sekiya, MD

Associate Professor
Associate Medical Director, MedSport
Department of Orthopaedic Surgery
University of Michigan
Ann Arbor, Michigan
109 Postoperative Hip

Maryam Shahabpour, MD

Chief, Musculoskeletal Imaging Clinic
Department of Radiology
Universitair Ziekenhuis Brussel
Clinical Professor of Radiology
Department of Medical imaging
Vrije Universiteit Brussel
Brussels, Belgium
10 Normal Elbow
24 Normal Knee

Prashant V. Shankar, MD

Resident in Diagnostic Radiology
Department of Radiology
University of North Carolina School of Medicine
Chapel Hill, North Carolina
50 Reactive Arthritis

Steven Shankman, MD

Vice-Chairman
Department of Radiology
Maimonides Medical Center
Brooklyn, New York
11 Acute Osseous Injury of the Elbow and Forearm
118 Percutaneous Biopsy of the Appendicular Skeleton
119 Percutaneous Biopsy of the Spine
Appendix 4 Diseases with Names

Roger Smith, MA, MD, FRCP

Honorary Consultant Physician
Department of Metabolic Medicine
Nuffield Orthopaedic Centre
Oxford, United Kingdom
83 Osteogenesis Imperfecta

Annemie Snoeckx, MD

Department of Radiology
University Hospital Antwerp
Antwerp, Belgium
84 Marfan Syndrome

Travis G. Snyder, MD

Radiologist
Utah Imaging Associates
Bountiful, Utah
15 Internal Derangement of the Wrist