

# WRIST-ANKLE ACUPUNCTURE 腕踝针

---

Zhou Qinghui Ling Changquan Zhang Xinshu  
周庆辉 凌昌全 张心曙 著



PUBLISHING HOUSE OF SHANGHAI  
UNIVERSITY OF TRADITIONAL  
CHINESE MEDICINE  
上海中医药大学出版社

# Wrist-Ankle Acupuncture

腕 踝 针

Zhou Qinghui  
Ling Changquan  
Zhang Xinshu

周庆辉 凌昌全 张心曙 著

**PUBLISHING HOUSE OF SHANGHAI  
UNIVERSITY OF TRADITIONAL  
CHINESE MEDICINE**  
上海中医药大学出版社

Publishing House of Shanghai University of Traditional Chinese Medicine  
530 Lingling Road, Shanghai, China

Wrist-Ankle Acupuncture

Zhou Qinghui, Ling Changquan and Zhang Xinshu

ISBN 7-81010-661-9

Copyright © 2002 by Publishing House of Shanghai University of Traditional Chinese Medicine. All rights reserved.

No part of this publication may be reproduced without prior written permission from the publisher.

责任编辑 李照国  
技术编辑 徐国民  
责任校对 黄国琪  
封面设计 王磊  
出版人 朱邦贤

### 图书在版编目 (C I P) 数据

腕踝针 = Wrist-Ankle Acupuncture / 周庆辉, 凌昌全, 张心曙著. —上海: 上海中医药大学出版社, 2002

ISBN 7-81010-661-9

I. 腕... II. ①周... ②凌... ③张... III. 腕踝针  
— 针刺疗法 — 英文 IV. R245.31

中国版本图书馆 CIP 数据核字 (2002) 第 019974 号

腕 踝 针

周庆辉 凌昌全 张心曙 著

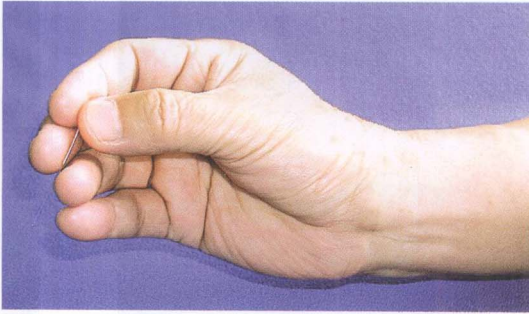
---

上海中医药大学出版社出版发行 (中国上海零陵路 530 号 邮政编码 200032)  
新华书店上海发行所经销 中国江苏省丹阳市教育印刷厂印刷  
开本 850 × 1168 1/32 印张 7.625 插页 8 字数 178 千字  
版次 2002 年 5 月第 1 版 印次 2002 年 5 月第 1 次印刷 印数 1 - 1500 册

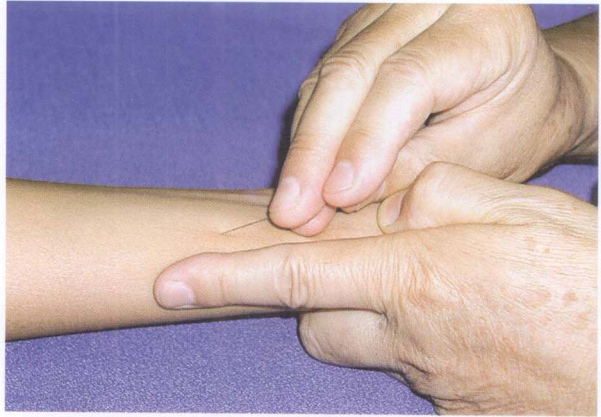---

ISBN 7-81010-661-9/R·627

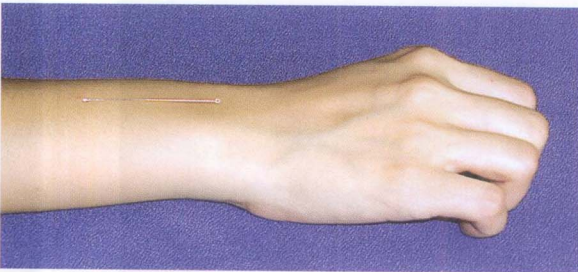
定价 46.90 元



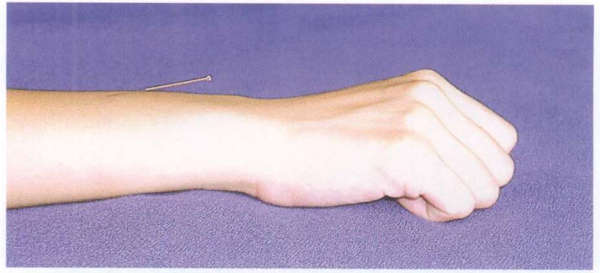
1. Posture of holding the needle.



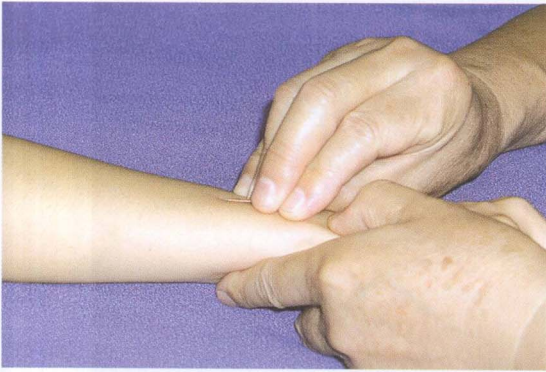2. Penetration of the skin by the tip of the needle, with an angle of 30 degree.



3. Release the needle after initial penetration, the body of the needle should lie flat on the skin surface without any angle (correct).

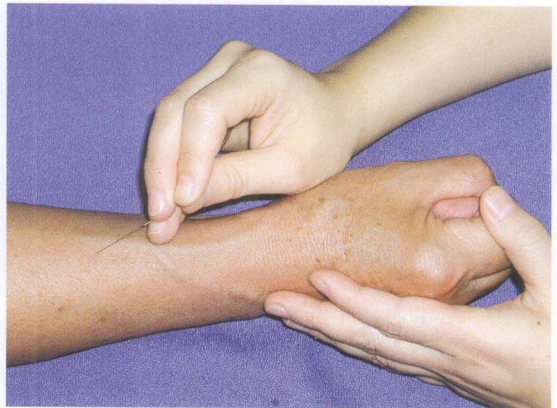

4. If there is an angle, it indicates that the penetration has gone too deep (wrong).

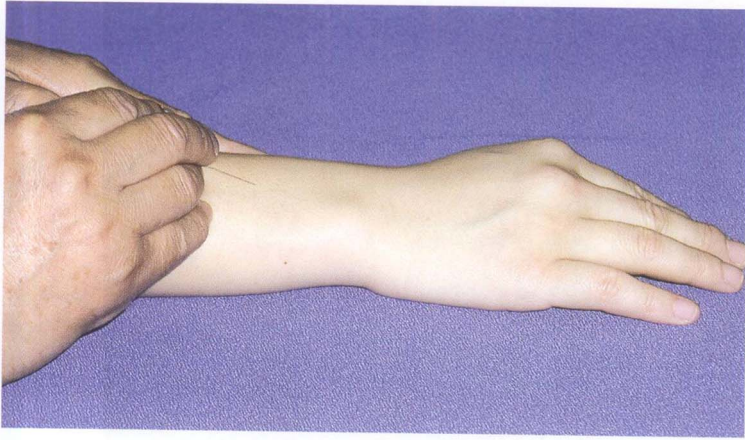


5. Gesture of pushing the needle subcutaneously.

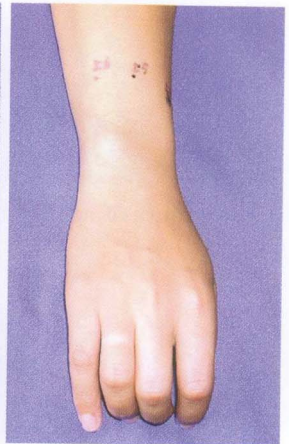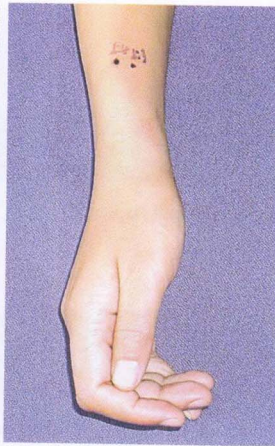
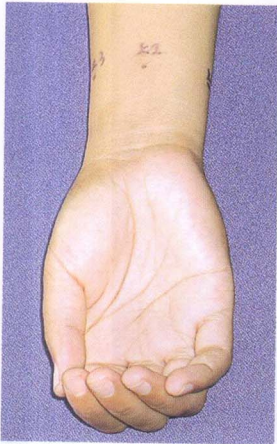6. The inserting point should be shifted a bit proximally if there is visible blood vessel at the selected inserting point.





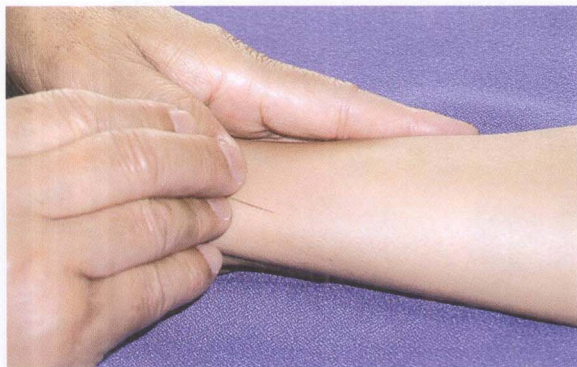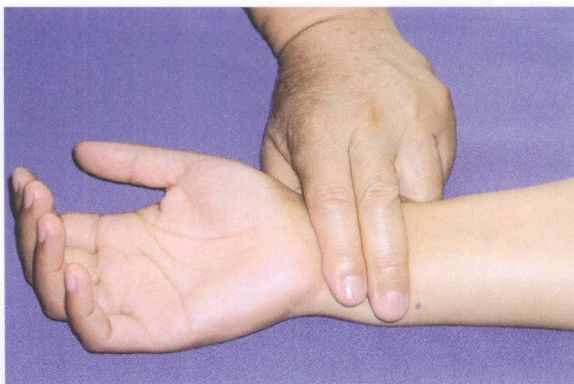


7. When the tip of the needle is directed distally, the inserting point should be shifted a bit proximally.

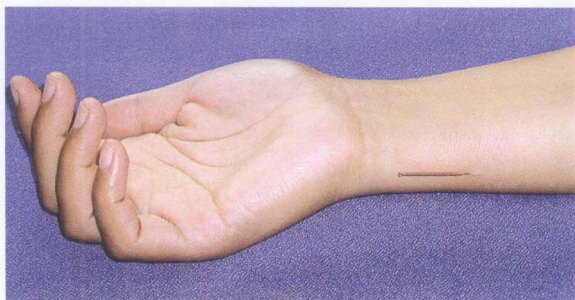


8. Position of Upper 1, Upper 2 and Upper 3 on the palmar aspect of the wrist.
9. Upper 4 is on the border of the radius at the juncture of the palmar and dorsal aspect.
10. Position of Upper 5 and Upper 6 on the dorsal aspect of the distal forearm.

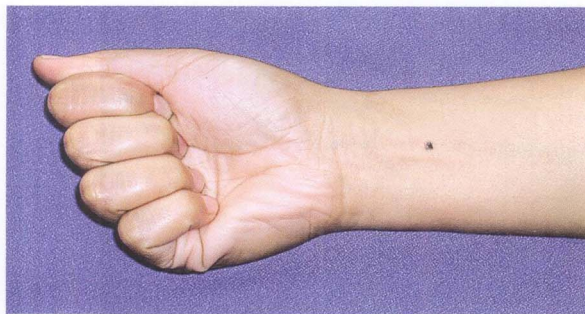
11. Location of Upper 1, in the depression between the border of the ulna and the tendon of musculus flexor carpi ulnaris.



12. Gesture of needle insertion of Upper 1.

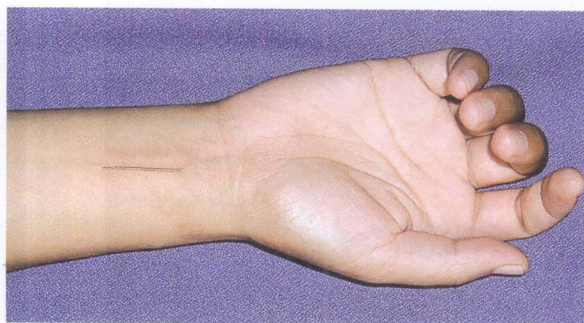
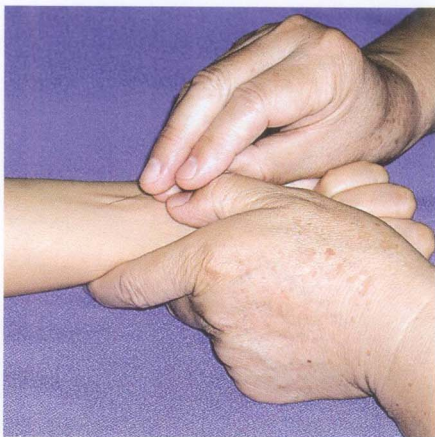

13. Position of needle on the Upper 1 after insertion.



14. Location of Upper 2, midway between the tendons of musculus palmaris longus and musculus flexor carpi radialis.

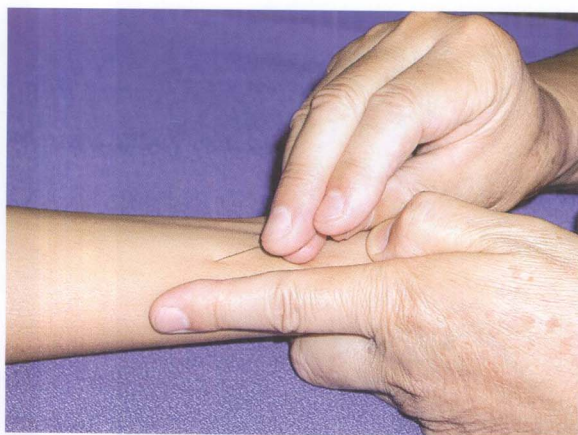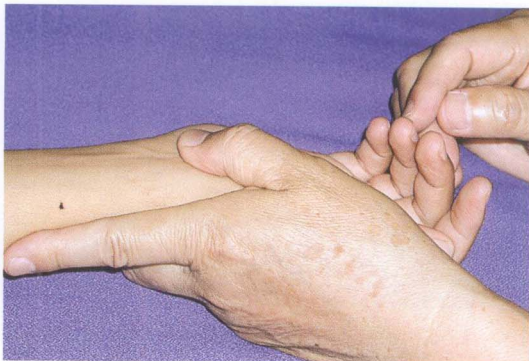15. Gesture of needle insertion of Upper 2.



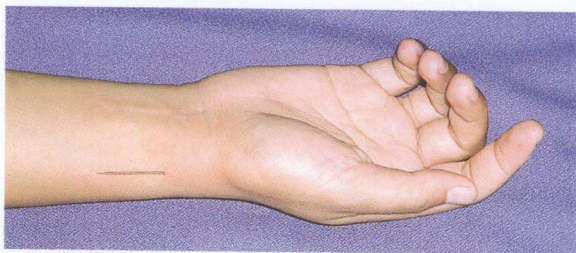16. Position of needle on Upper 2 after insertion.



17. Location of Upper 3, on the palmar aspect of the wrist, 1cm from the radial border of the forearm, between the radius and the radial artery.

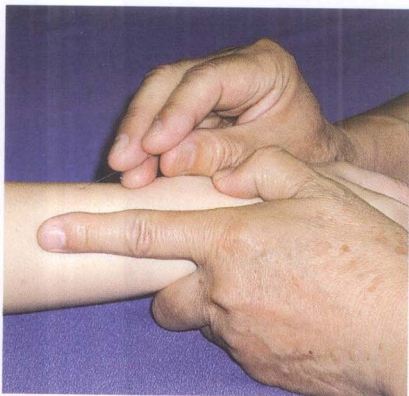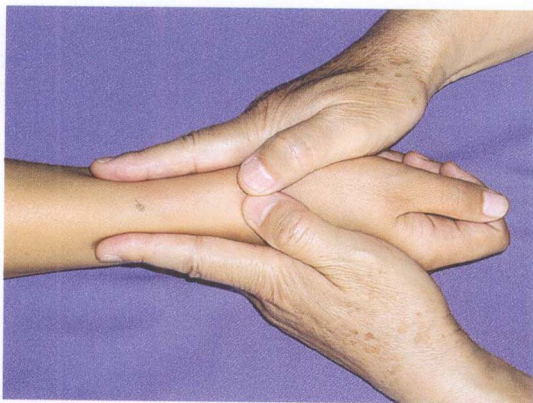


18. Gesture of needle insertion of Upper 3.

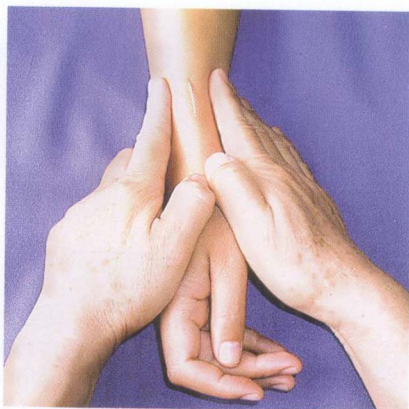


19. Position of the needle on Upper 3 after insertion.

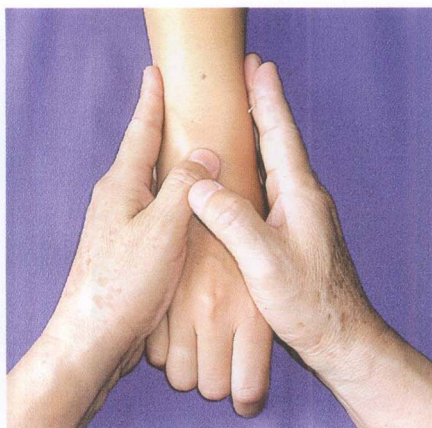
20. Location of Upper 4, on the lateral border of the radius.



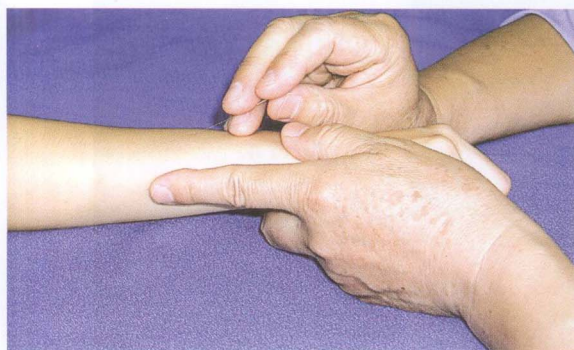21. Gesture of needle insertion of Upper 4.



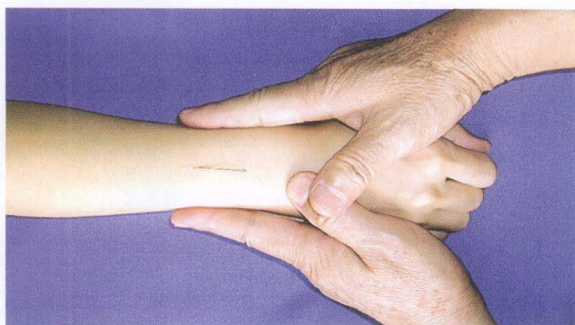22. Position of the needle on Upper 4 after insertion.



23. Location of Upper 5, midway between two lateral edges of the radius and the ulna.



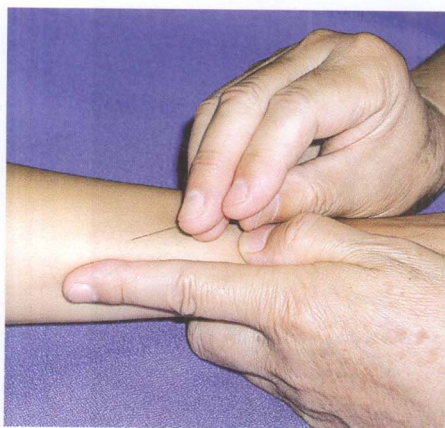
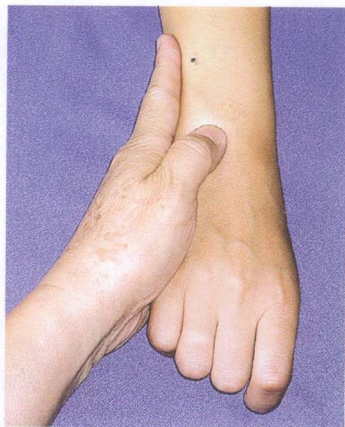24. Gesture of needle insertion of Upper 5.



25. Position of the needle on Upper 5 after insertion.

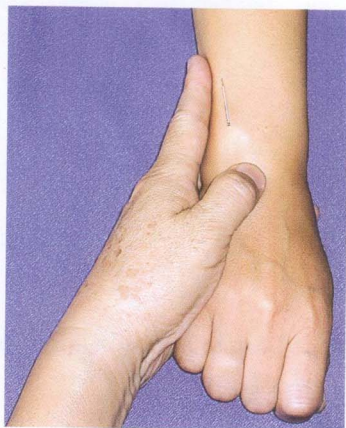


26. Location of Upper 6, on the dorsal side of the wrist, 1cm from its ulnar border.

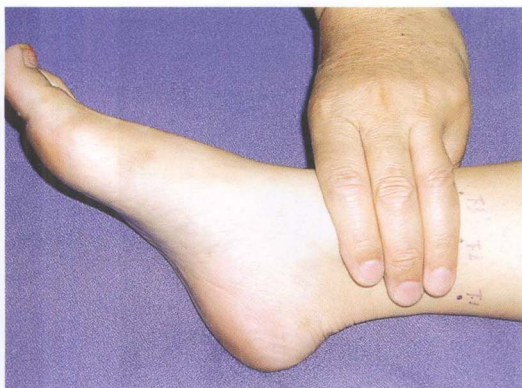

27. Gesture of needle insertion of Upper 6.

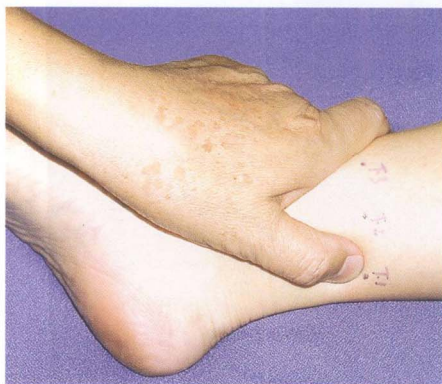28. Position of the needle on Upper 6 after insertion.



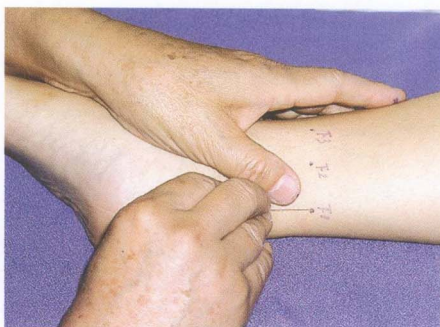



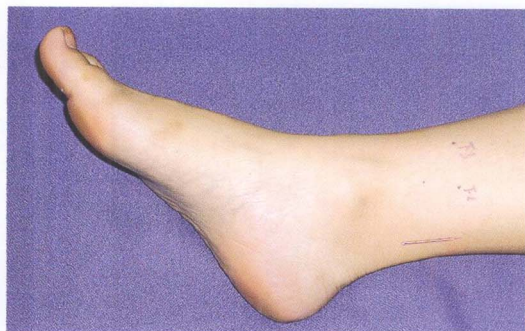29. The points at the ankle are located approximately three finger-breadths proximal to the tips of malleoli.



30. Location of Lower 1, on the medial side of the distal portion of the leg, close to the medial border of tendo calcaneus.

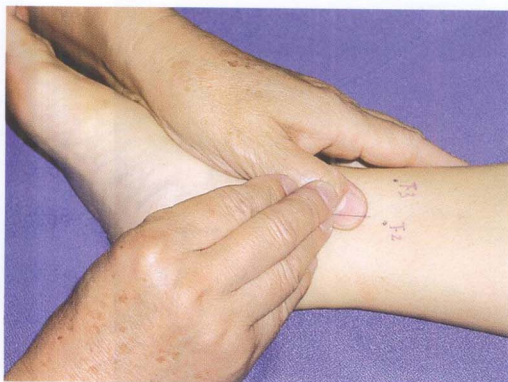
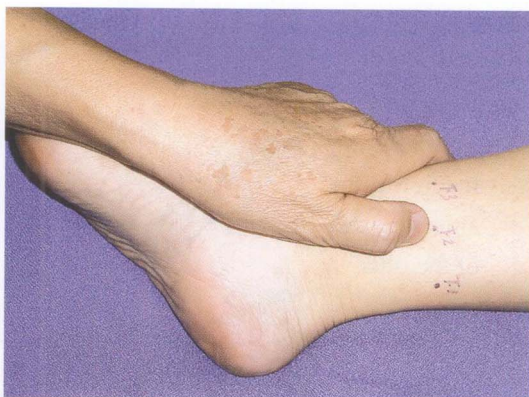
31. Gesture of needle insertion of Lower 1.

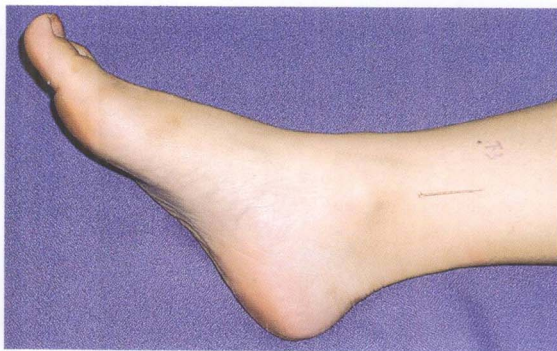

32. Position of the needle on Lower 1 after insertion.

33. Location of Lower 2, at the center of the medial side of the distal portion of the leg, just posterior to the tibial border.

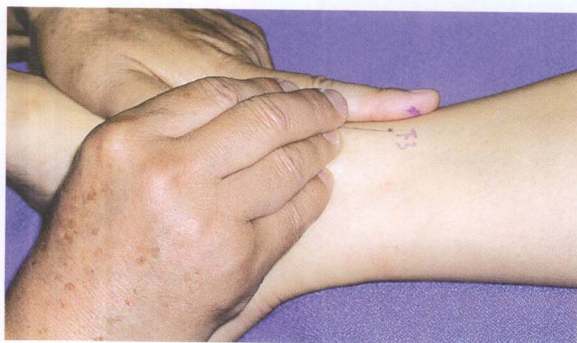
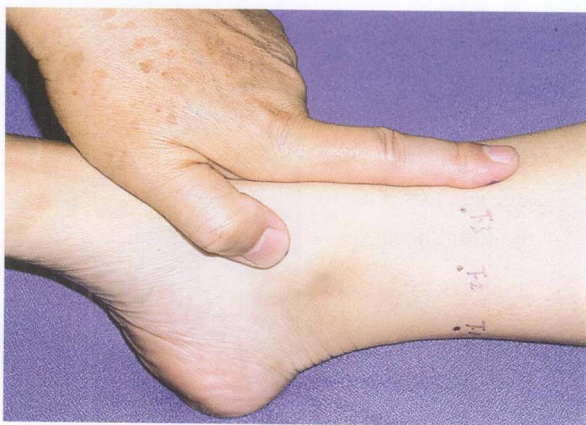
34. Gesture of needle insertion of Lower 2.



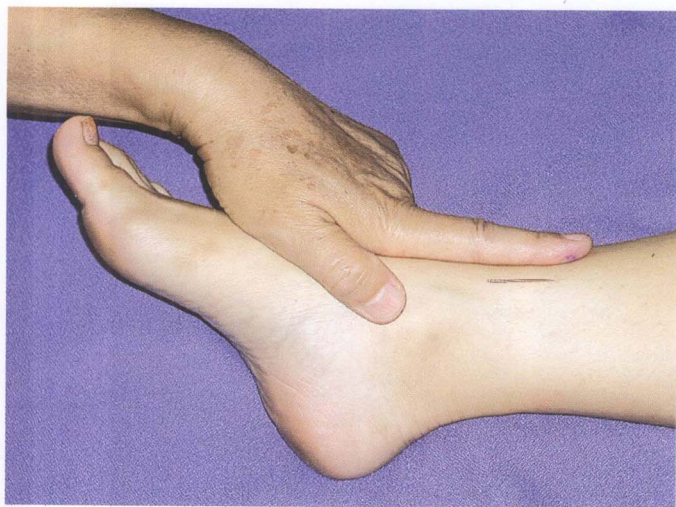35. Position of the needle on Lower 2 after insertion.

36. Location of Lower 3, 1cm medial to the anterior crest of the tibia.

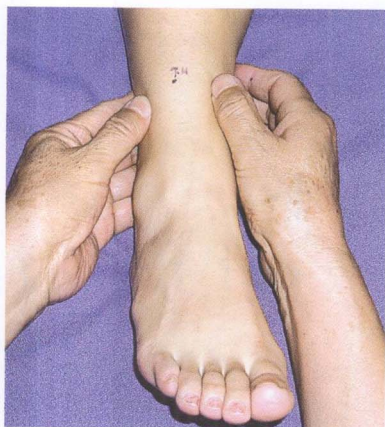


37. Gesture of needle insertion of Lower 3.

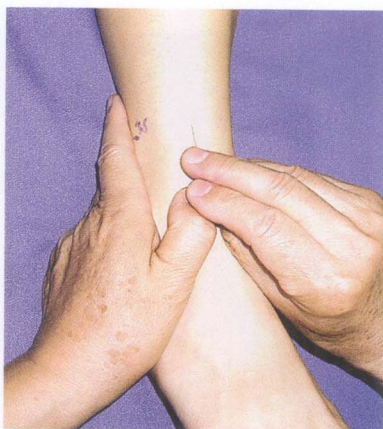



38. Position of the needle on Lower 3 after insertion.

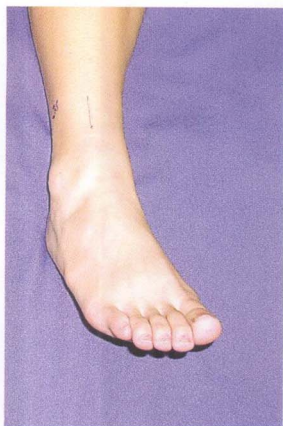


39. Location of Lower 4, feel the anterior crest of tibia and the anterior border of the fibula with the fingers, the point is located in the middle.

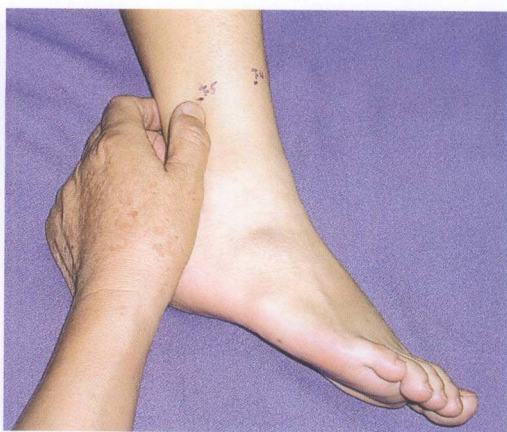

40. Gesture of needle insertion of Lower 4.

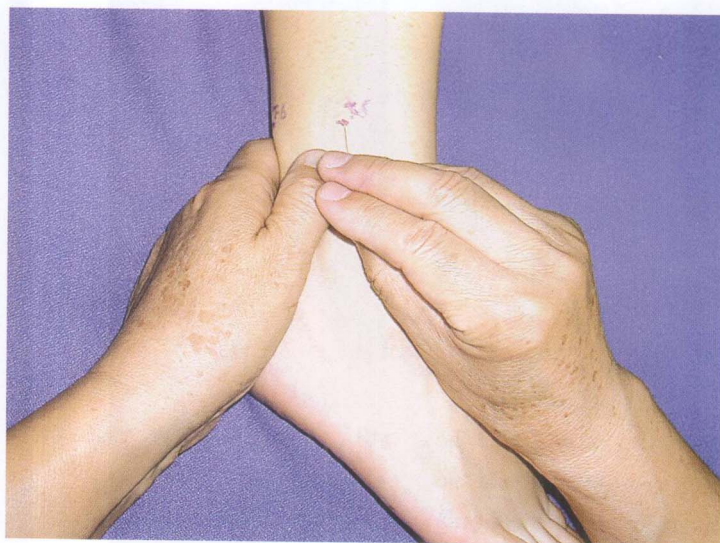



41. Position of the needle on Lower 4 after insertion.



42. Location of Lower 5, at the center of the lateral aspect of the distal portion of the leg, in the depression between the border of the fibula and the tendon of m. peroneus longus.



43. Gesture of needle insertion of Lower 5.