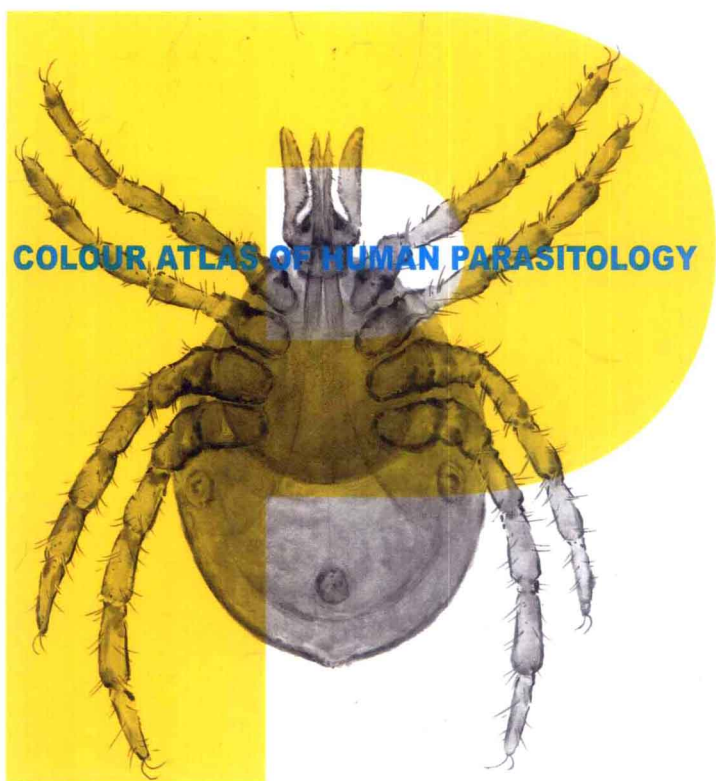


主 编 徐国成 韩秋生 王继春

# 人体寄生虫学彩色图谱




 人民军医出版社

PEOPLE'S MILITARY MEDICAL PRESS

FOUR ATLAS OF HUMAN PARASITOLOGY



ATLAS



人體寄生蟲學彩色圖譜

主 編

徐國成 韓秋生 王繼春



人民軍醫出版社

PEOPLE'S MILITARY MEDICAL PRESS

· 北 京 ·



ATLAS

谱

## ●【人体寄生虫学彩色图谱】编委会名单

主 编 徐国成 韩秋生 王继春  
 副主编 曹雅明 崔 昱 李雅杰 李鲁平  
 编 绘 (以姓氏笔画为序)  
 于 洋 王 阳 王继东 巴 静 邓立君 由晓芳  
 冯 辉 刘东举 刘 枫 刘英杰 阮鼎和 李久宏  
 李会波 李 佳 李 虹 李 婷 李 薇 邹卫东  
 宋 阳 金春峰 郑 丽 荆玉辰 姜懿凌 秦元华  
 高 柏 曹成侠 康 悦 焉雨濛 蒋志云 翟 宁

### 图书在版编目 (CIP) 数据

人体寄生虫学彩色图谱 / 徐国成, 韩秋生, 王继春  
 主编. —北京: 人民军医出版社, 2011.8  
 ISBN 978-7-5091-4036-9

I. ①人… II. ①徐… ②韩… ③王… III. ①医学: 寄生虫学—图谱 IV. ① R38-64

中国版本图书馆 CIP 数据核字(2011)第 101297 号

策划编辑: 张 晶 丁 震 文字编辑: 王晓东 责任审读: 刘 平  
 出版人: 石 虹

出版发行: 人民军医出版社 经销: 新华书店  
 通信地址: 北京市 100036 信箱 188 分箱 邮编: 100036

质量反馈电话: (010)51927278

邮购电话: (010)51927252

策划编辑电话: (010)51927278

网址: www.pmmp.com.cn

印装: 三河市春园印刷有限公司

开本: 889mm × 1194mm

印张: 5 字数: 116 千字

版、印次: 2011 年 8 月第 1 版第 1 次印刷

印数: 0001 ~ 3000

定价: 55.00 元

版权所有 侵权必究

购买本社图书, 凡有缺、倒、脱页者, 本社负责调换



## ● 前 言

人体寄生虫学是病原生物学的重要组成部分，是以寄生虫的形态结构及宿主的病理改变为主要内容的一门学科，具有很强的直观性。近年来，国内偶有寄生虫学图谱问世，但迄今尚缺乏一部人工绘制的彩色图谱。为了填补此空白，我们在总结国内外同行成熟经验的基础上，精心编绘了这部以人工绘制彩图为主，并辅以显微摄影图片的《人体寄生虫学彩色图谱》。

本书遵循全国普通高等医学院校教学大纲的要求，紧密围绕全国统编教材的主要内容，并以国内常见的致病性寄生虫种为着眼点编绘而成，全书共收载254幅彩图。与同类著作相比，这部图谱具有如下创新点：首先，本书人工绘制了131幅彩图，是国内首部采用水彩绘画形成表现寄生虫形态结构、宿主病理改变的专业图谱。这种写实的绘画风格使本书更具特色，是将水彩绘画技巧引入到人体寄生虫学图谱绘制的一种创新尝试。其次，本书吸取了国内外相同学科教材和图谱的精华，经过严谨构思、严密设计，精心绘制了一些寄生虫的生活史彩色示意图及某些重要食源性寄生虫病的传播媒介的彩图，生动形象地表现出寄生虫与宿主相互作用的内涵，便于学生理解和记忆。再次，本书显微摄影图片也是优中选优，使形态结构及病变更具典型性，以弥补教材中照片的不足。本书是高等医学院校学生学习人体寄生虫学的辅助工具，对从事临床检验、疾病预防与控制的专业人员也具有一定的参考价值。

由于编者学识所限，同时受客观因素制约，本书概括的人体寄生虫学主要教学内容难免存在缺点，期望同道不吝赐教，以便进一步完善。

编 者

2011年1月于中国医科大学

## 目 录

## 1 医学原虫

1. 溶组织内阿米巴滋养体 (铁苏木素染色)  
*Entamoeba histolytica* trophozoite stained  
with iron hematoxylin ..... 2
2. 溶组织内阿米巴滋养体 (铁苏木素染色)  
*Entamoeba histolytica* trophozoite stained  
with iron hematoxylin ..... 2
3. 溶组织内阿米巴包囊 (铁苏木素染色)  
*Entamoeba histolytica* cyst stained  
with iron hematoxylin ..... 2
4. 溶组织内阿米巴包囊 (铁苏木素染色)  
*Entamoeba histolytica* cyst stained  
with iron hematoxylin ..... 3
5. 溶组织内阿米巴包囊 (铁苏木素染色)  
*Entamoeba histolytica* cysts stained  
with iron hematoxylin ..... 3
6. 溶组织内阿米巴包囊 (碘染色)  
*Entamoeba histolytica* cysts stained  
with iodine ..... 3
7. 结肠内阿米巴包囊 (铁苏木素染色)  
*Entamoeba coli* cyst stained  
with iron hematoxylin ..... 4
8. 结肠内阿米巴包囊 (铁苏木素染色)  
*Entamoeba coli* cyst stained  
with iron hematoxylin ..... 4
9. 结肠内阿米巴包囊 (碘染色)  
*Entamoeba coli* cysts stained with iodine ..... 4
10. 溶组织内阿米巴生活史  
Life cycle of *Entamoeba histolytica* ..... 5
11. 结肠溃疡中的溶组织内阿米巴滋养体 (苏木素和伊红染色)  
*Entamoeba histolytica* trophozoites in  
colonic ulcer (H & E) ..... 6
12. 结肠溃疡中的溶组织内阿米巴滋养体 (苏木素和伊红染色)  
*Entamoeba histolytica* trophozoites in  
colonic ulcer (H & E) ..... 6
13. 结肠溃疡中的溶组织内阿米巴滋养体 (苏木素和伊红染色)  
*Entamoeba histolytica* trophozoites in  
colonic ulcer (H & E) ..... 6
14. 结肠溃疡中的溶组织内阿米巴滋养体 (苏木素和伊红染色)  
*Entamoeba histolytica* trophozoites in  
colonic ulcer (H & E) ..... 7
15. 阿米巴结肠溃疡 (苏木素和伊红染色)  
Amebic colonic ulcer (H & E) ..... 7
16. 阿米巴结肠病变  
Amebic colonic lesion ..... 8
17. 阿米巴肝脓肿  
Amebic liver abscess ..... 8
18. 棘阿米巴滋养体  
*Acanthamoeba* sp. trophozoite ..... 9
19. 棘阿米巴包囊  
*Acanthamoeba* sp. cysts ..... 9
20. 杜氏利什曼原虫无鞭毛体 (姬氏染色)  
*Leishmania donovani* amastigotes stained  
with Giemsa ..... 10



## 目 录

- |   |    |   |    |
|---|----|---|----|
| 21. 杜氏利什曼原虫前鞭毛体 (姬氏染色)<br><i>Leishmania donovani</i> promastigotes stained<br>with Giemsa ..... | 10 | 32. 间日疟原虫大滋养体 (姬氏染色)<br>Trophozoite of <i>Plasmodium vivax</i> stained<br>with Giemsa .....         | 15 |
| 22. 杜氏利什曼原虫前鞭毛体 (姬氏染色)<br><i>Leishmania donovani</i> promastigotes stained<br>with Giemsa ..... | 10 | 33. 间日疟原虫未成熟裂殖体 (姬氏染色)<br>Immature schizont of <i>Plasmodium vivax</i><br>stained with Giemsa ..... | 15 |
| 23. 杜氏利什曼原虫生活史<br>Life cycle of <i>Leishmania donovani</i> .....                                | 11 | 34. 间日疟原虫成熟裂殖体 (姬氏染色)<br>Mature schizont of <i>Plasmodium vivax</i><br>stained with Giemsa .....    | 15 |
| 24. 黑热病后皮肤利什曼疹<br>Post kala-azar dermal leishmaniasis .....                                     | 12 | 35. 间日疟原虫成熟裂殖体 (姬氏染色)<br>Mature schizont of <i>Plasmodium vivax</i><br>stained with Giemsa .....    | 16 |
| 25. 蓝氏贾第鞭毛虫滋养体 (瑞氏染色)<br><i>Giardia lamblia</i> trophozoites stained<br>with Wright .....       | 12 | 36. 间日疟原虫雌配子体 (姬氏染色)<br>Macrogametocyte of <i>Plasmodium vivax</i><br>stained with Giemsa .....     | 16 |
| 26. 蓝氏贾第鞭毛虫包囊 (铁苏木素染色)<br><i>Giardia lamblia</i> cysts stained<br>with iron hematoxylin .....   | 13 | 37. 间日疟原虫配子体 (姬氏染色)<br>Gametocytes of <i>Plasmodium vivax</i><br>stained with Giemsa .....          | 16 |
| 27. 贾第虫病肠切片 (苏木素和伊红染色)<br>Section of bowel tissue of giardiasis (H & E) ...                     | 13 | 38. 间日疟原虫 (姬氏染色)<br><i>Plasmodium vivax</i> stained with Giemsa .....                               | 17 |
| 28. 阴道毛滴虫 (姬氏染色)<br><i>Trichomonas vaginalis</i> stained with Giemsa ...                        | 13 | 39. 间日疟原虫厚血膜 (姬氏染色)<br>Thick blood film of <i>Plasmodium vivax</i><br>stained with Giemsa .....     | 17 |
| 29. 阴道毛滴虫 (姬氏染色)<br><i>Trichomonas vaginalis</i> stained with Giemsa ...                        | 14 | 40. 间日疟原虫生活史<br>Life cycle of <i>Plasmodium vivax</i> .....   | 18 |
| 30. 间日疟原虫环状体 (姬氏染色)<br>Ring forms of <i>Plasmodium vivax</i> stained<br>with Giemsa .....       | 14 | 41. 恶性疟原虫环状体 (姬氏染色)<br>Ring forms of <i>Plasmodium falciparum</i> stained<br>with Giemsa .....      | 19 |
| 31. 间日疟原虫大滋养体 (姬氏染色)<br>Trophozoite of <i>Plasmodium vivax</i> stained<br>with Giemsa .....     | 14 |   |    |



## 目 录

42. 恶性疟原虫雄配子体 (姬氏染色)  
Microgametocyte of *Plasmodium falciparum*  
stained with Giemsa ..... 19
43. 恶性疟原虫雄配子体 (姬氏染色)  
Microgametocyte of *Plasmodium falciparum*  
stained with Giemsa ..... 20
44. 恶性疟原虫雌配子体 (姬氏染色)  
Macrogametocyte of *Plasmodium falciparum*  
stained with Giemsa ..... 20
45. 恶性疟原虫雌配子体 (姬氏染色)  
Macrogametocyte of *Plasmodium falciparum*  
stained with Giemsa ..... 21
46. 刚地弓形虫 (弓形虫) 滋养体 (姬氏染色)  
*Toxoplasma gondii* trophozoites stained  
with Giemsa ..... 21
47. 弓形虫滋养体 (姬氏染色)  
*Toxoplasma gondii* trophozoites stained  
with Giemsa ..... 22
48. 脑组织中的弓形虫包囊 (姬氏染色)  
*Toxoplasma gondii* cyst in brain stained  
with Giemsa ..... 22
49. 淋巴结中的弓形虫假包囊 (姬氏染色)  
*Toxoplasma gondii* pseudocyst in lymph node  
stained with Giemsa ..... 23
50. 弓形虫卵囊  
*Toxoplasma gondii* oocysts ..... 23
51. 弓形虫生活史  
Life cycle of *Toxoplasma gondii* ..... 24
52. 弓形虫眼病 (视网膜脉络膜炎)  
Ocular toxoplasmosis (retinochoroiditis) ..... 25
53. 隐孢子虫卵囊 (改良抗酸染色)  
*Cryptosporidium* sp. oocysts,  
modified acid-fast staining ..... 25
54. 隐孢子虫病肠切片 (苏木素和伊红染色)  
Section of bowel tissue  
of cryptosporidiasis (H & E) ..... 26
55. 肺孢子虫包囊 (姬氏染色)  
*Pneumocystis* sp. cysts stained with Giemsa ... 26
56. 肺孢子虫包囊 (镀银染色)  
*Pneumocystis* sp. cysts stained with silver ... 27
57. 结肠小袋纤毛虫滋养体 (铁苏木素染色)  
*Balantidium coli* trophozoite stained  
with iron hematoxylin ..... 27
58. 结肠小袋纤毛虫包囊 (铁苏木素染色)  
*Balantidium coli* cysts stained  
with iron hematoxylin ..... 27

## 2 医学蠕虫

59. 华支睾吸虫 (肝吸虫) 成虫 (卡红染色)  
Adult *Clonorchis sinensis* stained  
with carmine ..... 30
60. 肝吸虫卵  
Eggs of *Clonorchis sinensis* ..... 31



ATLAS

谱

## 目 录

61. 肝吸虫尾蚴 (卡红染色)  
Cercaria of *Clonorchis sinensis* stained  
with carmine ..... 31
62. 肝吸虫囊蚴  
Encysted metacercariae of  
*Clonorchis sinensis* ..... 31
63. 肝吸虫生活史  
Life cycle of *Clonorchis sinensis* ..... 32
64. 肝吸虫第一中间宿主纹沼螺  
*Parafossarulus striatulus*, the first  
intermediate host of *Clonorchis sinensis* ..... 33
65. 肝吸虫第二中间宿主麦穗鱼  
*Pseudorasbora parva*, the second  
intermediate host of *Clonorchis sinensis* ..... 33
66. 肝吸虫第二中间宿主青鱼 (黑鲢)  
*Mylopharyngodon piceus*, the second  
intermediate host of *Clonorchis sinensis* ..... 33
67. 肝吸虫第二中间宿主草鱼 (白鲢)  
*Ctenopharyngodon idellus*, the second  
intermediate host of *Clonorchis sinensis* ..... 33
68. 肝吸虫第二中间宿主鲤鱼  
*Cyprinus carpio*, the second intermediate  
host of *Clonorchis sinensis* ..... 34
69. 肝吸虫第二中间宿主鲫鱼  
*Carassius auratus*, the second intermediate  
host of *Clonorchis sinensis* ..... 34
70. 肝吸虫成虫寄生的肝胆管切片 (苏木素和伊红染色)  
Section of adults of *Clonorchis sinensis*  
in intrahepatic bile duct (H & E) ..... 34
71. 布氏姜片吸虫 (姜片虫) 成虫 (卡红染色)  
Adult *Fasciolopsis buski* stained with carmine ... 35
72. 姜片虫卵  
Egg of *Fasciolopsis buski* ..... 36
73. 肝吸虫卵和姜片虫卵  
Eggs of *Clonorchis sinensis*  
and *Fasciolopsis buski* ..... 36
74. 姜片虫生活史  
Life cycle of *Fasciolopsis buski* ..... 37
75. 姜片虫中间宿主扁卷螺  
*Segmentina* sp., intermediate host  
of *Fasciolopsis buski* ..... 38
76. 姜片虫植物媒介菱角  
Water caltrop, plant vector of *Fasciolopsis buski* ... 38
77. 姜片虫植物媒介荸荠  
Water chestnut, plant vector of *Fasciolopsis buski* ... 39
78. 姜片虫植物媒介茭白  
Wild rice stem, plant vector of  
*Fasciolopsis buski* ..... 39
79. 姜片虫植物媒介莲藕  
Lotus root, plant vector of *Fasciolopsis buski* ... 40
80. 肝片形吸虫成虫 (卡红染色)  
Adult *Fasciola hepatica* stained with carmine ..... 40
81. 卫氏并殖吸虫成虫 (卡红染色)  
Adult *Paragonimus westermani* stained  
with carmine ..... 41
82. 卫氏并殖吸虫卵  
Egg of *Paragonimus westermani* ..... 42
83. 卫氏并殖吸虫卵  
Egg of *Paragonimus westermani* ..... 42





## 目 录

84. 卫氏并殖吸虫毛蚴 (卡红染色)  
Miracidium of *Paragonimus westermani*  
stained with carmine ..... 42
85. 卫氏并殖吸虫雷蚴 (卡红染色)  
Daughter redia of *Paragonimus westermani*  
stained with carmine ..... 43
86. 卫氏并殖吸虫尾蚴 (卡红染色)  
Cercaria of *Paragonimus westermani*  
stained with carmine ..... 43
87. 卫氏并殖吸虫囊蚴 (卡红染色)  
Encysted metacercariae of *Paragonimus westermani* stained with carmine ..... 43
88. 卫氏并殖吸虫生活史  
Life cycle of *Paragonimus westermani* ..... 44
89. 卫氏并殖吸虫第一中间宿主川卷螺  
Malaniid snails, the first intermediate host  
of *Paragonimus westermani* ..... 45
90. 卫氏并殖吸虫第二中间宿主螯蛄  
Crayfish, the second intermediate host  
of *Paragonimus westermani* ..... 45
91. 卫氏并殖吸虫第二中间宿主溪蟹  
*Potamon* sp., the second intermediate  
host of *Paragonimus westermani* ..... 46
92. 卫氏并殖吸虫成虫寄生的肺组织切片 (苏木素和伊红染色)  
Section of adults of *Paragonimus westermani* in lung tissue (H & E) ..... 46
93. 卫氏并殖吸虫寄生的犬肺  
Dog lung infected  
with *Paragonimus westermani* ..... 47
94. 卫氏并殖吸虫寄生的犬肺  
Dog lung infected with *Paragonimus westermani* ..... 48
95. 斯氏狸殖吸虫成虫 (卡红染色)  
Adult *Pagumogonimus skrjabini* stained  
with carmine ..... 49
96. 日本血吸虫成虫 (卡红染色)  
Adults *Schistosoma japonicum* stained  
with carmine ..... 49
97. 日本血吸虫成虫雌雄合抱 (卡红染色)  
Adults *Schistosoma japonicum*, female  
and male in copula stained with carmine ..... 50
98. 日本血吸虫卵  
Egg of *Schistosoma japonicum* ..... 50
99. 日本血吸虫卵  
Egg of *Schistosoma japonicum* ..... 51
100. 日本血吸虫毛蚴 (卡红染色)  
Miracidium of *Schistosoma japonicum*  
stained with carmine ..... 51
101. 日本血吸虫孢子蚴 (卡红染色)  
Daughter sporocyst of *Schistosoma japonicum* stained with carmine ..... 52
102. 日本血吸虫尾蚴 (卡红染色)  
Cercaria of *Schistosoma japonicum* stained  
with carmine ..... 52
103. 日本血吸虫生活史  
Life cycle of *Schistosoma japonicum* ..... 53
104. 日本血吸虫中间宿主钉螺  
*Oncelania* sp., the intermediate host  
of *Schistosoma japonicum* ..... 54

## 目 录

105. 肝组织内的日本血吸虫卵内芽肿切片(苏木素和伊红染色)  
Section of egg granuloma of *Schistosoma japonicum* in liver tissue (H & E) ..... 54
106. 肝组织内的日本血吸虫卵内芽肿切片(苏木素和伊红染色)  
Section of egg granuloma of *Schistosoma japonicum* in liver tissue (H & E) ..... 55
107. 肝组织内的日本血吸虫卵内芽肿切片(苏木素和伊红染色)  
Section of egg granuloma of *Schistosoma japonicum* in liver tissue (H & E) ..... 55
108. 慢性血吸虫病患者  
Patient with chronic schistosomiasis ..... 56
109. 血吸虫病肠病变(兔)  
Rabbit intestinal lesions in schistosomiasis ... 56
110. 血吸虫病肝病变(兔)  
Rabbit hepatic lesions in schistosomiasis ... 57
111. 日本血吸虫寄生的肠系膜静脉(兔)  
Rabbit mesenteric vein infected with *Schistosoma japonicum* ..... 57
112. 曼氏血吸虫卵  
Eggs of *Schistosoma mansoni* ..... 58
113. 埃及血吸虫卵  
Eggs of *Schistosoma haematobium* ..... 58
114. 异形异形吸虫成虫(卡红染色)  
Adult of *Heterophyes heterophyes* stained with carmine ..... 59
115. 横川后殖吸虫成虫(卡红染色)  
Adult *Metagonimus yokogawai* stained with carmine ..... 60
116. 棘口吸虫成虫(卡红染色)  
Adult *Echinostoma* sp. stained with carmine ..... 61
117. 曼氏迭宫绦虫头节(卡红染色)  
Scolex of *Spirometra mansoni* stained with carmine ..... 62
118. 曼氏迭宫绦虫成节(卡红染色)  
Mature proglottids of *Spirometra mansoni* stained with carmine ..... 62
119. 曼氏迭宫绦虫卵  
Eggs of *Spirometra mansoni* ..... 63
120. 曼氏裂头蚴(卡红染色)  
Plerocercoid of *Spirometra mansoni* stained with carmine ..... 63
121. 皮下裂头蚴病  
Subcutaneous sparganosis ..... 64
122. 眼裂头蚴病  
Ocular sparganosis ..... 64
123. 阔节裂头绦虫成虫  
Adult *Diphyllobothrium latum* ..... 65
124. 阔节裂头绦虫头节(卡红染色)  
Scolex of *Diphyllobothrium latum* stained with carmine ..... 66
125. 阔节裂头绦虫成节(卡红染色)  
Mature proglottids of *Diphyllobothrium latum* stained with carmine ..... 66
126. 链状带绦虫成虫  
Adult *Taenia solium* ..... 67



## 目 录

127. 链状带绦虫头节 (卡红染色)	
Scolex of <i>Taenia solium</i> stained	
with carmine .....	68
128. 链状带绦虫头节 (卡红染色)	
Scolex of <i>Taenia solium</i> stained	
with carmine .....	68
129. 链状带绦虫成节 (卡红染色)	
Mature proglottids of <i>Taenia solium</i> stained	
with carmine .....	68
130. 链状带绦虫孕节 (卡红染色)	
Gravid proglottid of <i>Taenia solium</i> stained	
with carmine .....	69
131. 链状带绦虫孕节 (卡红染色)	
Gravid proglottid of <i>Taenia solium</i> stained	
with carmine .....	69
132. 带绦虫横断面 (苏木素和伊红染色)	
Transverse section of tapeworm (H & E) ...	70
133. 带绦虫横断面 (苏木素和伊红染色)	
Transverse section of tapeworm (H & E) ...	70
134. 带绦虫卵	
Egg of tapeworm .....	70
135. 带绦虫卵	
Egg of tapeworm .....	71
136. 猪囊尾蚴 (卡红染色)	
<i>Cysticercus cellulosae</i> stained with carmine ...	71
137. 猪囊尾蚴 (卡红染色)	
<i>Cysticercus cellulosae</i> stained with carmine ...	71
138. 链状带绦虫生活史	
Life cycle of <i>Taenia solium</i> .....	72
139. 皮下囊尾蚴病	
Subcutaneous cysticercosis .....	73
140. 肌肉囊尾蚴病 (猪)	
Muscular cysticercosis of pig .....	74
141. 眼囊尾蚴病	
Ocular cysticercosis .....	75
142. 脑囊尾蚴病	
Cerebral cysticercosis .....	75
143. 心肌囊尾蚴病 (猪)	
Myocardial cysticercosis of pig .....	76
144. 肥胖带绦虫成虫	
Adult <i>Taenia saginata</i> .....	77
145. 肥胖带绦虫头节 (卡红染色)	
Scolex of <i>Taenia saginata</i> stained	
with carmine .....	78
146. 肥胖带绦虫成节 (卡红染色)	
Mature proglottids of <i>Taenia saginata</i>	
stained with carmine .....	78
147. 肥胖带绦虫孕节 (墨汁和卡红染色)	
Gravid proglottid of <i>Taenia saginata</i>	
stained with ink and carmine .....	79
148. 牛囊尾蚴 (卡红染色)	
<i>Cysticercus bovis</i> stained with carmine .....	79
149. 微小膜壳绦虫成虫 (卡红染色)	
Adult of <i>Hymenolepis nana</i> stained	
with carmine .....	80
150. 微小膜壳绦虫成虫头节 (卡红染色)	
Scolex of adult <i>Hymenolepis nana</i> stained	
with carmine .....	80



ATLAS

谱

## 目 录

151. 微小膜壳绦虫成节 (卡红染色)  
Mature proglottids of *Hymenolepis nana*  
stained with carmine ..... 81
152. 微小膜壳绦虫卵  
Egg of *Hymenolepis nana* ..... 81
153. 带绦虫卵和微小膜壳绦虫卵  
Eggs of tapeworm and *Hymenolepis nana* ... 81
154. 细粒棘球绦虫成虫 (卡红染色)  
Adult *Echinococcus granulosus* stained  
with carmine ..... 82
155. 细粒棘球绦虫成虫头节 (卡红染色)  
Scolex of *Echinococcus granulosus* stained  
with carmine ..... 82
156. 细粒棘球绦虫棘球蚴砂 (卡红染色)  
Hydatid sand of *Echinococcus granulosus*  
stained with carmine ..... 83
157. 细粒棘球绦虫棘球蚴砂 (卡红染色)  
Hydatid sand of *Echinococcus granulosus*  
stained with carmine ..... 83
158. 细粒棘球绦虫原头蚴 (卡红染色)  
Protoscolex of *Echinococcus granulosus*  
stained with carmine ..... 83
159. 细粒棘球绦虫棘球蚴切片 (苏木素和伊红染色)  
Section of hydatid cyst of  
*Echinococcus granulosus* (H & E) ..... 83
160. 细粒棘球绦虫生活史  
Life cycle of *Echinococcus granulosus* ..... 84
161. 肝棘球蚴  
Hydatid cyst of liver ..... 85
162. 肺棘球蚴病 (羊)  
Pulmonary echinococcosis of sheep ..... 86
163. 脑棘球蚴病  
Cerebral echinococcosis ..... 87
164. 犬复孔绦虫头节 (卡红染色)  
Scolex of *Dipylidium caninum* stained  
with carmine ..... 88
165. 犬复孔绦虫成节 (卡红染色)  
Mature proglottid of *Dipylidium caninum*  
stained with carmine ..... 88
166. 犬复孔绦虫孕节 (卡红染色)  
Gravid proglottid of *Dipylidium caninum*  
stained with carmine ..... 89
167. 犬复孔绦虫储卵囊  
Receptacula ovarum of *Dipylidium caninum* ... 89
168. 似蛔蛔线虫 (蛔虫) 成虫  
Adults of *Ascaris lumbricoides* ..... 90
169. 蛔虫唇瓣 (卡红染色)  
Lips of adult *Ascaris lumbricoides*  
stained with carmine ..... 90
170. 蛔虫雄虫交合刺 (卡红染色)  
Spicule of male *Ascaris lumbricoides*  
stained with carmine ..... 90
171. 蛔虫受精卵  
Fertilized egg of *Ascaris lumbricoides* ..... 91
172. 蛔虫受精卵  
Fertilized egg of *Ascaris lumbricoides* ..... 91
173. 蛔虫未受精卵  
Unfertilized egg of *Ascaris lumbricoides* ..... 91

## 目 录

174. 蛔虫受精卵和未受精卵  
Fertilized and unfertilized eggs  
of *Ascaris lumbricoides* ..... 92
175. 蛔虫受精卵和未受精卵  
Fertilized and unfertilized eggs  
of *Ascaris lumbricoides* ..... 92
176. 脱蛋白膜蛔虫受精卵  
Decorticated fertilized egg  
of *Ascaris lumbricoides* ..... 92
177. 脱蛋白膜蛔虫受精卵  
Decorticated fertilized egg  
of *Ascaris lumbricoides* ..... 93
178. 感染期蛔虫卵  
Infective egg of *Ascaris lumbricoides* ..... 93
179. 感染期蛔虫卵  
Infective egg of *Ascaris lumbricoides* ..... 93
180. 蛔虫生活史  
Life cycle of *Ascaris lumbricoides* ..... 94
181. 胆道蛔虫病  
Biliary ascariasis ..... 95
182. 蛔虫性肠梗阻  
Ascaris intestinal obstruction ..... 95
183. 蛔虫侵入阑尾  
*Ascaris lumbricoides* in appendix ..... 96
184. 蛔虫侵入胰腺  
*Ascaris lumbricoides* in pancreas ..... 96
185. 毛首鞭形线虫(鞭虫)雌虫(卡红染色)  
*Trichuris trichiura* female stained  
with carmine ..... 97
186. 鞭虫雄虫(卡红染色)  
*Trichuris trichiura* male stained  
with carmine ..... 97
187. 鞭虫卵  
Egg of *Trichuris trichiura* ..... 98
188. 鞭虫卵  
Egg of *Trichuris trichiura* ..... 98
189. 鞭虫附着肠黏膜  
Worms of *Trichuris trichiura* attached  
to intestinal mucosa ..... 99
190. 蠕形住肠线虫(蛲虫)成虫(卡红染色)  
Adults of *Enterobius vermicularis* stained  
with carmine ..... 100
191. 蛲虫头翼及咽管球(卡红染色)  
Cephalic alae and pharyngeal bulb of  
*Enterobius vermicularis* stained with carmine ... 100
192. 蛲虫卵  
Egg of *Enterobius vermicularis* ..... 100
193. 蛲虫生活史  
Life cycle of *Enterobius vermicularis* ..... 101
194. 蛲虫寄生于盲肠切片(苏木素和伊红染色)  
Section of *Enterobius vermicularis*  
in cecum (H & E) ..... 102
195. 十二指肠钩口线虫(卡红染色)  
Adults of *Ancylostoma duodenale* stained  
with carmine ..... 102
196. 美洲板口线虫(卡红染色)  
Adults of *Necator americanus* stained  
with carmine ..... 102



## 目 录

197. 十二指肠钩口线虫口囊 (卡红染色)  
Buccal capsule of *Ancylostoma duodenale*  
stained with carmine ..... 103
198. 美洲板口线虫口囊 (卡红染色)  
Buccal capsule of *Necator americanus*  
stained with carmine ..... 103
199. 十二指肠钩口线虫交合伞 (卡红染色)  
Copulatory bursa of *Ancylostoma duodenale*  
stained with carmine ..... 104
200. 美洲板口线虫交合伞 (卡红染色)  
Copulatory bursa of *Necator americanus*  
stained with carmine ..... 104
201. 钩虫卵  
Egg of hookworm ..... 105
202. 钩虫卵  
Egg of hookworm ..... 105
203. 钩虫卵  
Eggs of hookworm ..... 105
204. 钩虫卵  
Egg of hookworm ..... 106
205. 钩虫卵  
Eggs of hookworm ..... 106
206. 蛔虫受精卵和钩虫卵  
Fertilized egg of *Ascaris lumbricoides*  
and egg of hookworm ..... 106
207. 钩虫生活史  
Life cycle of hookworm ..... 107
208. 钩虫咬附肠黏膜切片 (苏木素和伊红染色)  
Section of hookworm attached  
to intestinal mucosa (H & E) ..... 108
209. 钩虫咬附肠黏膜  
Hookworms attached to intestinal mucosa ... 108
210. 钩虫所致匍行疹  
Creeping eruption caused  
by hookworm larvae ..... 109
211. 旋毛形线虫 (旋毛虫) 雌虫 (卡红染色)  
*Trichinella spiralis* female stained  
with carmine ..... 109
212. 旋毛虫雄虫 (卡红染色)  
*Trichinella spiralis* male stained  
with carmine ..... 109
213. 旋毛虫雌虫子宫 (卡红染色)  
Uterus of *Trichinella spiralis* female  
stained with carmine ..... 110
214. 旋毛虫雄虫末端 (卡红染色)  
Terminal of *Trichinella spiralis* male  
stained with carmine ..... 110
215. 旋毛虫幼虫囊包 (卡红染色)  
Encysted larvae of *Trichinella spiralis*  
stained with carmine ..... 111
216. 旋毛虫幼虫囊包 (卡红染色)  
Encysted larva of *Trichinella spiralis* stained  
with carmine ..... 111
217. 旋毛虫生活史  
Life cycle of *Trichinella spiralis* ..... 112
218. 班氏吴策线虫成虫  
Adult *Wuchereria bancrofti* ..... 113
219. 班氏微丝蚴 (梅氏苏木素染色)  
Microfilaria of *Wuchereria bancrofti* stained  
with Mayer's hematoxylin ..... 113



## 目 录

220. 马来微丝蚴 (梅氏苏木素染色)	
Microfilaria of <i>Brugia malayi</i> stained with Mayer's hematoxylin .....	114
221. 马来微丝蚴 (梅氏苏木素染色)	
Microfilaria of <i>Brugia malayi</i> stained with Mayer's hematoxylin .....	114
222. 丝虫生活史	
Life cycle of filaria .....	115
223. 阴囊象皮肿	
Elephantiasis of the scrotum .....	116
224. 下肢象皮肿	
Elephantiasis of the lower limb .....	116
225. 东方毛圆线虫卵	
Eggs of <i>Trichostrongylus orientalis</i> .....	117
226. 猪巨吻棘头虫棘头体 (卡红染色)	
Acanthella of <i>Macracanthorhynchus</i> <i>hirudinaceus</i> stained with carmine .....	117
227. 猪巨吻棘头虫寄生的猪小肠	
Pig small intestine infected with <i>Macracanthorhynchus hirudinaceus</i> .....	117

## 3 医学节肢动物

228. 全沟硬蜱雌虫	
<i>Ixodes persulcatus</i> female .....	120
229. 波斯锐缘蜱	
<i>Argas persicus</i> .....	121
230. 地里纤恙螨幼虫	
Larva of <i>Leptotrombidium deliense</i> .....	122
231. 格氏血厉螨雌虫	
<i>Haemolaelaps glasgowi</i> female .....	123
232. 人疥螨	
<i>Sarcoptes scabiei</i> .....	124
233. 屋尘螨雄虫	
<i>Dermatophagoides pteronyssinus</i> male .....	125
234. 毛囊蠕形螨	
<i>Demodex folliculorum</i> .....	126
235. 皮脂蠕形螨	
<i>Demodex brevis</i> .....	127
236. 中华按蚊	
<i>Anopheles sinensis</i> .....	128
237. 伯氏按蚊	
<i>Anopheles pattoni</i> .....	129
238. 致倦库蚊	
<i>Culex fatigans</i> .....	130
239. 白纹伊蚊	
<i>Aedes albopictus</i> .....	131
240. 蚊生活史	
Life cycle of mosquito .....	132
241. 舍蝇	
<i>Musca domestica vicina</i> .....	133



ATLAS

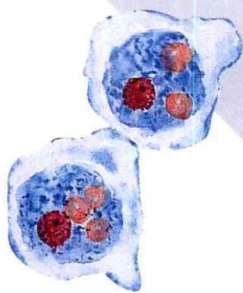
谱

## 目 录

242. 大头金蝇		249. 印鼠客蚤	
<i>Chrysomya megacephala</i> .....	133	<i>Xenopsylla cheopis</i> .....	138
243. 巨尾阿丽蝇		250. 人体虱	
<i>Aldrichia grahamsi</i> .....	134	<i>Pediculus humanus corporis</i> .....	139
244. 丝光绿蝇		251. 耻阴虱	
<i>Lucilia sericata</i> .....	134	<i>Pthirus pubis</i> .....	140
245. 棕尾别麻蝇		252. 人虱生活史	
<i>Boettcherisca peregrina</i> .....	135	Life cycle of <i>Pediculus humanus</i> .....	141
246. 厩腐蝇		253. 温带臭虫	
<i>Muscina stabulans</i> .....	135	<i>Cimex lectularius</i> .....	142
247. 蝇生活史		254. 美洲大蠊雄虫	
Life cycle of fly .....	136	<i>Periplaneta americana</i> male .....	143
248. 白蛉		<b>参考文献</b> .....	144
Sandfly .....	137		



# 1 MEDICAL PROTOZOA



医学原虫