8202079

R 656.6
2
3 P.T
P651
E991
2
49453
8202079
外文书库

BICKHAM-CALLANDER

Surgery of The Alimentary Tract

VOLUME TWO

By RICHARD T. SHACKELFORD, M.D.
Assistant Professor of Surgery
Johns Hopkins University School of Medicine

Assisted by Hammond J. Dugan, M.D.
Assistant in Surgery
Johns Hopkins University School of Medicine

W. B. Saunders Company
PHILADELPHIA LONDON 1955

62

Contents

VOLUME TWO

Chapter 5

THE PANCREAS 863

ANATOMY 863
EMBRYOLOGY AND HISTOLOGY 871
PHYSIOLOGY 872
GENERAL SURGICAL CONSIDERATIONS 874
METHODS OF EXPOSING THE PANCREAS 875
CONGENITAL MALFORMATIONS OF THE PANCREAS 879
Pancreas Divisum 879
Ectopic or Aberrant Pancreas 879
Annular Pancreas 881
Fibrocystic Pancreas 883
PANCREATIC INJURIES 883
Operative Treatment for Penetrating and Nonpenetrating Pancreatic Injuries 887
Treatment of Operative Injuries of the Pancreas 889
Incision for Biopsy 889
Injury to the Tail and Body of the Pancreas 889
Injury to the Head of the Pancreas 890
PANCREATITIS 892
Acute Pancreatitis 892
Nonsurgical Treatment 896
Operative Treatment by Pancreatotomy and Drainage by the Transgastrocolic Route 899
Chronic Pancreatitis 900
Choledochal Sphincterotomy 902
Dilation of the Sphincter of Oddi 903
Choledochojejunostomy (Bowers) 904
Other Sidetracking Operations 905
Decompression Procedures 905
Pancreatolithotomy 905
Sympathectomy 907
Ligation of Pancreatic Duct 916
Interlocking Mattress Ligation of Pancreas 916

Other Operations for Pancreatitis and Pancreatic Lithiasis.. 917
Results of Surgical Treatment of Chronic Relapsing Pancreatitis.... 917
CYSTS OF THE PANCREAS AND THEIR EXTENSIONS.... 918
Marsupialization of Pancreatic Cyst.... 920
Excision of a Pancreatic Cyst.... 922
Internal Drainage of Pancreatic Cysts.... 923
Roux-en-Y Cystojejunostomy.... 924
Partial Pancreatectomy Including Cyst in Resection.... 925
PANCREATIC FISTULAS.... 925
Excision of Pancreatic Fistula.... 926
Internal Drainage of Pancreatic Fistula.... 927
Excision of Tract Combined with Partial Pancreatectomy.... 927
Excision of Tract Combined with Sphincterotomy.... 928
ISLET CELL TUMORS OF THE PANCREAS.... 928
Excision of Islet Cell Tumor of Pancreas.... 930
PARTIAL PANCREATECTOMY: EXCISION OF THE TAIL AND BODY OF THE PANCREAS.... 934
CARCINOMA OF THE PANCREAS.... 938
CARCINOMA OF THE AMPULLA OF VATER.... 939
PANCREATODUODENAL RESECTION.... 940
One-Stage Pancreatoduodenal Resection (Trimble).... 943
Two-Stage Partial or Total Pancreatoduodenal Resection (Whipple) 959
Two-Stage Partial or Total Pancreatoduodenal Resection (Cattell).. 961
Complications Following Pancreatoduodenal Resection.... 962
Results of Pancreatoduodenal Resection.... 964
PALLIATIVE OPERATIONS FOR INOPERABLE CARCINOMA OF PANCREAS.... 964
REFERENCES.... 966

Chapter 6

THE SPLEEN 969

ANATOMY.... 969
PHYSIOLOGY.... 970
ACCESSORY SPLEENS.... 970
SPLENOSIS.... 972
GENERAL SURGICAL CONSIDERATIONS.... 972
INCISIONS.... 973
EXPLORATORY PUNCTURE OF THE SPLEEN AND SPLENIC BIOPSY.... 973
TOTAL SPLENECTOMY.... 975
LIGATION OF SPLENIC ARTERY.... 990
PARTIAL SPLENECTOMY.... 990
SPLENOTOMY.... 991
SURGICAL TREATMENT OF WOUNDS OF THE SPLEEN.... 992
Abdominal Wounds of the Spleen.... 992
Transthoracic Wounds of the Spleen.... 995
SPLENOPEXY FOR SPLENOPTOSIS.... 996
POSTOPERATIVE CARE IN OPERATION UPON THE SPLEEN.... 996
REFERENCES.... 997

Chapter 7

THE SMALL INTESTINE (JEJUNAL AND ILEAL PORTIONS) 999

ANATOMY 999
PHYSIOLOGY 1005
CONGENITAL ABNORMALITIES OF THE SMALL INTESTINE 1011
DISEASES OF THE JEJUNOILEUM 1017
Diverticulosis 1017
Tumors 1019
Primary Ulcer of the Jejunoileum 1024
Primary Jejunal Ulcer 1024
Primary Ileal Ulcer 1025
GENERAL SURGICAL CONSIDERATIONS IN OPERATING UPON THE INTESTINES .. 1026
ENTEROTOMY 1032
REPAIR OF INTESTINAL WOUNDS AND PERFORATIONS 1034
Repair of Wounds Due to Trauma 1035
Repair of Ulcerative Perforations 1039
ENTEROSTOMY 1040
Jejunostomy 1041
Temporary Jejunostomy 1043
Permanent Jejunostomy 1047
Jejunostomy Feeding 1049
Ileostomy 1051
Ileostomy with a Tube 1054
Ileostomy without a Tube: Tangential Ileostomy 1057
Ileostomy without a Tube: Double-Barrelled Ileostomy 1059
Ileostomy without a Tube: Double-Barrelled Ileostomy with Separation of the Stomas 1060
Ileostomy without a Tube: Stone Method 1062
Ileostomy without a Tube: Single-Barrelled Method 1066
Complications after Ileostomy 1072
Skin Grafting of Ileostomy Opening 1075
Closure of Enterostomy Stomas 1076
Closure of a Maydl Jejunostomy Stoma 1076
Closure of a Tangential, Loop or Double-Barrelled Ileostomy Stoma 1077
Closure of a Single-Barrelled Ileostomy Stoma 1079
Closure by the Intraperitoneal Route 1079
Summary of Enterostomy and Its Closure 1080
CLOSURE OF FISTULAS OF SMALL INTESTINE 1080
Closure of External Fistula 1080
Closure of Internal Intestinal Fistula 1089
Postoperative Care in Closure of Fecal Fistula 1091
Comments on Closure of Fecal Fistula 1092
PARTIAL ENTERECTOMY 1092
ANASTOMOSIS OF THE INTESTINE 1098
Lateral (Side-to-Side) Anastomosis after Enterectomy 1099
End-to-End Anastomosis 1107
End-to-Side Anastomosis 1132

此为试读,需要完整PDF请访问: www.ertongbook.com

Closed Side-to-Side Anastomosis 1135
Comparison of Intestinal Anastomoses 1135
OPERATIONS FOR SHORT-CIRCUITING (EXCLUSION, BY-PASSING) A SEGMENT OF INTESTINE 1137
Partial Short-Circuiting of a Segment of Small Intestine by Lateral Anastomosis between Its Limbs 1137
Partial Exclusion of a Loop of Bowel 1139
Complete (Bilateral) Exclusion of a Segment of Intestine 1139
INTESTINAL OBSTRUCTION 1140
Paralytic Ileus 1143
Dynamic (Spastic) Ileus 1145
Mechanical Intestinal Obstruction 1146
Intestinal Obstruction from Adhesions 1160
Plication of the Small Intestine for Adhesions (Noble) 1163
Immediate Postoperative Obstruction 1168
Intestinal Obstruction from External Hernia 1172
Intestinal Obstruction from Internal Hernia 1173
Obstruction of the Small Intestine by Foreign Bodies 1173
Volvulus of the Small Intestine (Not Due to Malrotation) 1173
Other Types of Mechanical Obstruction 1176
Intestinal Obstruction Due to Mesenteric Vascular Occlusion 1176
MALROTATION OF THE INTESTINE 1181
First Stage of Midgut Rotation 1181
Second Stage of Midgut Rotation 1182
Third Stage of Midgut Rotation 1186
Omphalocele Resulting from Failure of Rotation beyond the First Stage 1186
One-Stage Operation 1188
Two-Stage Operation (Gross) 1191
Nonrotation Resulting from Failure in Second Stage 1199
Operation for Duodenal Obstruction Caused by Nonrotation of the Midgut (Ladd) 1200
Congenital Volvulus of Midgut Resulting from Abnormality of Second Stage 1200
Malrotation during Second Stage of Midgut Rotation 1207
Internal Hernia Resulting from Abnormality of Second Stage 1209
Reversed Rotation 1214
Subhepatic Cecum 1215
Retrocecal Appendix 1217
Mobile Cecum 1217
CONGENITAL ATRESIA 1218
CONGENITAL STENOSIS OF THE INTESTINE AND COLON 1232
MECONIUM ILEUS 1239
Surgical Lavage of Intestine through a Tube 1241
Resection of Obstructed Segment of Ileum with End-to-End Anastomosis 1242
Witzel Enterostomy 1242
Mikulicz Resection with Ileocolostomy 1242
Mikulicz Resection and Double Ileostomy 1243
Results of Surgical Treatment by the Various Methods 1244

Convalescent Care Following Surgical Treatment 1245
DUPLICATIONS OF THE ALIMENTARY TRACT 1246
Surgical Treatments 1253
Duplications Arising in the Thorax 1253
Duplications in the Thorax Arising from Intestine 1254
Duplications of the Stomach 1255
Duplications of the Duodenum 1255
Duplication of the Intestine 1256
Duplications of the Colon and Rectum 1256
Results of Surgical Treatment 1259
MESENTERIC CYSTS 1259
MULTIPLE CYSTIC DISEASE OF THE MESENTERY 1262
OMENTAL CYSTS 1262
MECKEL'S DIVERTICULUM 1263
INTUSSUSCEPTION IN INFANTS AND CHILDREN 1271
Surgical Treatment 1275
Reducible Intussusception 1276
Irreducible or Gangrenous Intussusception 1280
Recurring Intussusception 1290
Results of Surgical Treatment 1291
Nonsurgical Treatment 1291
INTUSSUSCEPTION IN OLDER CHILDREN AND ADULTS 1295
REGIONAL ENTERITIS (CROHN'S DISEASE) 1297
Surgical Treatment 1306
Ileotransverse Colostomy with Transection of the Ileum 1307
One-Stage Resection 1308
Two-Stage Resections 1309
Comments on Surgical Treatment 1310
Recurrences 1312
REFERENCES 1314

Chapter 8

THE PERITONEUM, OMENTA AND MESENTERY 1319

ANATOMY 1319
OPERATIONS UPON THE PERITONEUM 1321
Surgical Treatment of Peritonitis 1321
Localized Peritonitis 1321
Diffuse Suppurative Peritonitis 1323
Prevention of Diffuse Peritonitis in Abdominal Injuries 1327
OPERATIONS ON THE GREAT OMENTUM 1328
Omental Grafting 1328
Partial or Complete Excision of the Great Omentum 1329
Operations for Torsion (Volvulus) of the Omentum 1329
Omentopexy for Cirrhosis of the Liver 1330
Removal of Cysts of the Omentum 1330
OPERATIONS UPON THE MESENTERY 1331
REFERENCES 1331

Chapter 9

THE COLON 1333

ANATOMY 1333
PHYSIOLOGY 1349
DEVELOPMENTAL ANOMALIES OF THE COLON 1352
DISEASES OF THE APPENDIX 1352
Appendicitis 1352
Acute Appendicitis 1353
Chronic and Chronically Recurring Appendicitis 1359
Appendiceal Abscess 1359
Other Lesions of the Appendix 1360
OPERATIONS UPON THE APPENDIX 1361
Appendectomy 1361
Drainage of Appendiceal Abscess 1371
Drainage of Pelvic Abscess 1373
Appendicostomy 1374
INJURIES OF THE COLON 1376
Surgical Treatment 1378
FOREIGN BODIES 1385
FECAL IMPACTION 1386
TUMORS OF THE COLON 1387
Benign Tumors 1387
Polyps or Multiple Polyps of the Colon 1388
Diffuse Familial (Multiple) Polyposis of the Colon 1393
Endometrioma (Adenomyoma) 1398
Other Benign Tumors of the Colon 1403
Malignant Tumors 1404
DIVERTICULA OF THE COLON 1416
DIVERTICULA OF CECUM 1434
PERSISTENT COLONIC FISTULAS 1435
Internal Persistent Colonic Fistula 1435
External Persistent Fecal Fistula 1436
NONSPECIFIC (IDIOPATHIC) ULCERATIVE COLITIS 1439
Pelvic Autonomic Neurectomy for Ulcerative Colitis 1461
CONGENITAL MEGACOLON (HIRSCHSPRUNG'S DISEASE) 1462
Surgical Treatment 1469
One-Stage Abdominoperineal Resection of Rectosigmoid (Swenson) 1470
Colostomy for Congenital Megacolon 1477
Partial Colectomy for Congenital Megacolon 1480
Lumbar Sympathectomy 1480
Paravertebral Sympathetic Block 1487
VOLVULUS OF THE SIGMOID 1489
VOLVULUS OF THE CECUM 1497
Operation for Volvulus of Cecum 1498
GENERAL CONSIDERATIONS IN OPERATIONS UPON THE COLON 1498
COLOTOMY 1500

COLOPEXY 1502
COLOSTOMY 1503
Temporary Tube Colostomies 1507
Tangential Colostomy 1509
Double-Barrelled Colostomies 1512
Loop Colostomy 1512
Spur Colostomy 1521
Terminal Single-Barrelled Colostomy 1530
Complications after Colostomy 1533
Comments on Colostomy 1538
Care of Bowel and Stoma Following Permanent Colostomy 1540
Intraperitoneal Closure of a Colostomy Stoma 1542
OPERATIONS FOR SHORT-CIRCUITING THE COLON 1545
RESECTION OF THE COLON 1549
Resection of the Right Colon 1551
One-Stage Resection of Right Colon 1553
Two-Stage Resection of Right Colon 1562
Three-Stage Resection of Right Colon 1565
Mikulicz Exteriorization Resection (Lahey Modification) ... 1566
Comments on Resection of Right Colon 1569
Resection of the Transverse Colon 1570
One-Stage Resection with Primary Anastomosis 1570
Multiple-Stage Resection of Transverse Colon 1577
Obstructive Resection of Transverse Colon (Rankin) 1578
Resection of the Descending Colon and Sigmoid 1581
One-Stage Resection with Primary End-to-End Anastomosis. 1581
Three-Stage Resection of Sigmoid (Schloffer) 1585
Mikulicz-Paul Resection of Sigmoid 1585
Other Methods 1587
Resection of Short Segment of Colon 1588
Colectomy 1589
One-Stage Colectomy with Ileostomy 1590
One-Stage Subtotal Colectomy with Ileorectotomy 1593
One-Stage Subtotal Colectomy with Ileostomy 1596
Total Colectomy with Anal Ileostomy and Preservation of Anal Sphincter (Ravitch) 1596
Two-Stage Total Colectomy with Permanent Ileostomy 1610
Two-Stage Subtotal Colectomy 1615
Three-Stage Total Colectomy with Ileostomy 1617
Four-Stage Total Colectomy 1622
Comments on Segmental, Partial, Subtotal and Total Colectomy ... 1625
REFERENCES 1629

CHAPTER 5

The Pancreas

ANATOMY

The pancreas is a soft, yellowish, elongated, hammer-head-shaped organ which lies deep in the epigastrium and left hypochondrium, extending transversely across the posterior abdominal wall from the concavity of the duodenum to the hilum of the spleen (Fig. 584). Because of its finely lobulated surface it resembles one of the larger salivary glands in appearance. Its average dimensions in the adult are 15 cm. in length by 3.1 cm. in width by 1.2 cm. in thickness.

The pancreas is situated between the lamina of the transverse mesocolon in a retroperitoneal position behind the peritoneal floor of the lesser peritoneal cavity, on the level of the second lumbar vertebra (sometimes the first and third); the stomach is in front, the duodenum to the right and the spleen to the left. The aorta, vena cava, celiac plexus, thoracic duct and diaphragmatic crura are immediately behind it.

Lesions of the pancreas cannot extend posteriorly; they extend forward into the lesser peritoneal sac.

Divisions

The pancreas, for descriptive purposes, may be divided into four anatomic divisions: the head, the neck, the body and the tail.

The *head,* or right extremity, has an inferior projection called the uncinate process, which gives it a globular shape and lies cradled in the concavity of the duodenum. The inferior margin of the uncinate process extends some distance below the general level of the rest of the gland. The right margin of the head is intimately apposed to the duodenum which actually grooves that portion of the substance of the gland. The terminal common bile duct passes through the substance of the head of the pancreas before entering the descending portion of the duodenum. The posterior surface of the head of the pancreas is in apposition with the inferior vena cava, the right ovarian or spermatic vein, the right renal vessels and the aorta.

The superior mesenteric vessels emerge from behind the neck of the pancreas and sometimes pass over the anterior surface of the lowermost portion of the inferior tip of the uncinate process. The antero-inferior surface of the head is covered by the first portion of the transverse colon.

Normally a good line of cleavage can be developed between the head of the pancreas and all these important structures, but inflammatory changes or malignant infiltration may destroy these lines of cleavage and make the dissection difficult or impossible.

The *neck* is a narrowed portion of the pancreas extending from the head to

the left where it joins the body of the gland. It is about 2.5 cm. in length and lies immediately posterior to the pylorus and the first portion of the duodenum. Its posterior surface is grooved by the origin of the portal vein which is formed by the junction of the superior mesenteric and splenic veins. These vessels cannot be sacrificed unless provision is made to anastomose the intestinal segment of the mesenteric vein to the vena cava, a formidable procedure. The close apportion of these vessels to the gland results in their frequently becoming involved by a malignant

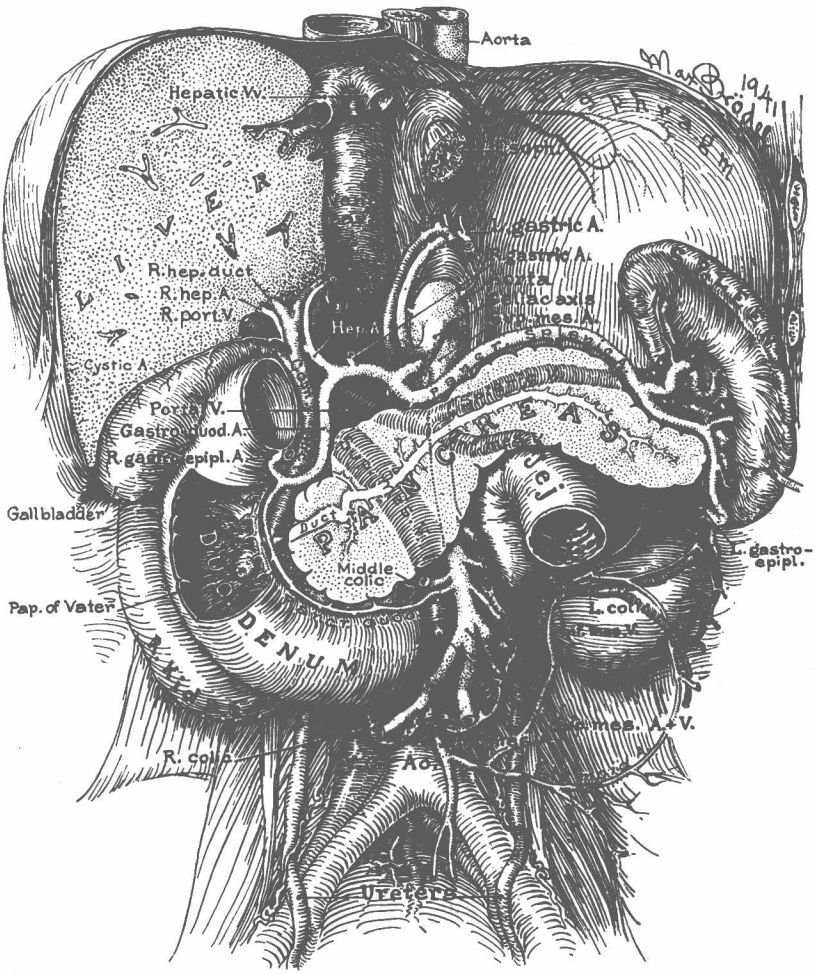

Fig. 584. Normal topography of the upper abdomen. (Trimble et al.: Surg., Gynec. & Obst., Vol. 73.)

growth in that area and thus jeopardizing the possibility of a cure by surgery. When not adherent because of inflammation or tumor, a line of cleavage between these vessels and the gland can usually be developed quite easily.

The *body* is the continuation to the left of the neck of the pancreas. It forms a well-marked anterior convexity across the vertebral column at, or a little below, the transpyloric plane. Without definite demarcation, the body emerges into the *tail,* which usually lies within the peritoneal duplication of the lienorenal ligament. The tail may or may not reach the hilus of the spleen.

此为试读,需要完整PDF请访问: www.ertongbook.com

Surfaces

The anterior surface of the body is flat, and is covered by the posterior parietal peritoneum which separates it from the posterior wall of the stomach, forming the lesser peritoneal sac. An acute inflammation of the pancreas may cause peritonitis and an effusion, which at first is limited to the lesser sac. If the epiploic foramen is affected simultaneously by inflammatory adhesions, the exudate may be confined to this region and give the physical signs of a tumor.

The inferior surface is covered by the posterior parietal peritoneum just before the latter turns forward to form the superior leaf of the transverse mesocolon; as a result, the inferior margin of the pancreatic body is closely related to the duodenojejunal junction on the right side and to the splenic flexure of the colon on the left.

The posterior surface of the body and tail of the pancreas lies astride of the aorta at the point of origin of the inferior mesenteric artery. It also passes over the left renal pedicle and the left kidney.

Pancreatic Ducts

These consist of the main pancreatic duct (canal of Wirsung) and the accessory pancreatic duct (duct of Santorini).

The *main pancreatic duct* begins at the tail of the pancreas and runs thence toward the head of the organ, passing nearer its posterior than its anterior aspect.

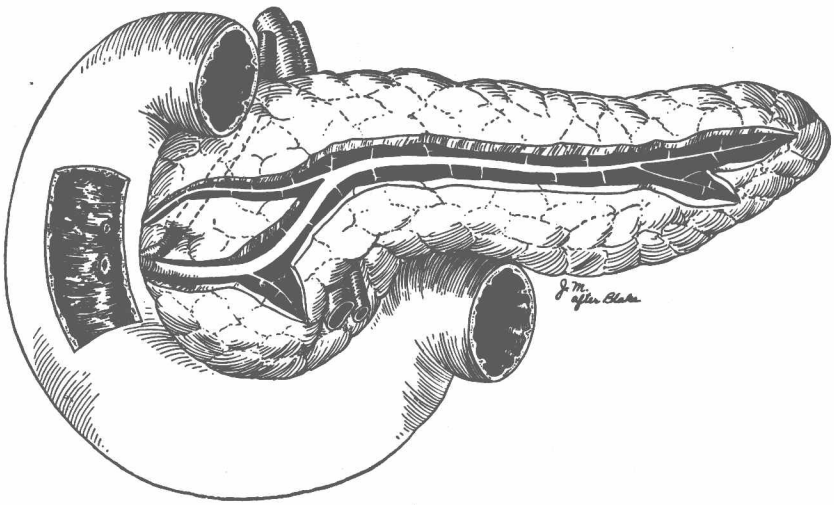

Fig. 585. Usual course and distribution of the pancreatic ducts. The papilla of Vater and the accessory papilla are shown. (Rienhoff & Pickrell: Arch. Surg., Vol. 51.)

After passing the neck, the duct turns downward, backward and to the right in the head and runs to the left side of the common bile duct. It enters the duodenal wall together with and parallel to the common bile duct, with which it unites while running obliquely in the walls of the duodenum and with which it empties by a common opening upon a papilla of mucous membrane about 10 cm. from the pylorus (Fig. 585). The opening is covered from above by a fold of mucous membrane. The main pancreatic duct may be recognized by its white color. Its diameter, near its termination, is between 2 and 3 mm. It usually drains the entire tail, body, neck and part of the head of the pancreas.

The *accessory pancreatic duct* may join the main duct near its termination, or may empty into the duodenum by a separate opening. It usually is much shorter than the main duct and courses through the ventral and cephalic portions of only the head of the gland.

Rienhoff and Pickrell[49] dissected the pancreatic and extrahepatic biliary ductal systems of 100 human beings and found that the accessory pancreatic duct was absent in only one instance, and that it communicated with the main duct in 89 of the subjects. In 61 per cent of their dissections the main duct drained the caudal portion of the head of the pancreas, leaving the remaining small portion of the head to be drained by the accessory duct. In 7 per cent the accessory duct drained the entire cephalic portion of the head while in 4 per cent it drained the greater portion of

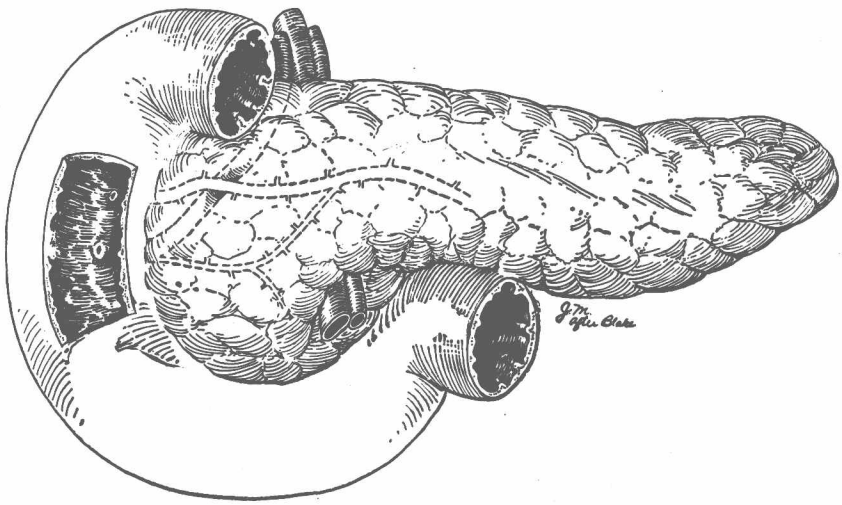

Fig. 586. Less common course of pancreatic ducts in which the duct of Santorini constitutes the major duct. (Rienhoff and Pickrell: Arch. Surg., Vol. 51.)

the head, leaving only the dorsal and caudal portions of the head to be drained by the main duct (Fig. 586).

Ampulla of Vater

The ampulla of Vater is a dilatation at the entrance of the common bile duct and pancreatic duct into the duodenum. The common bile duct and the main pancreatic duct may enter the duodenum through separate openings into a common papilla, or these two ducts may communicate with each other before emptying into the ampulla. Rienhoff and Pickrell[49] found that in their subjects the variations in this anatomic arrangement of the ampulla occurred in the incidence shown in Figure 587.

Sphincter of Oddi

The sphincter of Oddi controls the opening and closing of the outlet of the ampulla into the duodenum. It consists of muscle fibers that surround each duct, some of which surround both ducts. There is difference of opinion as to whether contraction of the sphincter simultaneously closes both ducts and thus prevents a common channel or whether it only closes the duodenal opening of the ampulla which when closed still permits a common channel for free communication between

the pancreatic and common bile ducts. Doubilet and Mulholland[19] reported that the latter was found to be true in 48 of 49 patients who were operated upon.

Papilla of Vater

The papilla of Vater (duodenal papilla) is an elevation of the duodenal mucous membrane at the point at which the ampulla of Vater empties into the duodenal lumen. It is most often situated on the posterolateral wall of the descending portion of the duodenum, but its position is variable. It can be distinguished only with

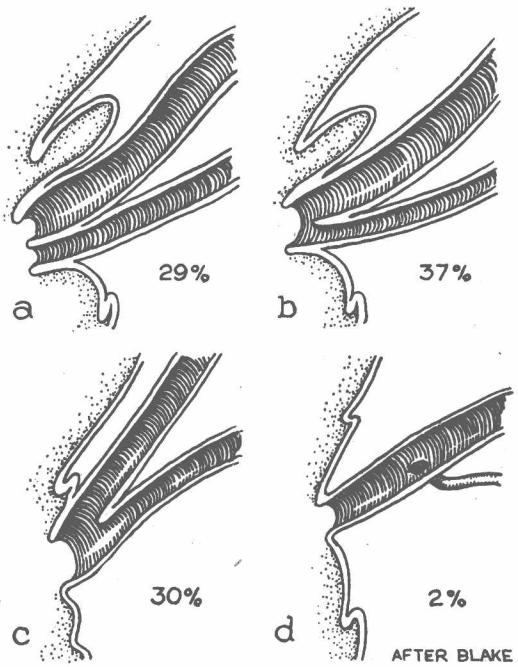

Fig. 587. Variations in terminations of the common bile and main pancreatic ducts. (Rienhoff and Pickrell: Arch. Surg., Vol. 51.)

difficulty by inspection of the internal surface of the duodenum, and is most easily identified by performing a choledochotomy and passing a probe down the common duct to the ampulla, after which transduodenal search for the papilla will reveal the tip of the probe protruding through the ampullary opening at the apex of the papilla.

Arteries

The pancreas receives its arterial supply by two branches from the gastroduodenal, two from the superior mesenteric and one from either the splenic, hepatic or celiac artery, as well as from a variable number of smaller tributaries of the splenic, hepatic and gastroduodenal arteries (see Fig. 146, p. 205).

The gastroduodenal artery arises from the hepatic artery in the gastrohepatic ligament at a point about 2 cm. above the superior margin of the pancreas and approximately in the same vertical plane as the pylorus. It runs downward and medial to the common bile duct to pass over the anterior surface of the head of the pancreas and posterior to the first portion of the duodenum to terminate in the right gastroepiploic and the superior pancreaticoduodenal arteries. The anterior

superior pancreaticoduodenal artery begins at the inferior margin of the first portion of the duodenum where it can be found by tracing back the more easily located right gastroepiploic artery to its origin. The anterior superior pancreaticoduodenal artery passes downward and traverses the sulcus between the head of the pancreas and the medial surface of the duodenum from above downward to meet and anastomose with the inferior pancreaticoduodenal artery which has arisen from the mesenteric artery and passed from below upward in this same sulcus. Thus the superior and inferior pancreaticoduodenal arteries form an anterior marginal artery along the medial surface of the duodenum and give off numerous small branches to the duodenum and to the head of the pancreas.

Before the gastroduodenal artery terminates it gives off the following branches:

1. The *posterior* superior pancreaticoduodenal artery which arises from the gastroduodenal at the superior margin of the duodenum and anterior to the common bile duct. It passes medially behind the head of the pancreas and posterior to the intrapancreatic portion of the common bile duct to anastomose with the posterior inferior pancreaticoduodenal artery which arises from the superior mesenteric artery and passes upward to meet it, forming a posterior marginal artery along the medial border of the duodenum.

2. The supraduodenal artery which is small and arises from the gastroduodenal at the superior margin of the duodenum to supply the superior and anterior portions of the first part of the duodenum.

3. The retroduodenal artery which is small and arises from the gastroduodenal at the same level or close to the supraduodenal. It courses along the posterior surface of the duodenum to supply the posterior wall of this part of the duodenum.

The anterior and posterior inferior pancreaticoduodenal arteries arise separately or by a common trunk from either the superior mesenteric artery or one of its primary branches. They not only anastomose with their corresponding superior pancreaticoduodenal arteries to form a marginal arcade to supply the duodenum and head of the pancreas as described above, but they also supply the duodenojejunal junction and adjacent parts of the neck of the pancreas.

Thus it can be seen that the head of the pancreas derives its chief arterial blood supply from the anterior and posterior marginal arcades formed by the anterior and posterior superior and inferior pancreaticoduodenal arteries as described above.

The neck, body and tail of the pancreas receive arterial blood from other sources.

The *superior pancreatic* artery is a small vessel which is often absent. When present, it most commonly arises from the splenic artery which courses transversely along the superior margin of the body and tail of the pancreas, but it may arise from the celiac axis, or from the hepatic, splenic or superior mesenteric artery. It courses along the superior border of the pancreas but is usually buried in the substance of the gland. It anastomoses with the inferior pancreatic artery.

The *inferior pancreatic* artery is also small but it is more constantly present than is the superior vessel. It may arise from the superior mesenteric, anterior superior or inferior pancreaticoduodenal, or the superior pancreatic artery. It passes through the substance of the body of the pancreas along the posterior inferior margin of the gland.

The body and tail of the pancreas also receive arterial blood from a number of branches of the splenic artery which leave that vessel at multiple points (see Fig. 146, p. 205), as it courses along the superior border of the pancreas, to pass

directly into the substance of the gland. These arteries are numerous, small and easily torn. Control of bleeding from them is tedious and often causes trouble when dissection is undertaken in this region.

Although the arterial supply to the pancreas is usually as described above, Falconer and Griffiths[21] found that variations were common (Fig. 588). Cattell and Warren[17] point out that in rare cases the main hepatic artery may arise from the

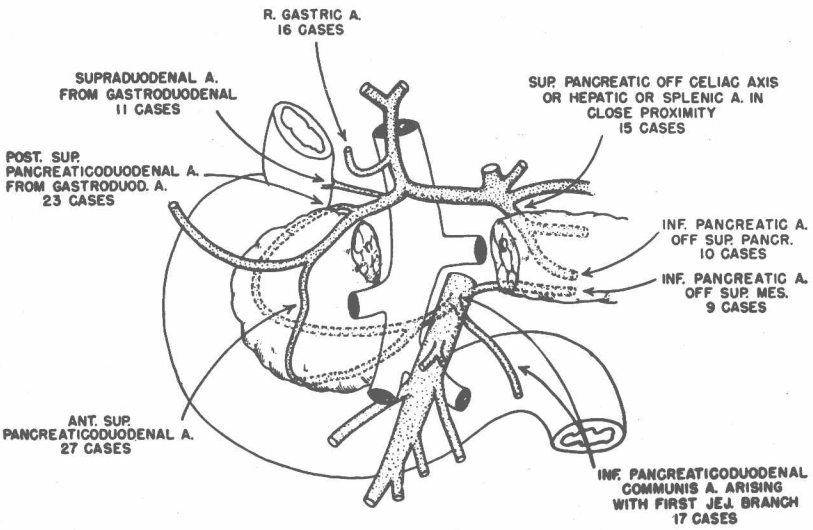

Fig. 588. Variations in origin of principal arteries to the pancreas. (Falconer and Griffiths: Brit. J. Surg., Vol. 37.)

superior mesenteric artery. Nonrecognition of this anomaly during dissection around the head of the pancreas may have serious consequences.

Veins

The venous blood of the pancreas drains into the portal system. The pattern of veins about the pancreas is most commonly as follows:

The portal vein is formed behind the neck of the pancreas by the junction of the superior mesenteric and splenic veins. These vessels groove the posterior surface of the pancreas, from which, however, they can easily be separated by blunt dissection unless inflammatory or neoplastic infiltration has destroyed the usual line of cleavage. Only occasionally is there a vein from the pancreas entering the anterior wall of the portal vein.

Falconer and Griffiths[21] found that the superior mesenteric vein was usually formed by the confluence of two main trunks, one running along each side of the superior mesenteric artery and uniting to form a single vessel at a variable distance before passing beneath the pancreas to join the splenic and form the portal vein.

The splenic vein runs transversely along the posterior surface of the superior margin of the pancreas to join the superior mesenteric vein and thus form the portal vein behind the pancreatic neck. During its course it receives numerous small venules that drain the body and tail of the pancreas. These venules are thin walled and may cause troublesome bleeding when dissection is made in their region.

The above-mentioned veins are constant in their presence and pattern.

The left gastric vein is constant in its presence but variable in its termination.

Falconer and Griffiths[21] found that it emptied into the splenic vein in 20 and into the splenoportal junction in 4 of their subjects.

The *inferior mesenteric vein* is also consistent in its presence, but variable in its termination. It passes from below upwards beneath the posterior surface of the body of the pancreas. Falconer and Griffiths found that it entered the splenic vein in 26 subjects and the superior mesenteric in 17.

The *right gastroepiploic vein* lies between the two peritoneal leaves of the gastrocolic ligament as it passes along the greater curvature of the stomach to join the superior mesenteric vein immediately beneath the neck of the pancreas. In its course it receives branches from the stomach, omentum, pylorus and the first portion of the duodenum. Just before its termination it is joined by the anterior superior pancreaticoduodenal and one or more colic veins to form what is called the gastrocolic trunk.

The *anterior superior pancreaticoduodenal vein* is formed in the pancreatoduodenal sulcus near the lower end of the second portion of the duodenum. It passes upward and medially in this sulcus to empty into the gastrocolic trunk. In its course it receives small thin-walled venules which drain the upper and anterior part of the head of the pancreas as well as the adjacent duodenum.

The *posterior superior pancreaticoduodenal vein* runs upward behind the intrapancreatic portion of the bile duct to enter the posterolateral aspect of the portal vein. It usually is of appreciable size and may be injured and cause troublesome bleeding in exposing the intrapancreatic portion of the common bile duct. The vessel can be ligated with impunity. It drains the upper posterior portion of the head of the pancreas, as well as the adjacent duodenum.

The *anterior inferior pancreaticoduodenal vein* is formed in the pancreatoduodenal sulcus near the origin of its superior counterpart and runs downward and medially in the substance of the pancreas to the lower margin of the uncinate process where it passes behind the superior mesenteric vessels to empty most commonly into the first jejunal vein near the latter's junction with the superior mesenteric vein. It drains the lower anterior part of the head of the pancreas and the adjacent duodenum.

The *posterior inferior pancreaticoduodenal vein* originates in the posterior pancreatoduodenal sulcus below the common bile duct and runs downward and medially around the lower edge of the uncinate process to empty into the first jejunal branch of the superior mesenteric vein. It drains the posterior portion of the lower part of the head of the pancreas.

The *inferior pancreatic vein* is fairly constant. It accompanies its artery along the posterior inferior border of the body of the pancreas and most frequently empties into the superior or inferior mesenteric veins, but may drain into the splenic vein or gastrocolic trunk instead.

A *pancreatic cervical vein* is inconstantly present. When present it is a short, wide vessel which leaves the inferior border of the neck of the pancreas to empty into the superior mesenteric vein.

The greater portion of the body and tail of the pancreas drains into the splenic vein by the short venules mentioned above.

As is the case with the arteries, the patterns described in the foregoing paragraphs are the most common (Fig. 589) but variations are frequent.

The vascular pattern of the pancreas has been described in detail because of its great surgical importance. It can be seen that the head of the pancreas and the

此为试读,需要完整PDF请访问: www.ertongbook.com