

影像学大师系列

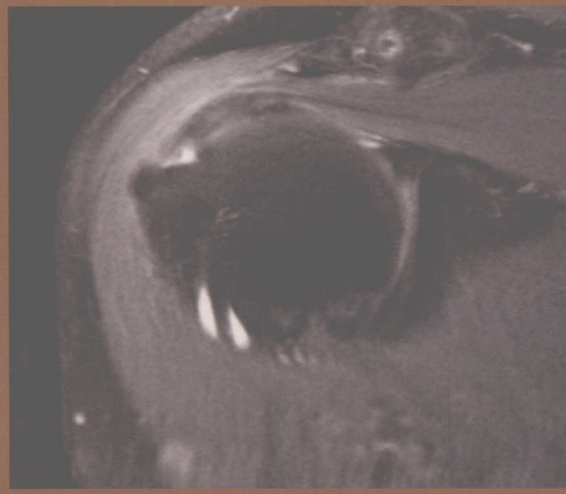
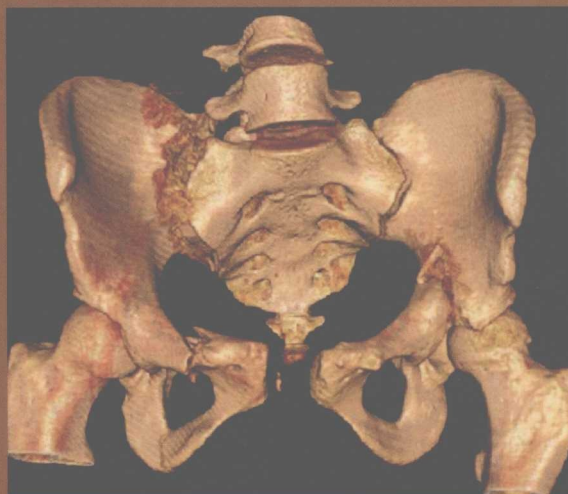
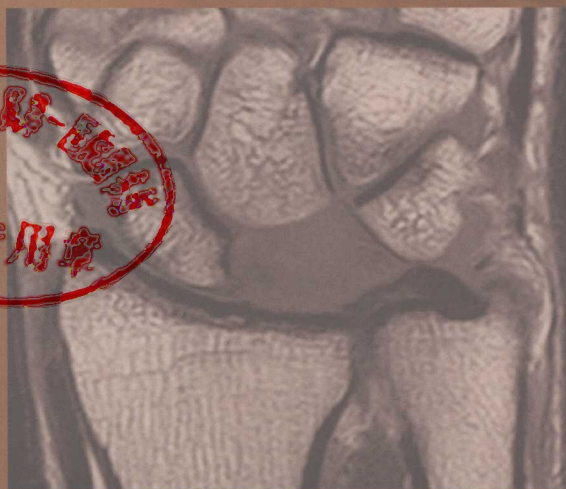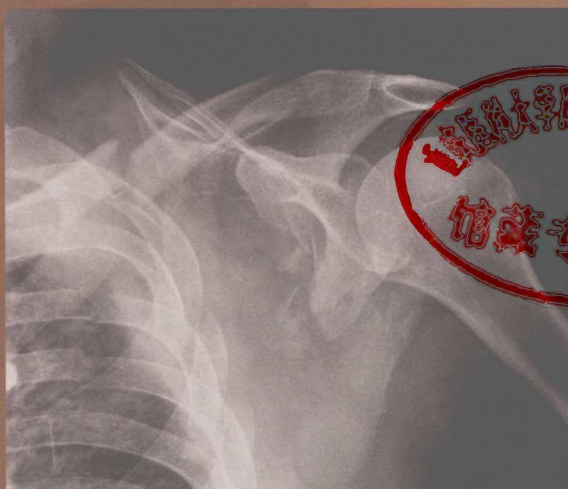# Musculoskeletal

## Imaging 2<sup>nd</sup> Edition

主编  
Thomas L. Pope, Hans L. Bloem, Javier Beltran  
William B. Morrison, David J. Wilson

主译 陆 勇 严福华 王绍武 王 蕾  
主审 陈克敏 江 浩

# 肌肉骨骼影像学



 上海科学技术出版社

ELSEVIER

影像学大师系列

# 肌肉骨骼影像学

Musculoskeletal Imaging (2<sup>nd</sup> Edition)

Thomas L. Pope Hans L. Bloem Javier Beltran  
William B. Morrison David J. Wilson

主译 陆 勇 严福华 王绍武 王 蕾  
主审 陈克敏 江 浩

上海科学技术出版社

## 图书在版编目(CIP)数据

肌肉骨骼影像学 / (美)托马斯·L·波普(Thomas L. Pope)  
等主编;陆勇等主译. —上海:上海科学技术出版社,2018.1

(影像学大师系列)

ISBN 978-7-5478-3732-0

I. ①肌… II. ①托…②陆… III. ①肌肉骨骼系统—  
影象诊断 IV. ①R680.4

中国版本图书馆 CIP 数据核字(2017)第 256205 号

## 肌肉骨骼影像学

主编 Thomas L. Pope Hans L. Bloem Javier Beltran

William B. Morrison David J. Wilson

主译 陆勇 严福华 王绍武 王蕾

上海世纪出版(集团)有限公司 出版、发行  
上海科学技术出版社

(上海钦州南路 71 号 邮政编码 200235 www.sstp.cn)

上海中华商务联合印刷有限公司 印刷

开本 889×1194 1/16 印张 76.75

字数: 2200 千字

2018 年 1 月第 1 版 2018 年 1 月第 1 次印刷

ISBN 978-7-5478-3732-0/R·1469

定价: 498.00 元

---

本书如有缺页、错装或损坏等严重质量问题,  
请向工厂联系调换

# ELSEVIER

Elsevier (Singapore) Pte Ltd.

3 Killiney Road

#08-01 Winsland House I

Singapore 239519

Tel: (65) 6349-0200

Fax: (65) 6733-1817

MUSCULOSKELETAL IMAGING, ED 2

Copyright © 2015, 2008 by Saunders, an imprint of Elsevier Inc.

ISBN 978-1-4557-0813-0

This translation of MUSCULOSKELETAL IMAGING, ED 2 by Thomas Pope, Hans Bloem, Javier Beltran, William Morrison and David Wilson, was undertaken by Shanghai Scientific & Technical Publishers and is published by arrangement with Elsevier (Singapore) Pte Ltd.

MUSCULOSKELETAL IMAGING, ED 2 by Thomas Pope, Hans Bloem, Javier Beltran, William Morrison and David Wilson 由上海科学技术出版社有限公司翻译,并根据上海科学技术出版社有限公司与爱思唯尔(新加坡)私人有限公司的协议约定出版。

肌肉骨骼影像学(主译 陆 勇 严福华 王绍武 王 蕾)

ISBN: 978-7-5478-3732-0

Copyright © 2017 by Elsevier (Singapore) Pte Ltd and Shanghai Scientific & Technical Publishers.

All rights reserved. No part of this publication may be reproduced or transmitted in any form or by any means, electronic or mechanical, including photocopying, recording, or any information storage and retrieval system, without permission in writing from Elsevier (Singapore) Pte Ltd. Details on how to seek permission, further information about Elsevier's permissions policies and arrangements with organizations such as the Copyright Clearance Center and the Copyright Licensing Agency, can be found at the website: [www.elsevier.com/permissions](http://www.elsevier.com/permissions).

This book and the individual contributions contained in it are protected under copyright by Elsevier (Singapore) Pte Ltd.

## 注 意

本译本由 Elsevier (Singapore) Pte Ltd. 和上海科学技术出版社有限公司完成。相关从业及研究人员必须凭借其自身经验和知识对文中描述的信息数据、方法策略、搭配组合、实验操作进行评估和使用。由于医学科学发展迅速,临床诊断和给药剂量尤其需要经过独立验证。在法律允许的最大范围内,爱思唯尔、译文的原文作者、原文编辑及原文内容提供者均不对译文或因产品责任、疏忽或其他操作造成的人身及/或财产伤害及/或损失承担责任,亦不对由于使用文中提到的方法、产品、说明或思想而导致的人身及/或财产伤害及/或损失承担责任。

Printed in China by Shanghai Scientific & Technical Publishers under special arrangement with Elsevier (Singapore) Pte Ltd. This edition is authorized for sale in the People's Republic of China only, excluding Hong Kong SAR, Macau SAR and Taiwan. Unauthorized export of this edition is a violation of the contract.



## 内容提要

Elsevier 出版社出版的“影像学大师系列”被业内奉为最经典的影像学专著,由国际最顶尖的影像学专家共同编写,代表着该领域的最高水准。*Musculoskeletal Imaging (second edition)*属于该系列中里程碑式的著作,主要内容包括肌肉骨骼疾病的 X 线、CT、MRI、核医学和超声影像学表现,以及影像学相关的临床、病理、生物力学的小结,并且以要点的形式总结了各类肌肉骨骼疾病的典型特征和影像学诊断须知。

《肌肉骨骼影像学》内容丰富全面,几乎涵盖了各类肌肉骨骼疾病的表现。其编写理念先进,侧重于疾病的影像学征象分析、鉴别诊断,特别突出强调了临床与影像学、生物力学与影像学的联系,从理念上进行了更新和开拓。本书兼顾临床、病理,提供了大量图片和相关要点分析。对于每天进行诊断和鉴别诊断的放射科、病理科和临床医师而言,本书具有重要的参考价值。对于其他对肌肉骨骼系统疾病感兴趣的读者来说,本书也是可读性很强的著作。



## 译者名单

- 主 译** 陆 勇 上海交通大学医学院附属瑞金医院  
严福华 上海交通大学医学院附属瑞金医院  
王绍武 大连医科大学附属第二医院  
王 蕾 上海交通大学医学院附属瑞金医院
- 主 审** 陈克敏 上海交通大学医学院附属瑞金医院  
江 浩 上海交通大学医学院附属瑞金医院
- 特约审稿** 杨庆铭 上海交通大学医学院附属瑞金医院  
杨程德 上海交通大学医学院附属瑞金医院
- 主译助理** 王晗琦 上海交通大学医学院附属瑞金医院  
陈 喆 上海交通大学医学院附属瑞金医院  
王文菁 上海交通大学医学院附属瑞金医院

### 译 者(按姓氏笔画排序)

- 丁晓毅 上海交通大学医学院附属瑞金医院  
万珊杉 云南昆钢医院  
王 黎 河北医科大学第二医院  
王凤丹 北京协和医院  
王巧丽 大连医科大学附属第二医院  
王戌娜 大连医科大学附属第二医院  
王忠敏 上海交通大学医学院附属瑞金医院  
王晗琦 上海交通大学医学院附属瑞金医院  
王慧燕 山西中医学院附属医院  
方字文 中山市中医院  
卢小婷 华中科技大学同济医学院附属协和医院(西院)  
田树平 海军总医院  
白爱国 上海国龙医院  
吕传剑 河南省人民医院  
朱 璐 湖南省人民医院  
朱建兵 苏州科技城医院  
任 钢 北京和睦家医院  
刘 伟 大连医科大学附属第二医院  
刘 衡 遵义医学院附属医院
- 刘元早 贵州省铜仁市人民医院  
许兵强 陕西省人民医院  
孙 闯 大连医科大学附属第二医院  
孙 珂 郑州大学第一附属医院  
孙文刚 华中科技大学同济医学院附属协和医院  
孙海艳 大连医科大学附属第二医院  
杜联军 上海交通大学医学院附属瑞金医院  
李 飞 郑州人民医院  
李 韬 郑州大学附属郑州中心医院  
李国权 重庆三峡中心医院  
李凯程 浙江中医药大学  
李建林 大连医科大学附属第二医院  
李建胜 深圳市宝安第二人民医院(集团)总医院  
李爱静 宁波市第二医院  
李智慧 上海长海医院  
李新华 山东省千佛山医院集团无棣医院  
杨 丽 复旦大学附属中山医院  
杨 敏 泸州市人民医院  
杨 超 大连医科大学附属第二医院

## 2 译者名单

- |     |                  |     |                     |
|-----|------------------|-----|---------------------|
| 杨先春 | 武汉科技大学附属汉阳医院     | 孟祥盼 | 东南大学                |
| 杨学东 | 中国中医科学院广安门医院     | 赵改菊 | 苏州市相城人民医院           |
| 吴 励 | 上海交通大学博士后流动站     | 赵倩楠 | 大连医科大学附属第二医院        |
| 余水莲 | 广西壮族自治区人民医院      | 赵婷婷 | 大连医科大学附属第三医院        |
| 狄 钰 | 同济大学附属同济医院       | 胡彦君 | 山西省人民医院             |
| 辛鸿婕 | 上海市第六人民医院东院      | 侯丽花 | 济宁市第一人民医院           |
| 沈沾荣 | 泸州市人民医院          | 侯美丹 | 大连医科大学附属第二医院        |
| 张 宁 | 南昌大学第一附属医院       | 秦 乐 | 上海交通大学医学院附属瑞金医院     |
| 张 冰 | 中国医科大学附属第四医院     | 高传平 | 青岛大学附属医院            |
| 张 堃 | 湖南中医药大学第一附属医院    | 高岩峰 | 内蒙古自治区肿瘤医院          |
| 张 越 | 天津市天津医院          | 郭冬梅 | 大连医科大学附属第二医院        |
| 张太娟 | 青岛市海慈医疗集团        | 陶 娟 | 大连医科大学附属第二医院        |
| 张丽娜 | 大连医科大学附属第一医院     | 黄小宁 | 南昌大学第二附属医院          |
| 张国平 | 陕西省人民医院          | 黄文荟 | 山西医科大学              |
| 张联合 | 武警浙江总队医院         | 盘中贤 | 深圳市中医院              |
| 陈 红 | 海南医学院第一附属医院      | 彭 虹 | 解放军总医院              |
| 陈 喆 | 上海交通大学医学院附属瑞金医院  | 彭俊萍 | 深圳龙岗中心医院            |
| 罗 宁 | 大连医科大学附属第二医院     | 彭娴婧 | 中南大学湘雅医院            |
| 季汉珍 | 南通大学附属南通第三人民医院   | 葛英霖 | 聊城市第二人民医院           |
| 周建收 | 中国人民解放军第 91 中心医院 | 蒋元文 | 新疆克拉玛依市中心医院         |
| 庞 婧 | 青岛大学附属医院         | 蒋梅花 | 上海交通大学医学院附属瑞金医院     |
| 庞小溪 | 北京大学第一医院         | 程少容 | 中国人民解放军武汉总医院        |
| 郑 丽 | 大连医科大学附属第二医院     | 程祖胜 | 浙江省绍兴市第七人民医院        |
| 郑 尉 | 天津体育学院           | 樊志红 | 湖南省人民医院(马王堆院区)      |
| 郑江龙 | 香港大学深圳医院         | 滕 剑 | 南京中医药大学附属江苏省中西医结合医院 |
| 郑邵微 | 大连医科大学附属第一医院     | 颜 凌 | 上海交通大学医学院附属瑞金医院     |

# Contributors

**Faustino A. Abascal, MD**

Department of Radiology  
Diagnóstico Médico Cantabria  
Santander, Spain  
*18 Soft Tissue Injuries of the Hand and Wrist*

**Judith E. Adams, MBBS, FRCR, FRCP**

Clinical Radiology  
Manchester Royal Infirmary & Manchester Academic  
Health Science Centre  
Manchester, Great Britain  
*77 Osteoporosis*

**Ronald S. Adler, MD, PhD**

Professor of Radiology  
NYU Langone Medical Center  
Department of Radiology  
New York, New York  
*12 Soft Tissue Injury to the Elbow*  
*35 Compressive and Entrapment Neuropathies of the Lower  
Extremity*

**Joong Mo Ahn, MD**

Associate Professor  
Department of Radiology  
University of Pittsburgh Medical Center  
Pittsburgh, Pennsylvania  
*40 Stress Injury*

**Jorge Albareda Albareda, MD**

Jefe de Servicio de Traumatología y Ortopedia  
Hospital Clínico Universitario  
Zaragoza, Spain  
*22 Acute Osseous Injury to the Hip and Proximal Femur*

**Sana Ali, MD**

Resident in Diagnostic Radiology  
Department of Diagnostic Imaging  
Maimonides Medical Center  
Brooklyn, New York  
*13 Normal Wrist*  
*82 Storage Diseases ( Mucopolysaccharidoses and Gly-  
cogenoses )*

**Gina M. Allen, BM, MFSEM, MSc (SEM), MRCP, MRCGP, FRCR**

Consultant Radiologist  
Oxford University Hospitals  
Consultant Radiologist  
St Lukes Radiology  
St Lukes Hospital  
Oxford, United Kingdom  
*73 Hemophilia and Related Disorders*  
*91 The Patient with a Soft-Tissue Lump*

**Arash Anavim, MD**

Assistant Clinical Professor and Residency Program  
Director  
Radiological Sciences  
University of California, Irvine  
Orange, California  
*122 Discography*

**Mark W. Anderson, MD**

Professor of Radiology and Orthopaedic Surgery  
Department of Radiology  
University of Virginia  
Charlottesville, Virginia  
*116 Normal Variants*

**Suzanne E. Anderson, MD, PhD**

Honorary Professor, Musculoskeletal Radiology  
Department of Diagnostic, Interventional and Paediatric  
Radiology  
Inselpital, University of Berne  
Berne, Switzerland  
Associate Professor  
Department of Radiology  
University of Melbourne  
Associate Professor  
Department of Medicine  
Royal Melbourne Hospital  
Melbourne, Australia  
*42 Complications of Osseous Trauma*

**Francisco Aparisi, MD**

Department of Radiology



Hospital Nueve de Octubre  
Valencia, Spain  
19 *The Normal Pelvis and Hip*  
20 *Acute Osseous Injury to the Pelvis and Acetabulum*

**Pilar Aparisi Gómez, MBChB, PQS Radiology, EFRANZCR**

Consultant Radiologist  
Department of Radiology  
Hospital Nueve de Octubre  
Valencia, Spain  
Consultant Radiologist  
Department of Radiology  
Auckland Hospital  
Auckland, New Zealand  
20 *Acute Osseous Injury to the Pelvis and Acetabulum*

**Derek R. Armfield**

Co-Founder, Vice Chairman, and President of Clinical  
Services  
Foundation Radiology, Inc.  
Vice Chairperson  
Department of Diagnostic Imaging  
Jefferson Regional Medical Center  
Pittsburgh, Pennsylvania  
109 *Postoperative Hip*

**Bridget Atkins, MA, MBBS, MSc, FRCPath, FRCP**

Consultant, Infectious Diseases and Microbiology  
Oxford University Hospitals NHS Trust  
Consultant ID Physician (Hon), Bone Infection Unit  
Nuffield Orthopaedic Centre  
Senior Lecturer (Hon)  
The University of Oxford  
Training Programme Director  
Infectious Diseases and Microbiology  
Oxford Deanery  
Oxford, United Kingdom  
64 *Soft Tissue Infection: Cellulitis, Pyomyositis, Abscess,  
Septic Arthritis*

**Jonathan C. Baker, MD**

Assistant Professor of Radiology  
Mallinckrodt Institute of Radiology  
Washington University School of Medicine  
St. Louis, Missouri  
111 *Postoperative Ankle and Foot*

**Lisa O. Ballehr, DO**

Diagnostic Radiologist  
Arizona Advanced Imaging Center  
Mesa, Arizona  
30 *The Normal Ankle and Foot*

**Romulo Baltazar, MD**

Attending Radiologist  
Imaging Subspecialists of North Jersey  
St. Joseph's Regional Medical Center

Paterson, New Jersey  
89 *Drug-Related Bone and Soft Tissue Disorders*

**Laura Bancroft, MD**

Chief of MSK Radiology  
Department of Radiology  
Florida Hospital  
Orlando, Florida  
Adjunct Professor  
University of Central Florida School of Medicine  
Orlando, Florida  
Clinical Professor  
Florida State University School of Medicine  
Tallahassee, Florida  
113 *Complications of Infection*

**Chad H. Barker, MD**

Musculoskeletal Radiology Fellow  
Department of Radiology  
University of Kentucky  
Lexington, Kentucky  
113 *Complications of Infection*

**Michelle A. Barr, MD**

Associate Professor of Radiology  
Department of Radiology  
University of Virginia  
Charlottesville, Virginia  
121 *Spinal Injections*

**Andrea Baur-Melnyk, MD**

Associate Professor of Radiology  
Section Chief of Department of Clinical Radiology  
Ludwig Maximilian University of Munich-Grosshadern  
Munich, Germany  
93 *Myeloma*

**Francesca Beaman, MD**

Assistant Professor of Radiology, Division Chief  
Musculoskeletal Radiology, Program Director  
Musculoskeletal Radiology Fellowship, Assistant  
Program Director Radiology Residency  
Department of Radiology  
University of Kentucky  
Lexington, Kentucky  
113 *Complications of Infection*

**Javier Beltran, MD, FACR**

Chairman  
Department of Radiology  
Maimonides Medical Center  
Brooklyn, New York  
Clinical Director of Musculoskeletal Radiology  
Radisphere National Radiology Group  
Beachwood, Ohio  
6 *Normal Shoulder*  
12 *Soft Tissue Injury to the Elbow*

*17 Compressive and Entrapment Neuropathies of the Upper Extremities*

*35 Compressive and Entrapment Neuropathies of the Lower Extremity*

*89 Drug-Related Bone and Soft Tissue Disorders*

**Luis S. Beltran, MD**

Assistant Professor of Radiology  
Department of Radiology  
New York University Langone Medical Center  
New York, New York

*17 Compressive and Entrapment Neuropathies of the Upper Extremity*

*35 Compressive and Entrapment Neuropathies of the Lower Extremity*

*88 Tuberos Sclerosis*

**Jenny T. Bencardino, MD**

Associate Professor of Radiology  
New York University School of Medicine  
New York, New York

*12 Soft Tissue Injury to the Elbow*

*17 Compressive and Entrapment Neuropathies of the Upper Extremity*

**Donna G. Blankenbaker, MD**

Professor  
Department of Radiology  
University of Wisconsin School of Medicine and Public Health

Madison, Wisconsin

*4 Cervical Spine Injuries*

**Hans L. Bloem, MD, PhD**

Professor and Chairman  
Department of Radiology  
Leiden University Medical Center  
Leiden, The Netherlands

*65 Appendicular Infection*

*90 The Patient with a Tumor or a Tumor-Like Lesion of Bone*

*99 Staging Bone and Soft Tissue Tumors*

*100 Monitoring Therapy in Bone and Soft Tissue Tumors*

**Marcy B. Bolster, MD**

Associate Professor of Medicine  
Harvard Medical School  
Division of Rheumatology  
Massachusetts General Hospital  
Boston, Massachusetts

*48 Rheumatoid Arthritis*

**Peyman Borghei**

Research Fellow  
Diagnostic Radiology  
University of California Irvine  
Orange, California

*122 Discography*

**Cedric Boulet, MD**

Department of Radiology  
Universitair Ziekenhuis Brussel  
Brussels, Belgium

*10 Normal Elbow*

**Patrick A. Brouwer, MD, MSc**

Neurovascular Network NorthSea  
Department of Radiology  
Leiden University Medical Center  
Leiden, The Netherlands

*124 Percutaneous Intradiscal Therapies*

**Elliott Brown, MD**

Assistant Professor  
Department of Diagnostic Radiology  
Yale University School of Medicine  
New Haven, Connecticut

*15 Internal Derangement of the Wrist*

**Ángel Bueno, MD**

Hospital Universitario Fundación Alcorcón  
Madrid, Spain

*Appendix 3 Fractures with Names*

**Michele Calleja, MD, FRCR**

Consultant Musculoskeletal Radiologist  
Radiology Department  
Royal National Orthopaedic Hospital  
Stanmore, United Kingdom

*103 Coalitions*

**Ana Canga, MD**

Departments of Radiology and of Anatomy and Cellular Biology

University of Cantabria

Marqués de Valdecilla University Hospital  
Santander, Spain

*18 Soft Tissue Injuries of the Hand and Wrist*

*34 Soft Tissue Injuries to the Ankle : Osteochondral Injuries and Impingement*

*103 Coalitions*

**Fabiano Nassar Cardoso, MD**

Musculoskeletal Radiology Assistant  
Department of Diagnostic Imaging  
Universidade Federal de São Paulo-UNIFESP  
São Paulo, Brazil

*44 Complex Regional Pain Syndrome*

*71 General Principles of Magnetic Resonance Imaging of the Bone Marrow*

*72 Ischemic Bone Lesions*

**Victor Cassar-Pullicino, FRCR**

Consultant Radiologist  
Robert Jones and Agnes Hunt Orthopaedic Hospital  
Oswestry, Shropshire

United Kingdom  
*66 Spinal Infection*

**Conrado Furtado de Albuquerque Cavalcanti, MD**

Section Chief, MRI Imaging  
Hospital Sírio-Libanês  
São Paulo, Brazil  
*44 Complex Regional Pain Syndrome*

**Luis Cerezal, MD**

Head  
Radiology Department  
Diagnóstico Médico Cantabria (DMC)  
Santander, Spain  
*18 Soft Tissue Injuries of the Hand and Wrist*  
*34 Soft Tissue Injury to the Ankle; Osteochondral Injuries and Impingement*

**Russell W. Chapin, MD**

Assistant Professor  
Department of Radiology and Radiological Sciences  
Medical University of South Carolina  
Charleston, South Carolina  
*37 Lower Extremity Injuries in Children*

**Qi Chen, MD**

Department of Radiology  
SUNY Downstate Medical Center  
Brooklyn, New York  
*6 Normal Shoulder*

**Yvonne Y. Cheung, MD, MS**

Associate Professor of Radiology  
Dartmouth Hitchcock Medical Center  
Dartmouth Medical School  
Lebanon, New Hampshire  
*32 Soft Tissue Injury to the Ankle; Ligament Injuries*

**Aaron Cho, MD**

Staff Neuroradiologist  
Department of Radiology  
Naval Medical Center San Diego  
San Diego, California  
*Appendix 2 Orthopedic Devices*

**Kishore K. Chundru, MD candidate**

Radiology Resident  
St. Luke's-Roosevelt Hospital  
New York, New York  
*80 Pituitary and Thyroid Disorders*

**Usha Chundru, MD, MBA**

Staff Radiologist  
Department of Radiology  
Maimonides Medical Center  
Brooklyn, New York  
*28 Internal Derangement of the Knee; Tendon Injuries*

**Christine B. Chung, MD**

Associate Professor of Radiology  
University of California School of Medicine  
Professor of Radiology  
Veterans Affairs Medicine Center  
San Diego, California  
*108 Postoperative Elbow, Wrist, and Hand*

**Claire Coggins, MD**

Owner  
Claire Coggins, MD P.A.  
Subspecialty Musculoskeletal Radiology  
Wilmington, DE  
*58 Ochronosis*  
*59 Diffuse Idiopathic Skeletal Hyperostosis and Ossification of the Posterior Longitudinal Ligament*

**Antonio Cruz, MD**

Department of Arthroscopic Surgery  
Hospital Mutua Montañesa  
Santander, Spain  
*34 Soft Tissue Injury to the Ankle; Osteochondral Injuries and Impingement*

**Christian Czerny, MD**

Department of Radiology  
General Hospital and Medical University of Vienna  
Vienna, Austria  
*23 Internal Derangement of the Hip and Proximal Femur*

**Richard H. Daffner, MD, FACR**

Emeritus Clinical Professor of Radiology  
Temple University School of Medicine  
Department of Diagnostic Radiology  
Allegheny General Hospital  
Pittsburgh, Pennsylvania  
*4 Cervical Spine Injuries*

**Melvin D'Anastasi, MD**

Institute for Clinical Radiology  
Ludwig Maximilian University of Munich-Grosshadern  
Munich, Germany  
*93 Myeloma*

**A. Mark Davies, MBChB, DMRD, FRCR**

Consultant Radiologist  
Department of Imaging  
Royal Orthopaedic Hospital  
Birmingham, United Kingdom  
*92 Primary Bone Tumors*  
*94 Tumor-Like Lesions of Bone*

**Kirkland W. Davis, MD**

Section Chief  
Musculoskeletal Imaging and Intervention  
Department of Radiology  
University of Wisconsin School of Medicine and Public

## Health

Madison, Wisconsin

4 *Cervical Spine Injuries*106 *Principles and Complications of Orthopedic Hardware***Milko C. de Jonge, MD, BSc**

Department of Radiology

Zuwe Hofpoort Hospital

Woerden, The Netherlands

Department of Plastic, Reconstructive, and Hand  
Surgery

Academic Medical Center

University of Amsterdam

Amsterdam, The Netherlands

5 *Injury of the Thoracic Cage and Thoracolumbar Spine***Michel O. De Maeseneer, MD, PhD**

Professor of Radiology

University Hospital Brussels

Brussels, Belgium

24 *Normal Knee***Arthur De Schepper, Sr., MD, PhD<sup>†</sup>**

Professor of Radiology

University Hospital Antwerp

Antwerp University

Antwerp, Belgium

Department of Radiology

Leiden University Medical Center

The Netherlands

95 *Soft Tissue Tumors*96 *Tumor-Like Soft Tissue Lesions***José Luis del Cura, MD, PhD**

Associate Professor

Surgery, Radiology, and Physical Medicine

Basque Country University

Department of Radiology

Hospital de Baurto-Basurtoko Ospitalea

Bilbao, Spain

Appendix 1 *Measurements Most Frequently Used in Orthopedic  
Imaging***Bradley N. Delman, MD**

Associate Professor

Department of Radiology

Icahn School of Medicine at Mount Sinai

New York, New York

3 *Imaging of Facial and Skull Trauma***Sachin Dheer, MD**

Director, Musculoskeletal Imaging and Intervention

Department of Radiology

Kennedy Health System

Cherry Hill, New Jersey

60 *Gout***Grégory Dieudonné, MD**

Assistant Professor

Departments of Imaging Sciences and Orthopedics

University of Rochester School of Medicine and Dentistry

Strong Memorial Hospital

Rochester, New York

9 *Glenohumeral Instability***Joseph Dobtsis, MD**

Director of Neuroradiology and Musculoskeletal Radiology

21st Century Radiology

Brooklyn, New York

80 *Pituitary and Thyroid Disorders*118 *Percutaneous Biopsy of the Appendicular Skeleton*119 *Percutaneous Biopsy of the Spine***Brendan T. Doherty, MD**Division of Musculoskeletal and General Diagnostic  
Radiology

Thomas Jefferson Hospital

Philadelphia, Pennsylvania

1 *General Imaging Principles*63 *Non-Inflammatory Intraarticular Pathology***Rodrigo Dominguez, MD**

Professor of Radiology, Retired

Maimonides Medical Center

Brooklyn, New York

80 *Pituitary and Thyroid Disorders*82 *Storage Diseases (Mucopolysaccharidoses and Glycogenoses)***Davide Maria Donati, MD**

Professor

University of Bologna

Head of the III Clinic Unit

Rizzoli Orthopaedic Institute

Bologna, Italy

98 *Treatment Strategies for Musculoskeletal Tumors and  
Tumor-Like Lesions***Seema Döring, MD**

Department of Radiology

Universitair Ziekenhuis Brussel

Brussels, Belgium

10 *Normal Elbow***Nimisha Dorshi, MD**

Resident of Diagnostic Radiology

Department of Diagnostic Imaging

Maimonides Medical Center

Brooklyn, New York

82 *Storage Diseases (Mucopolysaccharidoses and Glycogenoses)*<sup>†</sup> Deceased.

**Hassan Douis, MD, MRCP**

Clinical Fellow in Musculoskeletal Radiology  
Department of Radiology  
The Royal National Orthopaedic Hospital NHS Trust  
Stanmore, United Kingdom  
*92 Primary Bone Tumors*  
*94 Tumor-Like Lesions of Bone*

**Aija Dzirkale, MD**

Radiology Center  
Riga East University Hospital  
Riga, Latvia  
*107 Postoperative Shoulder*

**Georges Y. El-Khoury, MD, FACR**

Professor of Radiology and Orthopaedics  
University of Iowa Carver College of Medicine  
Director, Section of Musculoskeletal Radiology  
University of Iowa Hospitals and Clinics  
Iowa City, Iowa  
*40 Stress Injury*

**Ilze Engele, MD**

Department of Radiology  
Riga Stradins University  
Riga East University Hospital  
Riga, Latvia  
*57 Hemochromatosis*  
*85 Paget Disease*

**Ana M. Hualde Enguita, MD**

Servicio de Traumatología y Ortopedia  
Hospital Universitario Miguel Servet  
Zaragoza, Spain  
*22 Acute Osseous Injury to the Hip and Proximal Femur*

**Mara Epermane, MD**

Chief  
Radiology Center  
Riga East University Hospital  
Riga, Latvia  
*85 Paget Disease*

**Christopher J. Fang, MBBCh, FRCR**

Musculoskeletal Radiologist  
Department of Clinical Radiology  
Royal Derby Hospital  
Derby, United Kingdom  
*73 Hemophilia and Related Disorders*

**Laura M. Fayad, MD**

Associate Professor of Radiology, Orthopaedic Surgery,  
and Oncology  
Director of Translational Research for Advanced Imaging  
The Russell H. Morgan Department of Radiology and  
Radiological Science  
Johns Hopkins University School of Medicine

Baltimore, Maryland

*112 Imaging of the Residual Limb after Amputation*

**Steven Finden, MD, DDS**

Department of Radiology  
Thomas Jefferson University Hospital  
Philadelphia, Pennsylvania  
*114 Temporomandibular Joint*

**Donald J. Flemming, MD**

G. Victor Rohrer Professor of Radiology Education  
Professor of Radiology and Orthopedics  
Penn State Hershey Medical Center  
Hershey, Pennsylvania  
*97 Metastatic Disease*

**Jürgen Freyschmidt, MD**

Professor  
Consulting Center for Skeletal Radiology  
Central Hospital Bremen-Mitte  
Bremen, Germany  
*49 Psoriatic Arthritis and Psoriatic Spondyloarthropathy*  
*52 Progressive Scleroderma*

**Jan L. Gielen, MD**

Department of Radiology  
Antwerp University Hospital  
Antwerp, Belgium  
*96 Tumor-Like Soft Tissue Lesions*

**Angela Gessner Gopez, MD, BS**

Assistant Professor of Radiology  
Department of Radiology  
Jefferson Medical College  
Thomas Jefferson University Hospital  
Philadelphia, Pennsylvania  
*Appendix 2 Orthopedic Devices*

**Tetyana Gorbachova, MD**

Clinical Assistant Professor  
Department of Radiology  
Albert Einstein Medical Center  
Philadelphia, Pennsylvania  
*81 Gaucher Disease*

**Andrew J. Grainger, BM BS, MRCP, FRCR**

Consultant and Honorary Senior Lecturer  
Department of Musculoskeletal Radiology  
Leeds Teaching Hospitals  
Leeds, United Kingdom  
*43 Muscle Injury and Sequelae*

**Andrew H. Haims, MD**

Associate Professor  
Departments of Diagnostic Radiology and Orthopaedics  
and Rehabilitation  
Co-Director, Musculoskeletal Imaging



Yale University School of Medicine  
New Haven, Connecticut  
15 *Internal Derangement of the Wrist*

**Joseph Hanono, MD**

Radiology Resident  
Maimonides Medical Center  
Brooklyn, New York  
118 *Percutaneous Biopsy of the Appendicular Skeleton*  
119 *Percutaneous Biopsy of the Spine*

**Faye N. Hant, DO, MSCR**

Assistant Professor of Medicine  
Division of Rheumatology and Immunology  
Medical University of South Carolina  
Charleston, South Carolina  
48 *Rheumatoid Arthritis*

**John H. Harris, Jr., MD, DSc**

Professor Emeritus  
Department of Diagnostic and Interventional Radiology  
The University of Texas Medical School at Houston  
Houston, Texas  
2 *General Principles of Osseous Injury*

**Curtis W. Hayes, MD, FACR**

Professor of Radiology and Orthopedic Surgery  
Department of Radiology  
Virginia Commonwealth University Health System  
Richmond, Virginia  
58 *Ochronosis*  
59 *Diffuse Idiopathic Skeletal Hyperostosis and Ossification of the Posterior Longitudinal Ligament*

**Tamara Miner Haygood, PhD, MD**

Associate Professor  
Department of Diagnostic Radiology  
University of Texas M.D. Anderson Cancer Center  
Houston, Texas  
41 *Radiation Effects in the Musculoskeletal System*

**Victoria Higuera, MD**

Department of Radiology  
Hospital de la Ribera  
Alzira, Valencia  
Spain  
20 *Acute Osseous Injury to the Pelvis and Acetabulum*

**Siegfried Hofmann, MD, PhD**

Associate Professor of Orthopaedic Surgery  
General and Orthopedic Clinic-Stolzalpe  
Stolzalpe, Austria  
23 *Internal Derangement of the Hip and Proximal Femur*

**Peter Hrehorovich, MD**

Radiologist  
Florida Hospital Heartland Medical Center

Sebring, Florida  
14 *Acute Osseous Injury to the Wrist*  
16 *Acute Osseous Trauma to the Hand*

**Maya Sardjono Hsieh, BS, MD**

Department of Radiology  
Maimonides Medical Center  
Brooklyn, New York  
28 *Internal Derangement of the Knee; Tendon Injuries*

**Wouter C. J. Huysse, MD**

Musculoskeletal Radiologist  
Department of Radiology  
Ghent University Hospital  
Ghent, Belgium  
29 *Internal Derangement of the Knee; Cartilage and Osteochondral Injuries*

**Hakan Ilaslan, MD**

Associate Professor  
Department of Radiology  
Cleveland Clinic Lerner College of Medicine  
Cleveland, Ohio  
87 *Sarcoidosis*

**Karsten Jablonka, MD**

Department of Pediatric Radiology  
University of Giessen  
Giessen, Germany  
Head, Department of Pediatric Radiology  
Klinikum Bremen-Mitte  
Bremen, Germany  
49 *Psoriatic Arthritis and Psoriatic Spondyloarthritis*  
52 *Progressive Scleroderma*

**Neda Jafarian, MD**

Resident Physician  
Department of Radiology  
Maimonides Medical Center  
Brooklyn, New York  
8 *Shoulder Impingement Syndromes*

**Steven L. J. James, MBChB, FRCR**

Consultant Musculoskeletal Radiologist  
Department of Imaging  
The Royal National Orthopaedic Hospital NHS Trust  
Birmingham, United Kingdom  
92 *Primary Bone Tumors*  
94 *Tumor-Like Lesions of Bone*

**Ann M. Johnson, MD**

Associate Professor of Clinical Radiology  
Perelman School of Medicine at the University of Pennsylvania  
Children's Hospital of Philadelphia  
Philadelphia, Pennsylvania  
38 *Upper Extremity Injuries in Children*

**Karl Johnson, BSC, MB ChB, MRCP, FRCR**

Radiologist  
Birmingham Children's Hospital  
Birmingham, United Kingdom  
*55 Juvenile Idiopathic Arthritis*

**Maria Bernadette Johnson, MBChB, FRCR**

Consultant Musculoskeletal Radiologist  
Ealing Hospital  
London, United Kingdom  
*43 Muscle Injury and Sequelae*

**Apostolos Karantanas, MD, PhD**

Associate Professor of Radiology  
University of Crete  
Chairman  
Department of Medical Imaging  
University Hospital  
Heraklion, Greece  
*75 Thalassemia*

**David Karasick, MD, FACR**

Professor of Radiology  
Department of Radiology  
Thomas Jefferson University  
Philadelphia, Pennsylvania  
*25 Acute Osseous Injury to the Knee*

**Theodoros F. Katsivas, MD**

Assistant Professor  
Department of Medicine  
Division of Infectious Diseases  
San Diego, California  
*69 HIV Infection and AIDS*

**Eoin C. Kavanagh, FRR, RCSI, FRCPI**

UCD Associate Clinical Professor  
Consultant Radiologist  
Mater Misericordiae University Hospital  
Cappagh National Orthopaedic Hospital  
Dublin, Ireland  
*76 Myelofibrosis*  
*109 Postoperative Hip*

**Theodore E. Keats, MD<sup>†</sup>**

Alumni Professor  
Department of Radiology  
University of Virginia  
Professor of Radiology  
University of Virginia Health Sciences  
Charlottesville, Virginia  
*116 Normal Variants*

**Shah H. M. Khan, MB BS, FRCR, MSK DIP (ESSR)**

Consultant Radiologist

Department of Radiology  
East Lancashire Hospitals NHS Trust, Blackburn  
Senior Clinical Lecturer  
Department of Radiology  
University of Central Lancashire  
Preston, United Kingdom  
*65 Appendicular Infection*

**Valeriy Kheyfits, MD**

Assistant Professor  
Department of Imaging Sciences  
University of Rochester School of Medicine and  
Dentistry  
Strong Memorial Hospital  
Rochester, New York  
*9 Glenohumeral Instability*

**Gabrielle P. Konin, MD**

Assistant Professor  
Department of Radiology and Imaging  
Weill Cornell Medical College  
Assistant Attending Radiologist  
Hospital for Special Surgery  
New York, New York  
*67 Diabetic Pedal Infection*

**George Koulouris, MBBS, GrCertSpMed, MMed(Radiology), FRANZCR**

Radiologist  
Melbourne Radiology Clinic  
Melbourne, Australia  
*109 Postoperative Hip*

**Josef Kramer, MD, PhD, MSc**

Roentgeninstitut am Schillerpark  
Linz, Austria  
*23 Internal Derangement of the Hip and Proximal Femur*

**Mark J. Kransdorf, MD**

Department of Radiology  
Mayo Clinic  
Phoenix, Arizona  
*117 Biopsy: Soft Tissue*

**Herman M. Kroon, MD**

Radiologist, Department of Radiology  
Department of Radiology  
Leiden University Medical Center  
Leiden, The Netherlands  
*90 The Patient with a Tumor or a Tumor-Like Lesion of Bone*  
*99 Staging Bone and Soft Tissue Tumors*

**Dylan C. Kwait, MD**

Radiologist

<sup>†</sup> Deceased.

Department of Diagnostic Imaging  
Maimonides Medical Center  
Brooklyn, New York  
*13 Normal Wrist*

**Radhesh Lalam, MBBS, MRCS, FRCR**

Consultant Radiologist  
Department of Diagnostic Radiology  
The Robert Jones and Agnes Hunt Orthopaedic and  
District Hospital NHS Foundation Trust  
Oswestry, Shropshire  
United Kingdom  
*45 Degenerative Disorders of the Spine*

**Susanne W. Y. Lardenoije, MD**

Department of Radiology  
Radboud University Medical Center  
Nijmegen, the Netherlands  
*39 Skeletal Manifestations of Pediatric Nonaccidental Injury*

**Hans P. Ledermann, MD**

IMAMED Radiologie Nordwest  
Basel, Switzerland  
*67 Diabetic Pedal Infection*

**Scott S. Lenobel, MD**

Clinical Instructor  
Department of Radiology  
The Ohio State University Wexner Medical Center  
Columbus, Ohio  
*7 Osseous Injuries of the Shoulder Girdle*

**Brandon Y. Liu, MD**

Diagnostic Radiologist  
Department of Medical Imaging  
Swedish Medical Center  
Radia Medical Imaging, Inc.  
Everett, Washington  
*11 Acute Osseous Injury of the Elbow and Forearm*

**Eva Llopis, MD**

Coordinator, Musculoskeletal Section  
Servicio de Radiología  
Hospital Universitario de la Ribera  
Valencia, Spain  
*18 Soft Tissue Injuries of the Hand and Wrist*  
*19 The Normal Pelvis and Hip*  
*20 Acute Osseous Injury to the Pelvis and Acetabulum*  
*22 Acute Osseous Injury to the Hip and Proximal Femur*

**Bart Loeys, MD, PhD**

Professor of Clinical Genetics  
Center for Medical Genetics  
Antwerp University Hospital/University of Antwerp,  
Antwerp, Belgium  
*84 Marfan Syndrome*

**Chika Iloanusi Logie, MD**

Senior Scientist and Associate Editor  
Musculoskeletal Imaging  
American Institute for Radiologic Pathology  
Silver Spring, Maryland  
Adjunct Assistant Professor  
Departments of Radiology and Radiological Sciences  
Uniformed Services University of the Health Sciences  
Bethesda, Maryland  
*79 Amyloidosis*  
*86 Hypertrophic Osteoarthropathy*

**Niamh M. Long, MB, BCh, BAO**

Department of Radiology  
Mater Misericordiae University Hospital  
Dublin, Ireland  
*76 Myelofibrosis*  
*109 Postoperative Hip*

**Calvin Ma, MD**

Staff Radiologist  
Sutter Imaging, Musculoskeletal Section  
Sutter Health Systems  
Sacramento, California  
*17 Compressive and Entrapment Neuropathies of the Upper  
Extremity*  
*35 Compressive and Entrapment Neuropathies of the Lower  
Extremity*  
*80 Pituitary and Thyroid Disorders*  
*82 Storage Diseases (Mucopolysaccharidoses and Glycogenoses)*

**Jacques Malghem, MD**

Professor of Radiology  
Université Catholique Louvain  
Cliniques Universitaires Saint-Luc  
Brussels, Belgium  
*72 Ischemic Bone Lesions*

**Natalia Marks, MD**

Radiologist  
Department of Diagnostic Imaging  
Maimonides Medical Center  
Brooklyn, New York  
*13 Normal Wrist*

**José Martel, MD, PhD**

Diagnóstico por Imagen  
Hospital Universitario Fundación Alcorcón  
Madrid, Spain  
*Appendix 3 Fractures with Names*

**Manesh Mathew, MD**

Attending Radiologist  
Altoona Regional Medical Center  
Altoona, Pennsylvania  
*14 Acute Osseous Injury to the Wrist*  
*16 Acute Osseous Trauma to the Hand*

**Iain W. McCall, MD, NIB, ChB, FRCR**

Professor of Radiologic Sciences (retired)  
 Keele University  
 Honorary Consultant Radiologist  
 Department of Radiology  
 University Hospital of North Staffordshire  
 Stoke on Trent, North Staffordshire  
 Consultant Radiologist  
 Department of Radiology  
 The Robert Jones and Agnes Hunt Orthopaedic Hospital  
 NHS Foundation Trust  
 Shropshire, United Kingdom  
*45 Degenerative Disorders of the Spine*

**Eugene McNally, MD, BCh, BAO, FRCR, FRCPI**

Consultant Musculoskeletal Radiologist  
 Department of Radiology  
 Nuffield Orthopaedic Centre  
 Honorary Senior Lecturer  
 Nuffield Department of Orthopaedic Surgery  
 Oxford University Hospital  
 Oxford, United Kingdom  
*27 Internal Derangement of the Knee; Ligament Injuries*

**José M. Mellado Santos, MD**

Servicio de Radiología  
 Hospital Reina Sofía  
 Tudela, Navarra  
 Spain  
*20 Acute Osseous Injury to the Pelvis and Acetabulum*  
*22 Acute Osseous Injury to the Hip and Proximal Femur*

**Kirsten A. Menn, MD**

Clinical Fellow  
 Division of Pediatric Radiology  
 Yale New Haven Hospital  
 New Haven, Connecticut  
*68 Pediatric Infections*

**Theodore T. Miller, MD, FACR**

Professor of Radiology  
 Weill Medical College of Cornell University  
 Attending Radiologist  
 Department of Radiology and Imaging  
 Hospital for Special Surgery  
 New York, New York  
*6 Normal Shoulder*  
*10 Normal Elbow*  
*28 Internal Derangement of the Knee; Tendon Injuries*

**Douglas N. Mintz, MD**

Associate Attending Radiologist  
 Hospital for Special Surgery  
 Associate Professor of Clinical Radiology  
 Weill College of Medicine  
 Cornell University  
 New York, New York

*110 Postoperative Knee*

**Johnny U. V. Monu, MBBS, MSc**

Professor of Imaging Sciences and Orthopedics  
 Department of Imaging Sciences  
 University of Rochester  
 Rochester, New York  
*46 Aging*  
*48 Rheumatoid Arthritis*  
*55 Juvenile Idiopathic Arthritis*  
*61 Crystal-Related Arthritis*

**Sandra Moore, MD**

Assistant Professor  
 Department of Radiology  
 New York University School of Medicine  
 NYU Langone Medical Center  
 New York, New York  
*62 Neuropathic Osteoarthropathy*  
*69 HIV Infection and AIDS*

**Morcós Morcos, MD**

Diagnostic Radiologist  
 Department of Radiology  
 Maimonides Medical Center  
 Brooklyn, New York  
*13 Normal Wrist*

**William B. Morrison, MD**

Professor of Radiology  
 Thomas Jefferson University  
 Director, Division of Musculoskeletal and General  
 Diagnostic Radiology  
 Thomas Jefferson University Hospital  
 Philadelphia, Pennsylvania  
*1 General Imaging Principles*  
*63 Non-Inflammatory Intraarticular Pathology*  
*67 Diabetic Pedal Infection*

**Geert R. Mortier, MD**

Professor of Clinical Genetics  
 University Hospital Antwerp  
 University Antwerp and Ghent, Belgium  
*101 Focal Growth Disturbances*

**Timothy J. Mosher, MD, MS**

Distinguished Professor of Radiology and Orthopaedics  
 Kenneth L. Miller Chair of Radiology  
 Department of Radiology  
 Penn State University College of Medicine  
 Department of Radiology  
 Penn State University Hospital  
 Hershey, Pennsylvania  
*47 Degenerative Disease; Physiology and Advanced Imaging*

**Michael E. Mulligan, MD**

Professor of Diagnostic Radiology and Nuclear Medicine