

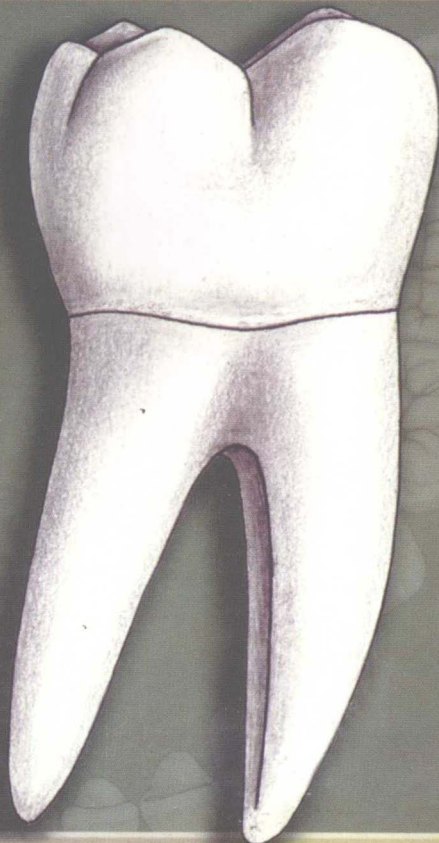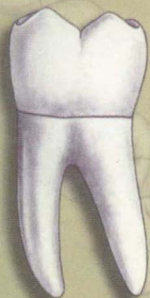牙体图谱

第2版

Atlas of the Human Dentition

原著 Charles J. Goodacre, DDS, MSD

主译 张秀华 李一鸣



人民卫生出版社

Atlas of the Human Dentition 2e, Charles J. Goodacre, DDS, MSD
Robert Knabenbauer, Medical Illustrator
Rob Holland, Graphic and Multimedia Designer
Mirosljub Ilich, CDT, Morphology Consultant
Loma Linda University School of Dentistry
11092 Anderson Street, Loma Linda, CA 92350

图书在版编目 (CIP) 数据

牙体图谱 / 张秀华等主译. —北京: 人民卫生出版社,
2008.6

ISBN 978-7-117-10154-7

I. 牙... II. 张... III. 牙体-图谱 IV. R322.4-64

中国版本图书馆CIP数据核字 (2008) 第059270号

图字: 01-2008-2516

牙 体 图 谱

主 译: 张秀华 李一鸣

出版发行: 人民卫生出版社 (中继线 010-67616688)

地 址: 北京市丰台区方庄芳群园 3 区 3 号楼

邮 编: 100078

网 址: <http://www.pmph.com>

E - mail: pmph@pmph.com

购书热线: 010-67605754 010-65264830

印 刷: 北京彩云龙印刷有限公司

经 销: 新华书店

开 本: 787×1092 1/32 印张: 3 字数: 80千字

版 次: 2008年6月第1版 2008年6月第1版第1次印刷

标准书号: ISBN 978-7-117-10154-7/R·10155

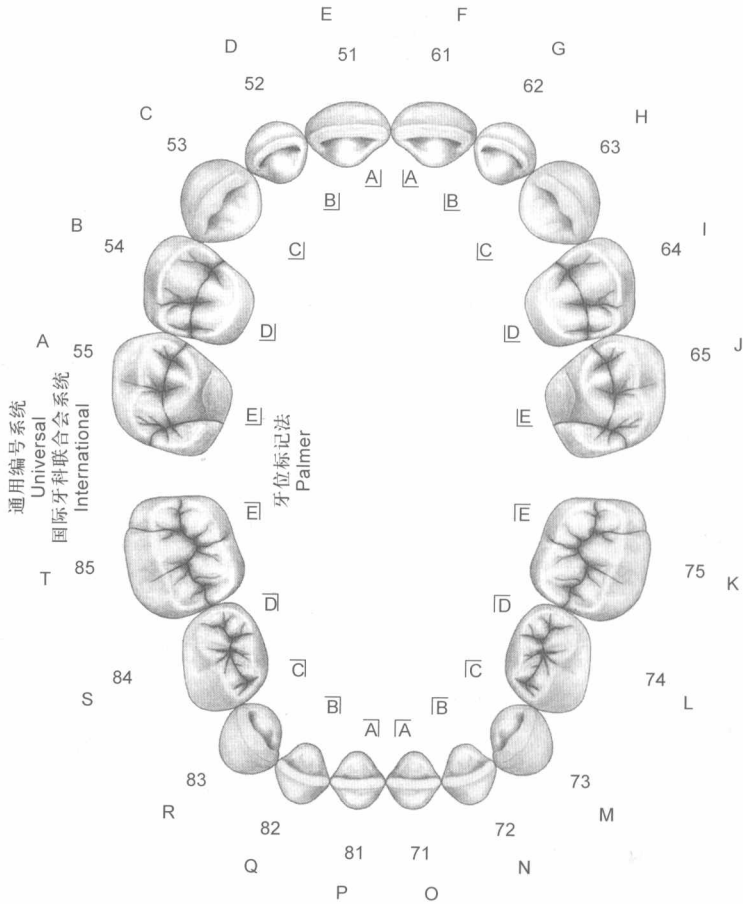
定 价: 39.00元

版权所有, 侵权必究, 打击盗版举报电话: 010-87613394

(凡属印装质量问题请与本社销售部联系退换)

乳牙列

Primary Dentition

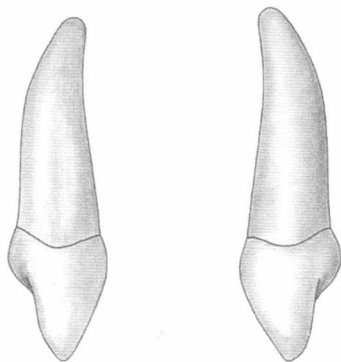
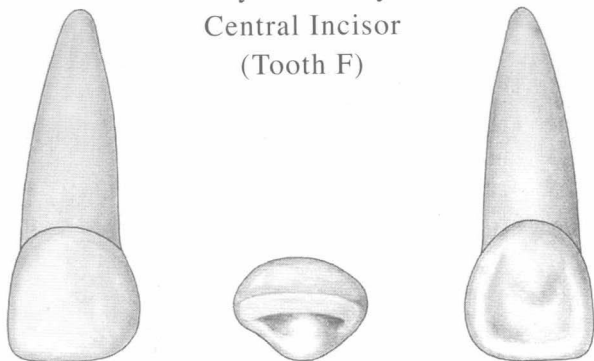


左侧上颌乳中切牙 (编号: F)

Primary Maxillary Left

Central Incisor

(Tooth F)


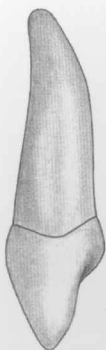
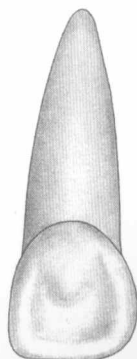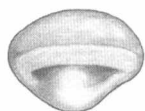
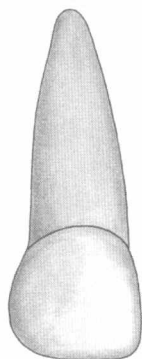


右侧上颌乳中切牙 (编号: E)

Primary Maxillary Right

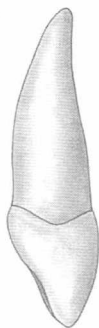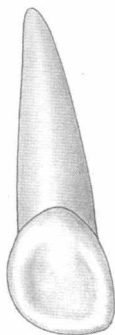

Central Incisor

(Tooth E)



左侧上颌乳侧切牙 (编号: G)
Primary Maxillary Left

Lateral Incisor
(Tooth G)

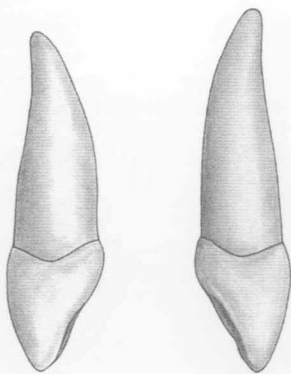
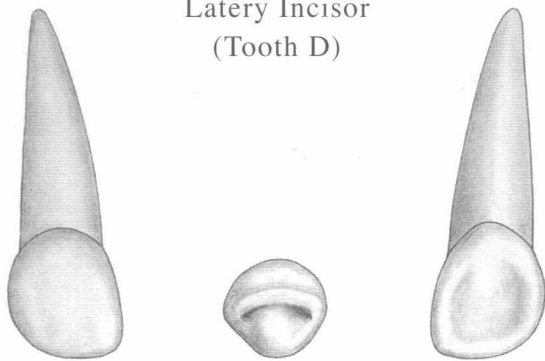


右侧上颌乳侧切牙 (编号: D)

Primary Maxillary Right

Lateral Incisor

(Tooth D)

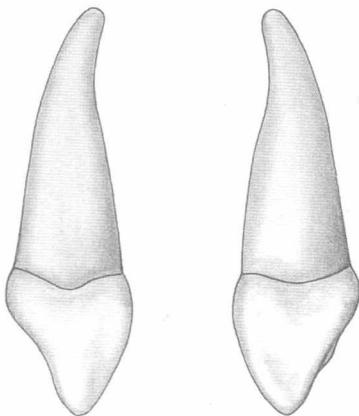
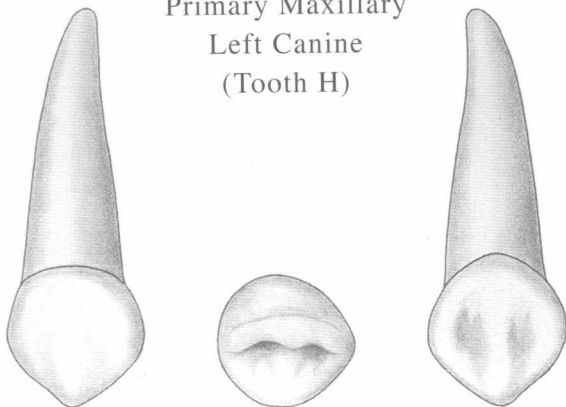


左侧上颌乳尖牙 (编号: H)

Primary Maxillary

Left Canine

(Tooth H)

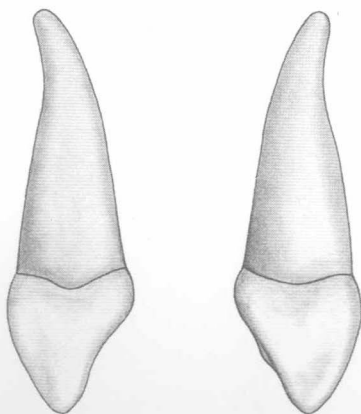
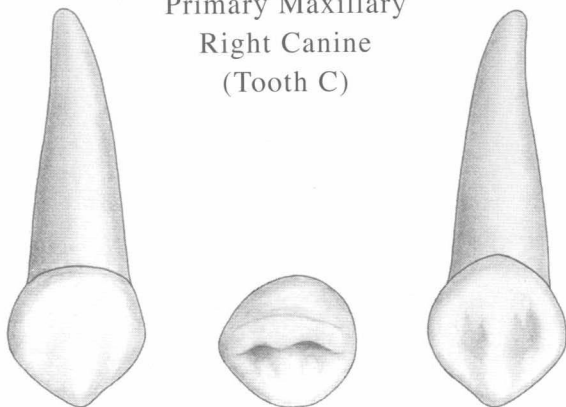


右侧上颌乳尖牙 (编号: C)

Primary Maxillary

Right Canine

(Tooth C)

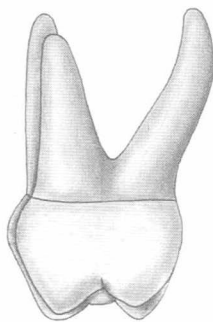
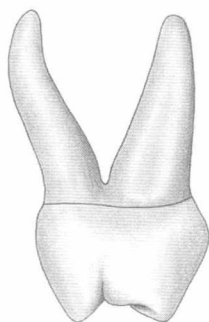
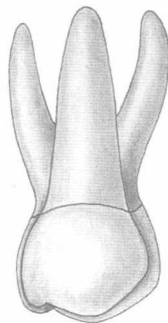
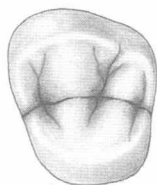
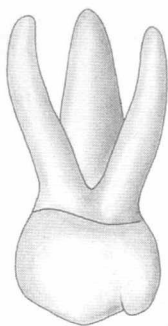


左侧上颌第一乳磨牙 (编号: I)

Primary Maxillary Left

First Molar

(Tooth I)

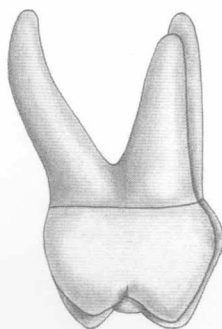
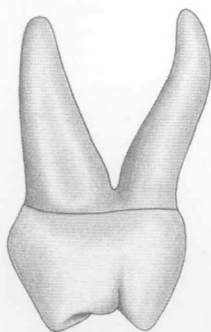
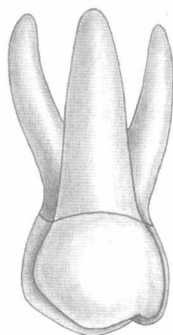
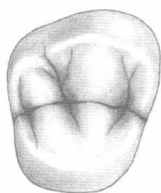
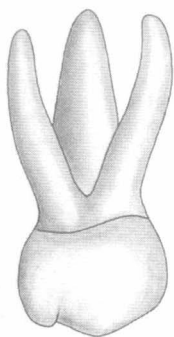


右侧上颌第一乳磨牙 (编号: B)

Primary Maxillary Right

First Molar

(Tooth B)

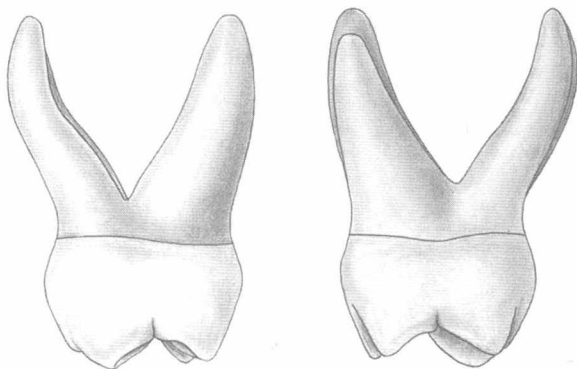
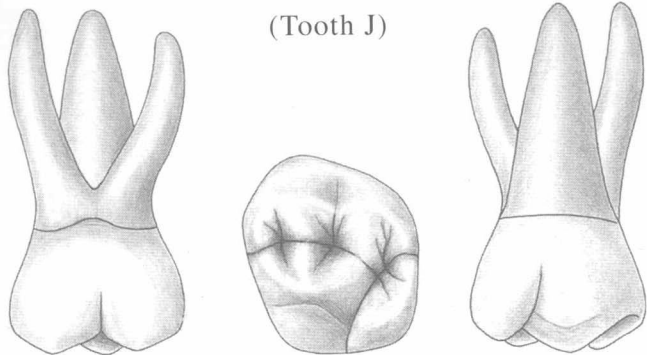


左侧上颌第二乳磨牙 (编号: J)

Primary Maxillary

Left Second Molar

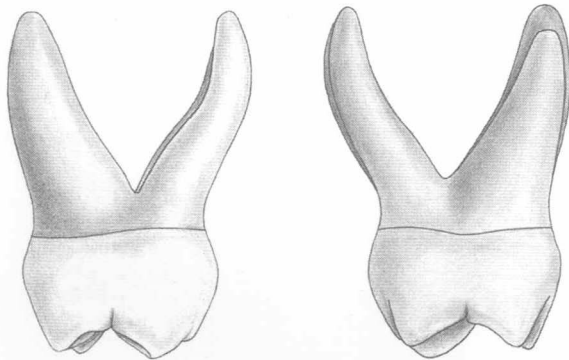
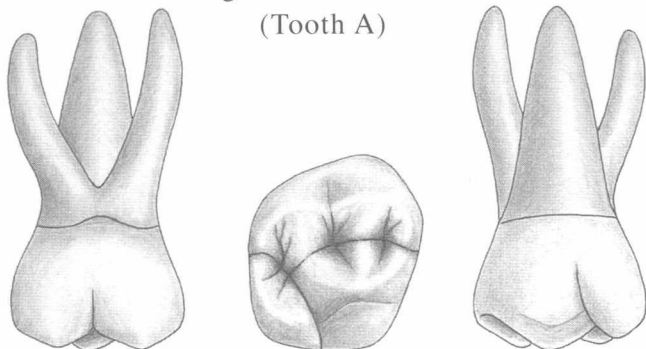
(Tooth J)



右侧上颌第二乳磨牙 (编号: A)

Primary Maxillary
Right Second Molar

(Tooth A)

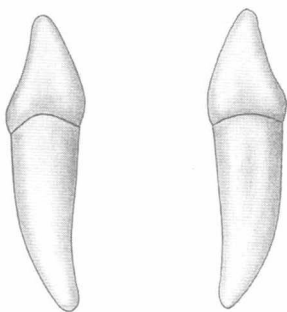
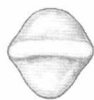
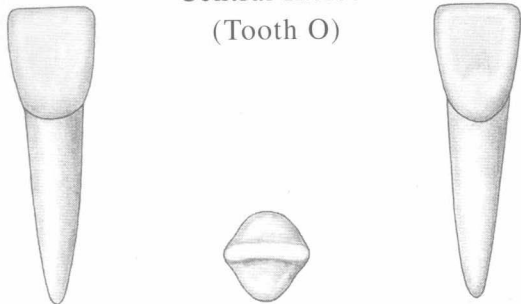


左侧下颌乳中切牙 (编号: 0)

Primary Mandibular Left

Central Incisor

(Tooth 0)

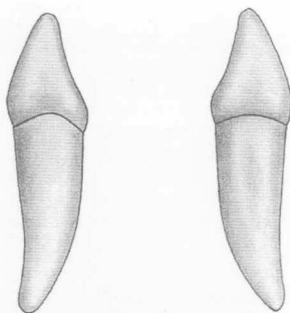
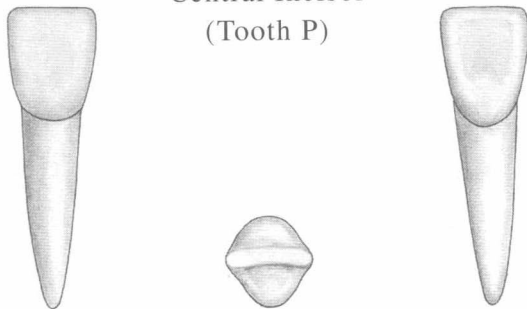


右侧下颌乳中切牙 (编号: P)

Primary Mandibular Right

Central Incisor

(Tooth P)

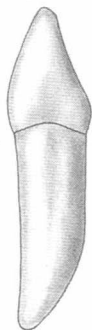
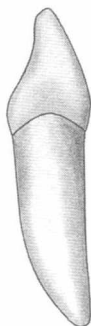
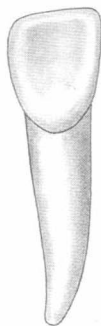
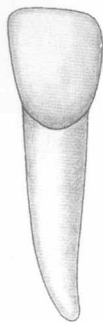


左侧下颌乳侧切牙 (编号: N)

Primary Mandibular Left

Lateral Incisor

(Tooth N)



右侧下颌乳侧切牙 (编号: Q)

Primary Mandibular Right

Lateral Incisor

(Tooth Q)

