

# Managing Myeloproliferative Neoplasms

A CASE-BASED APPROACH

EDITED BY RUBEN A. MESA & CLAIRE N. HARRISON



CAMBRIDGE

Medicine

# Managing Myeloproliferative Neoplasms

---

## A Case-Based Approach

Edited by

**Ruben A. Mesa, MD**

Consultant Hematologist and Chair, Division of Hematology and Medical Oncology, Mayo Clinic, Scottsdale, AZ, USA

**Claire N. Harrison, MD**

Consultant Haematologist and Deputy Clinical Director, Cancer and Haematology, Guy's and St. Thomas' NHS Foundation Trust, London, UK



**CAMBRIDGE**  
UNIVERSITY PRESS

**CAMBRIDGE**  
UNIVERSITY PRESS

University Printing House, Cambridge CB2 8BS, United Kingdom

Cambridge University Press is part of the University of Cambridge.

It furthers the University's mission by disseminating knowledge in the pursuit of education, learning and research at the highest international levels of excellence.

[www.cambridge.org](http://www.cambridge.org)

Information on this title: [www.cambridge.org/9781107444430](http://www.cambridge.org/9781107444430)

© Cambridge University Press 2016

This publication is in copyright. Subject to statutory exception and to the provisions of relevant collective licensing agreements, no reproduction of any part may take place without the written permission of Cambridge University Press.

First published 2016

Printed in the United Kingdom by Clays, St Ives plc

*A catalogue record for this publication is available from the British Library*

*Library of Congress Cataloguing in Publication data*

Names: Mesa, Ruben A., editor. | Harrison, Claire (Claire N.), editor.

Title: Managing myeloproliferative neoplasms : a case-based approach / edited by Ruben A. Mesa, Claire N. Harrison.

Description: Cambridge, United Kingdom; New York : Cambridge University Press, 2016. | Includes bibliographical references and index.

Identifiers: LCCN 2015046522 | ISBN 9781107444430 (pbk.)

Subjects: | MESH: Myeloproliferative Disorders--therapy |

Hematologic Neoplasms--therapy

Classification: LCC RC280.H47 | NLM WH 380 | DDC 616.99/418--dc23

LC record available at <http://lcn.loc.gov/2015046522>

ISBN 978-1-107-44443-0 Paperback

Cambridge University Press has no responsibility for the persistence or accuracy of URLs for external or third-party internet websites referred to in this publication, and does not guarantee that any content on such websites is, or will remain, accurate or appropriate.

.....

Every effort has been made in preparing this book to provide accurate and up-to-date information which is in accord with accepted standards and practice at the time of publication. Although case histories are drawn from actual cases, every effort has been made to disguise the identities of the individuals involved. Nevertheless, the authors, editors and publishers can make no warranties that the information contained herein is totally free from error, not least because clinical standards are constantly changing through research and regulation. The authors, editors and publishers therefore disclaim all liability for direct or consequential damages resulting from the use of material contained in this book. Readers are strongly advised to pay careful attention to information provided by the manufacturer of any drugs or equipment that they plan to use.

# Managing Myeloproliferative Neoplasms

---



**Francisco Cervantes**

Departments of Hematology, Hospital Clinic, IDIBAPS, University of Barcelona, Barcelona, Spain

**Nicholas C.P. Cross**

Wessex Regional Genetics Laboratory, Salisbury, and Faculty of Medicine, University of Southampton, Southampton, UK

**Lorenzo Falchi**

Department of Leukemia, The University of Texas MD Anderson Cancer Center, Houston, TX, USA

**Veena Fauble**

Mayo Clinic, Scottsdale, AZ, USA

**Guido Finazzi**

Department of Hematology, Ospedale Papa Giovanni XXIII, Bergamo, Italy

**David A. Garcia**

Professor of Medicine, Division of Hematology, University of Washington, Seattle, WA, USA

**Holly L. Geyer**

Department of Internal Medicine, Mayo Clinic, Scottsdale, AZ, USA

**Aaron T. Gerds**

Leukemia Program, Cleveland Clinic Taussig Cancer Institute, Cleveland, OH, USA

**Jason Gotlib**

Associate Professor of Medicine (Hematology), Stanford University School of Medicine/ Stanford Cancer Institute, Stanford, CA, USA

**Paola Guglielmelli**

Laboratorio Congiunto Malattie Mieloproliferative Croniche, Department of Experimental and Clinical Medicine, University of Florence, Azienda Ospedaliera Universitaria Careggi, Florence, Italy

**Vikas Gupta**

Princess Margaret Cancer Center, Toronto, Canada

**Claire N. Harrison**

Consultant Haematologist and Deputy Clinical Director, Cancer and Haematology, Guy's and St. Thomas' NHS Foundation Trust, London, UK

**Dimitra Koumaki**

2nd Department of Dermatology and Venereology, Attikon University Hospital, Athens, Greece

**Hans Michael Kvasnicka**

Senckenberg Institute of Pathology, University of Frankfurt, Frankfurt, Germany

**Mary Frances McMullin**

Professor of Clinical Haematology, Department of Haematology, Belfast City Hospital, Queen's University Belfast, Belfast, N. Ireland

**Ruben A. Mesa**

Consultant Hematologist and Chair, Division of Hematology and Medical Oncology, Mayo Clinic, Scottsdale, AZ, USA

**Georgia Metzgeroth**

Department of Haematology and Oncology, University Medical Centre, Mannheim, Germany

**Laura C. Michaelis**

Associate Professor, Hematology and Oncology, Froedtert Hospital and the Medical College of Wisconsin, Milwaukee, WI, USA

**Loula Papageorgiou**

Department of Haematology and Bone Marrow Transplantation Unit, National and Kapodistrian University of Athens, School of Medicine, Laiko General Hospital, Athens, Greece

**Arturo Pereira**

Department of Hemotherapy and Hemostasis,  
Hospital Clinic, IDIBAPS, University of Barcelona,  
Barcelona, Spain

**Daniel A. Pollyea**

Clinical Director of Leukemia Services, University of  
Colorado School of Medicine, and Assistant Professor  
of Medicine, Department of Medicine, Division of  
Hematology, Aurora, CO, USA

**Josef Prchal**

Hematology, University of Utah School of Medicine,  
Salt Lake City, UT, USA

**Deepti Radia**

Haematology Consultant, Guys and St Thomas'  
NHS Foundation Trust, Haematology Department,  
London, UK

**Craig B. Reeder**

Mayo Clinic, Scottsdale, AZ, USA

**Andreas Reiter**

Department of Haematology and Oncology,  
University Medical Centre, Mannheim, Germany

**Susan Robinson**

Guy's Hospital, London, UK

**Bethany T. Samuelson**

Hematology–Oncology, University of Washington,  
San Francisco, CA, USA

**Robyn M. Scherber**

Division of Hematology and Medical Oncology, Mayo  
Clinic, Scottsdale, AZ, USA

**Robert Schneidewend**

Department of Oncology, Froedtert Hospital and the  
Medical College of Wisconsin, Milwaukee, WI, USA

**Jeffrey T. Schowinsky**

University of Colorado School of Medicine,  
Department of Pathology, Aurora, CO, USA

**Mikkael A. Sekeres**

Leukemia Program, Cleveland Clinic, Taussig Cancer  
Institute, Cleveland, OH, USA

**Brady L. Stein**

Assistant Professor of Medicine, Division of  
Hematology/Oncology, Department of Medicine,  
Robert H. Lurie Comprehensive Cancer Center,  
Northwestern University Feinberg School of  
Medicine, Chicago, IL, USA

**Sabina Swierczek**

Hematology, University of Utah School of Medicine,  
Salt Lake City, UT, USA

**Raoul Tibes**

Mayo Clinic, Scottsdale, AZ, USA

**Ramon V. Tiu**

Leukemia Program, Cleveland Clinic Taussig Cancer  
Institute, Cleveland, OH, Eli-Lilly and Company,  
Indianapolis, IN, USA

**Alessandro M. Vannucchi**

Laboratorio Congiunto Malattie Mieloproliferative  
Croniche, Department of Experimental and  
Clinical Medicine, University of Florence, Azienda  
Ospedaliera Universitaria Careggi, Florence, Italy

**Srdan Verstovsek**

Department of Leukemia, The University of Texas MD  
Anderson Cancer Center, Houston, TX, USA

# Preface

Clinical manifestations of the myeloproliferative neoplasms span the breadth of hematology. The diagnostic net particularly for entities such as eosinophilia must be cast wide and can be challenging. Patients may suffer aggressive neoplastic transformation, and also hemorrhage, or thrombosis. In this book our authors, all experts in this field, will guide the reader through the entire clinical path from diagnosis to management, navigating the many changes and advances in the past decade since the description of the *JAK2 V617F* mutation using an engaging case-based approach.

Using clinical examples, our readers will gain an understanding of the many molecular advances (such as calreticulin and *CSF3R* mutations) and application of novel therapies, in particular JAK and other tyrosine kinase inhibitors.

Whatever your prior experience of this field as a trainee, consultant, pharmacist, nurse, or expert patient, this book will demystify these rare conditions and leave you confident in managing the myeloproliferative neoplasms.

# Contents

*List of contributors* vii

*Preface* ix

- 
- 1 **Initial assessment of the undiagnosed patient who has an erythrocytosis, leukocytosis, or thrombocytosis** 1  
Mary Frances McMullin
  - 2 **Practical approaches to molecular testing and diagnosis of mastocytosis, hypereosinophilia, and MDS/MPN overlap syndromes** 9  
Nicholas C.P. Cross, Dimitra Koumaki, Georgia Metzgeroth, and Andreas Reiter
  - 3 **Incidental splenomegaly: an approach to diagnosis** 17  
Craig B. Reeder
  - 4 **When to do a bone marrow biopsy and how to interpret it in the diagnosis of myeloproliferative neoplasm** 22  
Hans Michael Kvasnicka
  - 5 **Accurately assessing risk in your myeloproliferative neoplasm patient** 37  
Francisco Cervantes and Arturo Pereira
  - 6 **Incorporating symptomatic assessment in therapy choice for patients with myeloproliferative neoplasms** 45  
Robyn M. Scherber, Holly L. Geyer, and Ruben A. Mesa
  - 7 **The newly diagnosed patient with essential thrombocythemia** 56  
Guido Finazzi
  - 8 **The newly diagnosed patient with polycythemia vera** 64  
Alessandro M. Vannucchi and Paola Guglielmelli
  - 9 **Longstanding polycythemia vera and essential thrombocythemia: monitoring and management goals** 70  
Loula Papageorgiou and Claire N. Harrison
  - 10 **Which patients are candidates for JAK inhibitors and how to manage patients on JAK inhibitor treatment** 79  
Lorenzo Falchi and Srdan Verstovsek
  - 11 **Hematopoietic cell transplantation for myelofibrosis: who and when?** 86  
Veena Fauble and Vikas Gupta
  - 12 **Systemic mast cell disease: diagnosis and management** 97  
Deepti Radia
  - 13 **Hypereosinophilia: an illustrated approach to diagnosis and management** 108  
Jason Gotlib
  - 14 **Myelodysplastic/myeloproliferative neoplasm overlap syndromes** 120  
Aaron T. Gerds, Ramon V. Tiu, and Mikkael A. Sekeres
  - 15 **Atypical chronic myeloid leukemia and chronic neutrophilic leukemia** 129  
Daniel A. Pollyea and Jeffrey T. Schowinsky
  - 16 **Women and children with myeloproliferative neoplasms – special considerations** 137  
Robert Schneidewend and Laura C. Michaelis
  - 17 **Conception and pregnancy in myeloproliferative neoplasms** 152  
Susan Robinson
  - 18 **Managing acute vascular events in patients with myeloproliferative neoplasms** 160  
David A. Garcia and Bethany T. Samuelson
  - 19 **Challenging thrombotic scenarios in the myeloproliferative neoplasms: splanchnic vein thrombosis and others** 172  
Brady L. Stein



20	<b>Familial myeloproliferative neoplasms – implications for patients and their families</b>	178
	Sabina Swierczek and Josef Prchal	

21	<b>Management of acute leukemia following myeloproliferative neoplasms</b>	184
	Raoul Tibes	

---

	<i>Index</i>	191
--	--------------	-----

# Initial assessment of the undiagnosed patient who has an erythrocytosis, leukocytosis, or thrombocytosis

Mary Frances McMullin

A patient can present with a raised hemoglobin (Hb), raised white cell count (WCC) or leukocytosis, or raised platelet counts and in each case the causes of the abnormality have to be considered and investigated in order to arrive at the diagnosis. Each type of abnormality will be discussed and illustrative cases given. Cases presenting with simultaneous multiple raised cell counts will also be considered.

## Erythrocytosis

An absolute or true erythrocytosis is present when the red cell mass is greater than 125% predicted for the patient's sex and body mass. The presence of an erythrocytosis is indicated by an Hb and/or a hematocrit (Hct) above the upper limit of normal. However, a raised Hb or Hct may not necessarily indicate that a true erythrocytosis is present. It may be necessary to formally measure the red cell mass in order to prove that there is a true erythrocytosis as opposed to an apparent erythrocytosis (where the Hct is raised but the red cell mass is within the reference range) or a relative erythrocytosis (where the Hct is raised but the red cell mass is within the reference range and the plasma volume reduced). In cases where the Hct is above 0.60% in a male or 0.56% in a woman the red cell mass is always elevated and formal measurement of the red cell mass is unnecessary to prove the point.<sup>1</sup>

## Differential diagnosis of erythrocytosis

An erythrocytosis can be primary where there is an intrinsic defect within the bone marrow compartment or secondary where something usually mediated by erythropoietin (EPO) is driving the red cell mass expansion. In each case the cause can be congenital or acquired.<sup>2</sup> Table 1.1 lists all the causes of an erythrocytosis.

## Initial assessment of an undiagnosed patient with erythrocytosis

The patient should be seen and the full blood picture (FBP) repeated to confirm that the abnormality is present. A careful history and examination should then be carried out considering the differential diagnosis.<sup>3</sup> Having confirmed the erythrocytosis if a diagnosis of polycythemia vera (PV) seems a possibility, the next investigation indicated is a test for *JAK2* mutations which, if positive, will confirm clonal disease.<sup>4</sup> If PV does not seem likely then the next step would be to measure the EPO level. A low-level EPO suggests a primary defect in the EPO signaling pathway and this should then be investigated further. A normal or elevated EPO level suggests a secondary cause of erythrocytosis and this should then be investigated further, pursuing any suggestions from the history and examination. Figure 1.1 is an algorithm of the suggested investigative route for a patient with erythrocytosis.

### Case 1

*An 18-year-old woman presented to the maternity unit 10 weeks pregnant. She was well. In her history she stated that her mother had been investigated because "she had too much blood." On examination there was nothing abnormal of note. Her FBP: Hb 194 g/L, Hct 0.60%, WCC  $8.0 \times 10^9/L$  and platelets (Pts)  $151 \times 10^9/L$ . Her EPO level was 25 mIU/mL (normal range (NR) 2.5–10.5).*

*As she had an erythrocytosis, with a raised EPO level, she had a secondary erythrocytosis. Because of her young age and strong family history a congenital secondary erythrocytosis was considered. Her globin genes were sequenced first and she was found to have the high-affinity  $\beta$  hemoglobin hemoglobin San Diego  $\beta$  109 GTG-ATG; Val-Met.*

**Table 1.1** Patient investigation

**Erythrocytosis**
**Primary erythrocytosis**
**Congenital**

Erythropoietin receptor mutation

**Acquired**

Polycythemia vera

*LNK* mutations (congenital or acquired)

**Secondary erythrocytosis**
**Congenital**

High oxygen-affinity hemoglobin

Bisphosphoglycerate mutase deficiency

Methemoglobinemia

Oxygen-sensing pathway defects

*VHL* gene mutation

*PHD2* mutations

*HIF-2A* mutations

**Acquired**
Erythropoietin-mediated

Central hypoxia

Chronic lung disease

Right-to-left cardiopulmonary shunts

Carbon monoxide poisoning

Smoker's erythrocytosis

Hypoventilation syndromes

High-altitude habitat

Local renal hypoxia

Renal artery stenosis

End-stage renal disease

Hydronephrosis

Renal cysts (polycystic kidney disease)

Post renal transplant erythrocytosis

Pathological erythropoietin production

Tumors

Cerebellar hemangioblastoma

Meningioma

Parathyroid adenoma/carcinoma

Hepatocellular carcinoma

Renal cell carcinoma

Pheochromocytoma

Uterine leiomyomas

Exogenous erythropoietin

Erythropoietin administration

Androgen administration

**Idiopathic erythrocytosis**
**Leukocytosis**
**Neutrophil leukocytosis**

Bacterial infection

Inflammation

Tissue necrosis

Any neoplasm

Hemorrhage

Hemolysis

Drug, e.g. steroids, granulocyte

colony-stimulating factor

Chronic myeloid leukemia

Myeloproliferative neoplasms

(polycythemia vera, essential

thrombocythemia, primary myelofibrosis)

Smoking

Asplenia

**Eosinophil leukocytosis**

Allergic disorders

Parasitic infections

Polyarteritis nodosa

vasculitis

Skin diseases (e.g., pemphigus)

Metastatic malignancy

Graft-versus-host disease

Hodgkin's disease

Myeloproliferative neoplasms, including

mastocytosis

Hypereosinophilic syndrome

Pulmonary syndromes (e.g., Churg–Strauss

syndrome)

**Basophil leukocytosis**

Myxoedema

Smallpox

Chickenpox infection

Ulcerative colitis

Myeloproliferative neoplasms, including

polycythemia vera and chronic myeloid

leukemia

**Thrombocytosis**
**Primary**

Essential thrombocythemia

Polycythemia vera

Primary myelofibrosis

Myelodysplasia (with del5q)

Refractory anemia with ring sideroblasts

Chronic myeloid leukemia

Chronic myelomonocytic leukemia

Atypical chronic myeloid leukemia

Myelodysplastic syndrome/  
myeloproliferative neoplasm, unclassifiable

**Secondary**

Infection

Inflammation

Tissue damage

Hyposplenism

Postoperative

Hemorrhage

Iron deficiency

Any neoplasm

Hemolysis

Drug therapy, e.g., steroids

**Spurious**

Microspherocytes

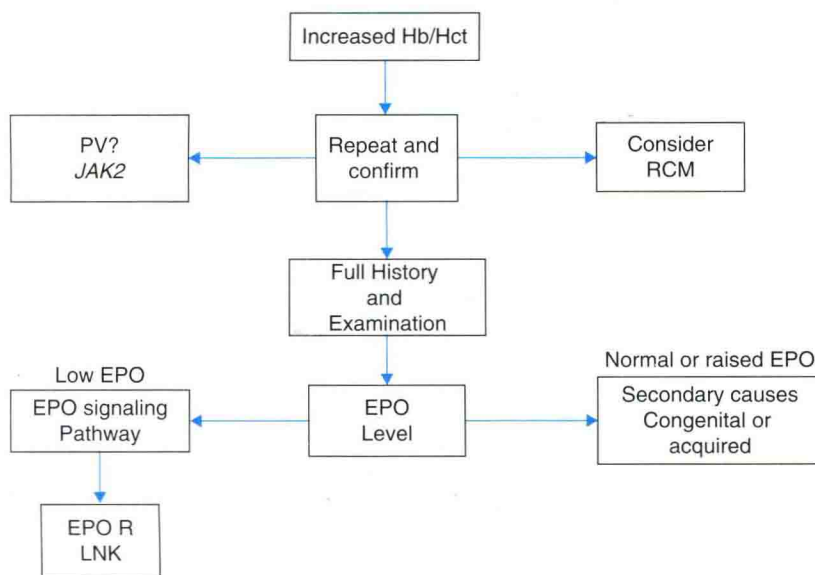
Neoplastic cell fragments

Schistocytes

Bacteria

Cryoglobulinemia

Pappenheimer bodies



**Figure 1.1** An algorithm for the investigation of an erythrocytosis. Hb, hemoglobin; Hct, hematocrit; PV, polycythemia vera; RCM, red cell mass; EPO, erythropoietin.

*Diagnosis: Hemoglobin San Diego: high oxygen affinity hemoglobin.*

## Case 2

A 60-year-old man attended his general practitioner complaining of increasing bleeding from hemorrhoids. He had had hemorrhoids for many years but had increased bleeding over the last 6 months. His FBP: Hb 115 g/L, Hct 0.35%, mean corpuscular volume (MCV) 70 fL, mean corpuscular hemoglobin (MCH) 25 pg, mean corpuscular hemoglobin concentration (MCHC) 29 g/L, WCC  $7.5 \times 10^9/L$ , and platelets  $380 \times 10^9/L$ . He was referred for gastrointestinal investigations and started on oral iron supplementation. Four weeks later at a follow-up appointment his repeat FBP was Hb 185 g/L, Hct 0.53%, MCV 80 fL, MCH 28 pg, MCHC 30 g/L, WCC  $7.5 \times 10^9/L$ , and Pts  $380 \times 10^9/L$ . On referral for further investigation of this erythrocytosis, a JAK2 V617F mutation was revealed.

*Diagnosis: Polycythemia vera.*

This patient presented with iron deficiency due to long-term blood loss. This masked underlying polycythemia vera. As soon as iron supplementation was given, the Hb rose rapidly and the patient developed an erythrocytosis. This is a dangerous situation as the rapid rise in Hb can lead to thromboembolic events.

## Case 3

A 64-year-old woman was referred for investigation of a raised Hb. She complained of generalized aches and

pains and red eyes for some months. On examination she had a plethoric appearance and bloodshot injected eyes, and was hypertensive. There were no other abnormalities on examination. Her repeat FBP: Hb 221 g/L, red blood cells (RBC)  $7.47 \times 10^{12}/L$ , Hct 0.70%, MCV 94 fL, MCHC 315 g/L, WCC  $7.0 \times 10^9/L$ , and Pts  $204 \times 10^9/L$ . Her EPO level was  $<2.5$  mIU/mL (NR 2.5–10.5). A test for the JAK2 V617F mutation was negative. Testing for JAK2 exon 12 mutations revealed an K539L mutation.<sup>5</sup>

*Diagnosis: Polycythemia vera with an exon 12 JAK2 mutation.*

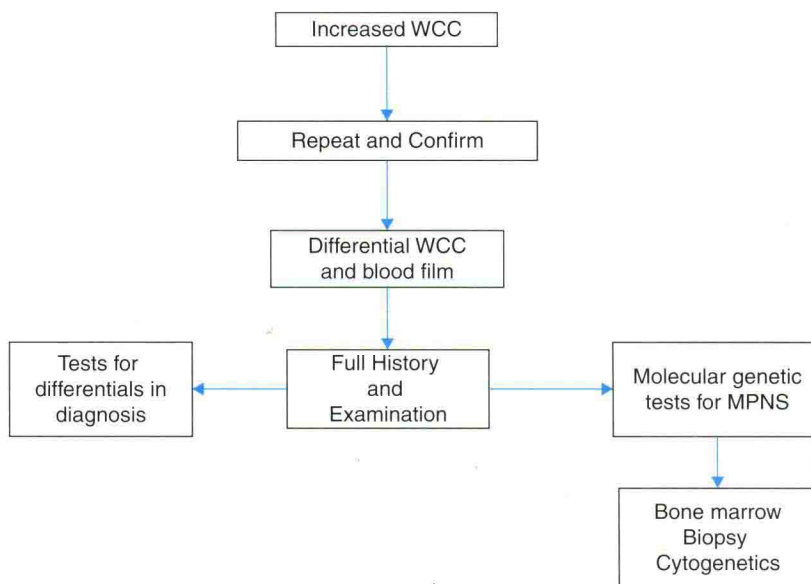
## Leukocytosis

A leukocytosis indicated by a raised WCC above the normal range can be due to raised neutrophils, eosinophils, or basophils. The differential WCC will reveal the type of leukocytosis and fully elucidate the type of elevated white cells. A monocytosis or lymphocytosis as the cause of the elevated WCC will be revealed and eliminated. White cells are produced and turned over in a very short time frame and a leukocytosis can develop and disappear very rapidly.

## Differential diagnosis of a leukocytosis

The causes of a leukocytosis are extensive. A neutrophil leukocytosis can be due to any bacterial infection, particularly pyogenic infections, which will only be sustained if the infection continues. Neutrophilia is also part of the response to any inflammation or tissue





**Figure 1.2** An algorithm for the investigation of a leukocytosis. WCC, white cell count; MPNs, myeloproliferative neoplasms.

damage, acute hemorrhage or hemolysis. Any neoplasm can be associated with neutrophilia. Many drugs such as corticosteroids can cause neutrophilia and it is the desired response from administration of granulocyte colony-stimulating factor. Myeloproliferative neoplasms, both Philadelphia-positive and -negative, frequently have an associated neutrophilia.<sup>6</sup> Other causes include chronic smoking and asplenia.

An eosinophil leukocytosis has many potential causes, including allergic and parasitic disorders, any metastatic malignancy, systemic disorders such as polyarteritis nodosa, many skin diseases, and vasculitis. Hematological causes include Hodgkin's disease, many of the myeloproliferative neoplasms, and graft-versus-host disease. There are also a number of specific hypereosinophilic syndromes and pulmonary syndromes which cause eosinophilia.

A basophil leukocytosis is rare but can be caused by viral infections such as smallpox and chickenpox, myxoedema, ulcerative colitis, and in myeloproliferative neoplasms.

A summary list of causes of leukocytosis is presented in Table 1.1.

### Initial assessment of an undiagnosed patient with leukocytosis

The patient with a leukocytosis should be seen and have the blood test repeated to confirm that the abnormality remains present. The patient should have a careful

history taken, including lifestyle issues and examination carried out with consideration of the differential diagnosis. The differential WCC will give information on the type of leukocyte involved. A blood film needs to be examined. Further investigation then depends upon the information at this point. Any likely cause needs to be further investigated. Molecular testing looking for a clonal disorder (*BCR/ABL*, *JAK2*, *MPL*, and *CALR*) should be undertaken if there is no obvious cause, to look for a myeloproliferative neoplasm; specific tests such as *CSF3R* mutations may be considered. Figure 1.2 presents an algorithm to follow for investigation of a leukocytosis.

### Case 4

A 62-year-old woman was referred to hematology outpatients as a red flag referral because of a leukocytosis. The referring FBP: Hb 155 g/L, WCC  $14 \times 10^9/L$  and Pts  $280 \times 10^9/L$ . The patient was well with no specific complaints. Her weight was stable. She smoked 30 cigarettes a day and drank moderate amounts of alcohol at the weekends. On examination she was thin and had nicotine-stained fingers. She had a few scattered coarse crepitations in her chest. Repeat FBP with differential WCC: Hb 152 g/L WCC  $13.5 \times 10^9/L$  and Pts  $285 \times 10^9/L$ , neutrophils  $10.5 \times 10^9/L$  (NR 2.0–7.5), lymphocytes  $2.5 \times 10^9/L$  (NR 1.0–3.5), monocytes  $0.5 \times 10^9/L$  (NR 0.2–0.8), eosinophils  $0.4 \times 10^9/L$  (NR 0.04–0.4), basophils  $0.1 \times 10^9/L$  (NR 0.01–0.1). Chest X-ray showed changes of chronic obstructive pulmonary disease.

*Diagnosis: Neutrophil leukocytosis due to smoking.*

*This woman may need to be investigated further to ensure that she does not have a lung neoplasm as she is a heavy smoker. However, she has no symptoms and nothing of note on her chest X-ray. Her WCC has been at this level for years.<sup>7</sup> Smoking cessation would be advised.*

### Case 5

*A 65-year-old woman attended her general practitioner for a routine annual check-up. She was feeling very well and had no complaints. Included in the screening bloods carried out was a FBP which showed a raised WCC: Hb 133 g/L, WCC  $20.5 \times 10^9/L$  and Pts  $275 \times 10^9/L$ , and she was referred to hematology. On arrival she had no further history of note and examination did not reveal any abnormalities. Repeat FBP and differential: Hb 133 g/L, WCC  $28.5 \times 10^9/L$  and Pts  $271 \times 10^9/L$ , and manual differential neutrophils  $16.5 \times 10^9/L$  (NR 2.0–7.5), lymphocytes  $5.15 \times 10^9/L$  (NR 1.0–3.5), monocytes  $0.57 \times 10^9/L$  (NR 0.2–0.8), eosinophils  $0.86 \times 10^9/L$  (NR 0.04–0.4), basophils  $0.29 \times 10^9/L$  (NR 0.01–0.1), myelocytes  $3.15 \times 10^9/L$ , metamyelocytes  $2.0 \times 10^9/L$ . Molecular investigation showed a BCR/ABL rearrangement and no JAK2 mutation.*

*Diagnosis: Chronic myeloid leukemia.<sup>8</sup>*

*The presence of the BCR/ABL rearrangement showed a clonal disorder. This is early chronic myeloid leukemia. Further investigation would then include bone marrow examination and cytogenetic examination and/or fluorescent in situ hybridization to confirm the presence of the Philadelphia chromosome.*

## Thrombocytosis

A thrombocytosis is present when the platelet count is raised above the normal range, greater than  $450 \times 10^9/L$ . A markedly and repeatedly raised thrombocytosis is of importance, but the significance of one just above the normal range is difficult to assess.

### Differential diagnosis of a thrombocytosis

A raised platelet count can be due to a primary defect in the bone marrow or primary thrombocytosis, or a secondary thrombocytosis where something else drives the increase in the platelet count. There are also a number of reasons where something else may be counted as platelets, erroneously leading to spuriously raised platelets. Bone marrow disorders which lead to primary thrombocytosis include essential thrombocythemia, where there is an acquired clone in the bone

marrow driving the platelet production. The identified clones include JAK2, MPL,<sup>9</sup> and, more recently CALR,<sup>10,11</sup> although there are still cases where no clone has yet been identified. Other myeloproliferative neoplasms, both Philadelphia-positive and -negative, and myelodysplastic syndromes can present with thrombocytosis which is primary. There are many secondary causes for thrombocytosis where increased platelets are produced as part of the reaction to the underlying disorder. This includes response to infection, any inflammation or tissue damage, iron-deficiency hemorrhage and hemolysis, and malignancy. Various cellular elements can be counted as platelets by analyzers. Bacteria, schistocytes, and Pappenheimer bodies, for instance, can be counted, and lead to a spurious platelet reading.<sup>12</sup> The causes of thrombocytosis are listed in Table 1.1.

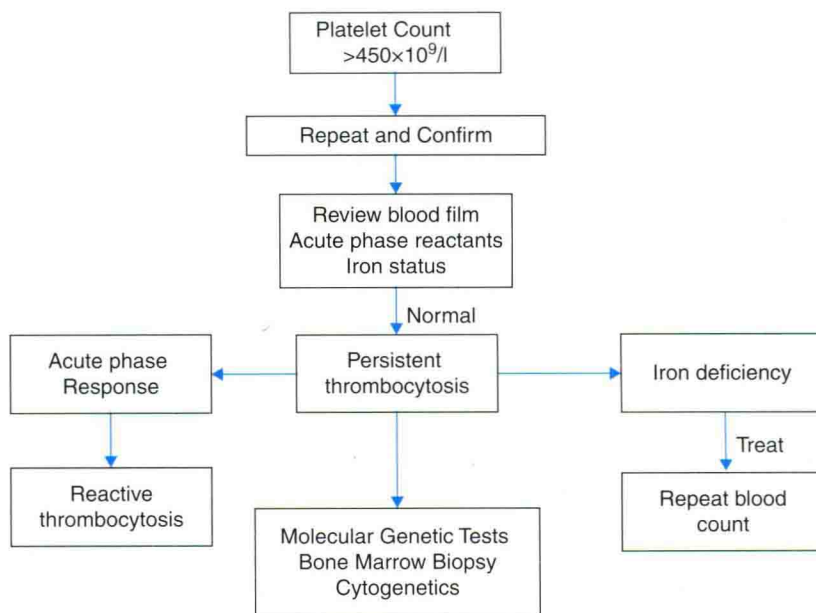
### Initial assessment of an undiagnosed patient with thrombocytosis

As with other patients with an elevated count, the initial assessment is to repeat the count and confirm that there is actually a sustained elevation of the platelet count. The patient then needs to be reviewed and assessed with a careful history and examination. Attention to a search for secondary reactive causes should be included. The next step is to review the blood film and test the iron status (ferritin) and for acute-phase reactants C-reactive protein (CRP) or erythrocyte sedimentation rate (ESR). An elevated acute-phase reactant suggests a reactive thrombocytosis. Iron deficiency should be treated to see if the platelet count decreases. If it does not fall into either of these categories and the elevated platelet count is sustained on repeat, then molecular testing should be carried out, looking for an acquired clone and bone marrow aspirate; trephine and cytogenetic testing should be considered. The algorithm in Figure 1.3 sets out the diagnostic pathway.

### Case 6

*A 50-year-old woman was referred to hematology because she was found to have an elevated platelet count when attending to donate blood. She was otherwise well. On examination there were no abnormal findings. Repeat FBP done 4 weeks after the initial count was: Hb 135 g/L, MCV 85 fL, WCC  $5.5 \times 10^9/L$ , and Pts  $820 \times 10^9/L$ . CRP is 0.3 mg/L (NR 0.1–5) and ferritin 30 µg/L (NR 13–300). It was noted also on searching computer records that she had a platelet count of  $635 \times 10^9/L$  2 years previously*





**Figure 1.3** An algorithm for the investigation of a thrombocytosis.

when having a minor gynecological procedure. Molecular testing detected a JAK2 V617F mutation. A bone marrow trephine was moderately hypercellular with marked proliferation of megakaryocytes, some of which have hyperlobulated nuclei. Reticulin was grade 0 (out of 4). Chromosomes are normal.

*Diagnosis: Essential thrombocythemia.*

### Case 7

An 80-year-old woman was referred to hematology from rheumatology because of a persistently raised platelet count. She had had rheumatoid arthritis for the previous 20 years. This did not now give her much trouble. Otherwise she was well. On examination she had extensive rheumatoid changes in her hands. There were no other abnormal findings on examination. On repeat her FBP was: Hb 129 g/L, MCV 89 fL, WCC  $8.3 \times 10^9/L$ , and Pts  $857 \times 10^9/L$ . ESR is 6 mm/h and ferritin 16  $\mu\text{g/L}$  (NR 13–300). A molecular test for JAK2 V617F was positive.

*Diagnosis: Essential thrombocythemia.*

This woman was presumed to have a reactive thrombocytosis due to her rheumatoid arthritis. However, the referring doctor was suspicious that the rise in platelet count was higher and more sustained than would be expected in a reactive case. Her rheumatoid arthritis was also very quiescent. Molecular testing revealed an acquired clone and therefore she had a primary hematological disorder.

### Case 8

A 17-year-old young man attended his general practitioner for review of his mild asthma. A routine blood count revealed an elevated platelet count and he was referred urgently to hematology. At clinic he was well. Asthma was easily controlled with a salbutamol inhaler. On examination he was 181 cm and looked well, including well nourished. There were no abnormalities on examination. His FBP: Hb 147 g/L, RBC  $5.34 \times 10^{12}/L$ , Hct 0.45%, MCV 84 fL, MCHC 343 g/L, WCC  $9.7 \times 10^9/L$ , and Pts  $1275 \times 10^9/L$ . CRP < 0.3 mg/L (NR 0.1–5) and ferritin 35  $\mu\text{g/L}$  (NR 30–300). Lactate dehydrogenase was 386 IU/L (NR 135–225) and all other biochemistry was within the normal ranges. Blood film showed thrombocytosis and mild poikilocytosis. The bone marrow aspirate was hypercellular with platelet drifts, hyperlobulated megakaryocytes and myeloid hyperplasia, and no excess of blasts. The trephine biopsy was hypercellular with increased hyperlobulated megakaryocytes, disrupted erythropoietic architecture, and reticulin of grade 1 (out of 4). Chromosomes were normal. Molecular testing showed no BCR-ABL1 rearrangement, JAK2 V617F negative, MPL screen negative, and a CALR mutation, exon 9, 5bp insertion.

*Diagnosis: Essential thrombocythemia with a CALR mutation.<sup>13</sup>*

## Initial assessment of an undiagnosed patient more than one cell line elevated

This article has concentrated on the elevation of single cell lines and the diagnostic pathway for each. However, many patients present with elevation of more than one cell line. They need to be investigated in a similar manner with repetition of the blood count to confirm the abnormality and examination of the blood film. Careful history taking and examination are required, looking for reactive and primary or secondary causes, testing to eliminate reactive causes, and then bone marrow and molecular testing for hematological disorders. The cases which follow illustrate where the patient presents with more than one cell lineage elevated.

### Case 9

This 33-year-old woman attended her general practitioner for a check-up. She was married 1 year previously. She had had a pregnancy which spontaneously aborted at 12 weeks' gestation 6 months ago and had not yet conceived again and she was anxious to see if there was any reason for the fact that she had not yet become pregnant again. As part of the screening she had an abnormal FBP and so was referred urgently to hematology. When seen in hematology her only complaint was tiredness. On examination she had a pale complexion but her hands were red. There were no other findings on examination. Her repeat FBP was very similar to the original one carried out by her general practitioner and showed: Hb 197 g/L, RBC  $7.52 \times 10^{12}/L$ , Hct 0.58%, MCV 77 fL, MCHC 338 g/L, WCC  $15.3 \times 10^9/L$ , and Pts  $460 \times 10^9/L$ . She was positive for the JAK2 V617F mutation and her EPO level was  $<2.5$  mIU/mL (NR 2.5–10.5).

Diagnosis: Polycythemia vera.

As her Hct was so high and the diagnosis so likely with these blood counts, she was venesected before she left the clinic. She was then venesected weekly until the Hct was less than 0.45%<sup>14</sup> but, as her WCC and platelets continued to increase, she was also started on interferon. Within 3 months of normalization of her blood counts, she became pregnant and 9 months later delivered a normal healthy baby boy.

### Case 10

A 50-year-old woman was admitted through accident and emergency with sudden severe abdominal pain. On examination she had diffuse tenderness

in her abdomen. Ultrasound of her abdomen showed thrombus in the portal vein and a spleen of 17 cm. She had Budd–Chiari syndrome and was anticoagulated. Her FBP showed: Hb 160 g/L, RBC  $5.34 \times 10^{12}/L$ , Hct 0.458%, MCV 84 fL, MCHC 343 g/L, WCC  $9.7 \times 10^9/L$ , and Pts  $649 \times 10^9/L$ . Testing for a JAK2 V617F mutation was positive.

Diagnosis: Polycythemia vera presenting with a portal vein thrombosis.

## Summary

Patients presenting with an elevated blood count need it to be repeated after a period of time to confirm the abnormality. The patient then needs a thorough history and examination considering primary and secondary causes of the abnormality. A blood film should be examined and then further investigation follows a pathway depending on initial results. Bone marrow examination and molecular testing may reveal the hematological diagnosis.

## References

1. Johansson PL, Soodabeh S-K, Kutti J. An elevated venous haemoglobin concentration cannot be used as a surrogate marker for absolute erythrocytosis: a study of patients with polycythaemia vera and apparent polycythaemia. *Br J Haematol.* 2005;129:701–5.
2. McMullin MF. The classification and diagnosis of erythrocytosis. *Int J Lab Hematol.* 2008;30:185–90.
3. McMullin MF, Bareford D, Campbell P, et al. Guidelines for the diagnosis, investigation and management of polycythaemia/erythrocytosis. *Br J Haematol* 2005;130:174–95.
4. McMullin MF, Reilly JT, Campbell P, et al. Amendment to the guideline for the diagnosis and investigation of polycythaemia/erythrocytosis. *Br J Haematol* 2007;138:821–2.
5. Scott LM, Tong W, Levine RL, et al. JAK2 exon 12 mutations in polycythemia vera and idiopathic erythrocytosis. *N Engl J Med.* 2007;356:459–68.
6. Vardiman JW, Melo JV, Baccarani M, Thiele J. Myeloproliferative neoplasms. In: Swerdlow SH, Campo E, Harris NL, et al. (eds) *WHO Classification of Tumours of Haematopoietic and Lymphoid Tissues.* IARC, Lyon, 2008, pp. 67–86.
7. Smith MR, Kinmonth AL, Luben RN et al. Smoking status and differential white cell count in men and women in EPIC-Norfolk population. *Atherosclerosis.* 2003;169:331–7.



8. Gale RP, Goldman JM. Treating chronic myeloid leukemia in the area of tyrosine kinase inhibitors. *Acta Haematol.* 2013;130:192–5.
9. Beer PA, Campbell PJ, Scott LM, et al. MPL mutations in myeloproliferative disorders: analysis of the PT-1 cohort. *Blood.* 2008;112:141–9.
10. Nangalia J, Massie CE, Baxter EJ, et al. Somatic mutations of calreticulin in myeloproliferative neoplasms. *N Engl J Med.* 2013;369:2379–90.
11. Klampfl T, Gisslinger H, Harutyunyan AS, et al. Somatic CALR mutations in myeloproliferative neoplasms with nonmutated *JAK2*. *N Engl J Med.* 2013;369:2391–405.
12. Harrison CN, Bareford D, Butt N, et al. Guideline for investigation and management of adults and children presenting with a thrombocytosis. *Br J Haematol.* 2010;149:352–75.
13. Harrison CN, Butt N, Campbell P, et al. Modification of British Committee for Standards in Haematology diagnostic criteria for essential thrombocythaemia. *Br J Haematol.* 2014;167 (3):421–3.
14. Marchioli R, Finazzi G, Specchia G, et al. Cardiovascular events and intensity of treatment in polycythemia vera. *N Engl J Med.* 2013;368:22–33.