

PLASTIC SURGERY

VOLUME 3

THE FACE

Part 2

PLASTIC SURGERY

VOLUME 3

THE FACE

Part 2

1990

W.B. SAUNDERS COMPANY

Harcourt Brace Jovanovich, Inc.

Philadelphia ■ London ■ Toronto

Montreal ■ Sydney ■ Tokyo

W. B. SAUNDERS COMPANY
Harcourt Brace Jovanovich, Inc.

The Curtis Center
Independence Square West
Philadelphia, PA 19106

Library of Congress Cataloging-in-Publication Data

Plastic surgery.

Contents: v. 1. General principles—v. 2–3.

The face—v. 4. Cleft lip & palate and craniofacial anomalies—[etc.]

1. Surgery, Plastic. I. McCarthy, Joseph G., 1938—
[DNLM: 1. Surgery, Plastic. WO 600 P7122]

RD118.P536 1990 617'.95 87-9809

ISBN 0-7216-1514-7 (set)

Editor: W. B. Saunders Staff

Designer: W. B. Saunders Staff

Production Manager: Frank Polizzano

Manuscript Editor: David Harvey

Illustration Coordinator: Lisa Lambert

Indexer: Kathleen Garcia

Cover Designer: Ellen Bodner

Volume 1 0-7216-2542-8

Volume 2 0-7216-2543-6

Volume 3 0-7216-2544-4

Volume 4 0-7216-2545-2

Volume 5 0-7216-2546-0

Volume 6 0-7216-2547-9

Volume 7 0-7216-2548-7

Volume 8 0-7216-2549-5

8 Volume Set 0-7216-1514-7

Plastic Surgery

Copyright © 1990 by W. B. Saunders Company.

All rights reserved. No part of this publication may be reproduced or transmitted in any form or by any means, electronic or mechanical, including photocopy, recording, or any information storage and retrieval system, without permission in writing from the publisher.

Printed in the United States of America.

Last digit is the print number: 9 8 7 6 5 4 3 2 1

PLASTIC SURGERY

Editor

JOSEPH G. McCARTHY, M.D.

Lawrence D. Bell Professor of Plastic Surgery and
Director of the Institute of Reconstructive Plastic Surgery
New York University Medical Center
New York, New York

Editors, Hand Surgery Volumes

JAMES W. MAY, JR., M.D.

Director of Plastic Surgery and Hand Surgery Service
Massachusetts General Hospital
Associate Clinical Professor of Surgery
Harvard Medical School
Boston, Massachusetts

J. WILLIAM LITTLER, M.D.

Past Professor of Clinical Surgery
College of Physicians and Surgeons
Columbia University, New York
Senior Attending Surgeon
The St. Luke's-Roosevelt Hospital Center
New York, New York

Contributors

SHERRELL J. ASTON, M.D.

Associate Professor of Surgery (Plastic Surgery), New York University School of Medicine; Attending Surgeon, University Hospital and Manhattan Eye, Ear & Throat Hospital, New York, New York.

DANIEL C. BAKER, M.D.

Associate Professor of Surgery (Plastic Surgery), New York University School of Medicine; Attending Surgeon, University Hospital, Bellevue Hospital Center, Manhattan Eye, Ear & Throat Hospital, and Manhattan Veterans Administration Hospital, New York, New York.

ALFONSO BARRERA, M.D.

Attending Surgeon, Memorial City Medical Center Hospital and West Houston Medical Center Hospital, Houston, Texas.

FRITZ E. BARTON, Jr., M.D.

Professor and Chairman, Division of Plastic Surgery, Department of Surgery, The University of Texas Health Science Center at Dallas; Chief, Plastic Surgery Service, Children's Medical Center; Assistant Chief, Plastic and Reconstructive Surgery Service, Baylor University Medical Center; Attending Surgeon, Parkland Memorial Hospital, Dallas Veterans Administration Hospital, Presbyterian Medical Center, and Gaston Episcopal Hospital, Dallas, Texas.

BURT BRENT, M.D.

Clinical Associate Professor of Plastic Surgery, Stanford University School of Medicine; Clinical Faculty, Stanford University Hospital; Staff Surgeon, El Camino Hospital, Palo Alto, California.

H. STEVE BYRD, M.D.

Associate Professor of Plastic and Reconstructive Surgery, The University of Texas Health Science Center at Dallas; Attending Surgeon, Children's

Medical Center, Baylor University Medical Center, Presbyterian Hospital, and St. Paul Hospital, Dallas, Texas.

THOMAS D. CRONIN, M.D.

Clinical Professor of Plastic Surgery, Baylor College of Medicine; Attending Surgeon, St. Joseph Hospital, Houston, Texas.

JOEL J. FELDMAN, M.D.

Associate in Plastic Surgery, Harvard Medical School; Consultant Plastic Surgeon, Shriners Burns Institute and Massachusetts General Hospital, Boston, Massachusetts; Attending Surgeon, Mount Auburn Hospital, Cambridge, Massachusetts.

JOSEPH G. MCCARTHY, M.D.

Lawrence D. Bell Professor of Plastic Surgery, New York University School of Medicine; Director, Institute of Reconstructive Plastic Surgery, New York University Medical Center; Attending Surgeon, University Hospital, Bellevue Hospital, Manhattan Eye, Ear and Throat Hospital, and Veterans Administration Hospital, New York, New York.

KITARO OHMORI, M.D.

Associate Professor of Plastic Surgery, Juntendo University School of Medicine; Director, Department of Plastic and Reconstructive Surgery, Tokyo Metropolitan Police Hospital, Tokyo, Japan.

THOMAS D. REES, M.D.

Clinical Professor of Surgery (Plastic Surgery), New York University School of Medicine; Chairman, Department of Plastic Surgery, Manhattan Eye, Ear & Throat Hospital, New York, New York.

JACK H. SHEEN, M.D.

Associate Clinical Professor of Plastic and Reconstructive Surgery, University of California, Los

Angeles, School of Medicine; Attending Surgeon, UCLA Medical Center, Los Angeles, California.

CHARLES H. M. THORNE, M.D.

Assistant Professor of Surgery (Plastic Surgery), New York University School of Medicine; Attending Surgeon, Manhattan Eye, Ear & Throat Hospital, University Hospital, Bellevue Hospital, and Manhattan Veterans Administration Hospital, New York, New York.

DONALD WOOD-SMITH, M.D., F.R.C.S.E.

Professor of Surgery (Plastic Surgery), New York University School of Medicine; Chairman, Depart-

ment of Plastic Surgery, New York Eye & Ear Infirmary; Attending Surgeon (Plastic Surgery), Bellevue Medical Center; Attending Surgeon, New York University Hospital, New York Veterans Administration Hospital, and Manhattan Eye, Ear & Throat Hospital, New York, New York.

BARRY M. ZIDE, D.M.D., M.D.

Assistant Professor of Surgery (Plastic Surgery), New York University Medical Center; Attending Surgeon, Bellevue Hospital Center, Manhattan Veterans Administration Hospital, and Manhattan Eye, Ear & Throat Hospital, New York, New York.

Contents

Volume 3

The Face (Part 2)

35	41
Rhinoplasty 1785	Facial Burns 2153
Joseph G. McCarthy • Donald Wood-Smith	Joel J. Feldman
36	42
Secondary Rhinoplasty 1895	Facial Paralysis 2237
Jack H. Sheen	Daniel C. Baker
37	43
Acquired Deformities of the Nose 1924	Blepharoplasty and Facialplasty 2320
Fritz E. Barton, Jr. • H. Steve Byrd	Thomas D. Rees • Sherrell J. Aston
38	Charles H. M. Thorne
Deformities of the Lips and Cheeks 2009	
Barry M. Zide	
39	44
Deformities of the Cervical Region 2057	Esthetic Surgery in the Asian Patient ... 2415
Thomas D. Cronin • Alfonso Barrera	Kitaro Ohmori
40	Index i
Reconstruction of the Auricle 2094	
Burt Brent	

Rhinoplasty

HISTORY

ANATOMY

ESTHETICS

ETHNIC VARIATIONS

PHYSIOLOGY

Anatomic Factors Influencing Nasal Ventilation

CORRECTIVE SURGERY

General Considerations

Anesthesia

Basic Technique

Adjunctive Techniques

Variations in Techniques

Problem Noses

THE DEVIATED NOSE

ESTHETIC RHINOPLASTY IN NON-CAUCASIANS

POSTOPERATIVE CARE

COMPLICATIONS

DEPRESSED NASAL DORSUM: TECHNIQUES OF BONE AND CARTILAGE GRAFTING

ILIAC BONE GRAFT FOR NASAL CONTOUR RESTORATION

COSTAL CARTILAGE GRAFT FOR NASAL CONTOUR RESTORATION

Rhinoplasty, one of the most commonly performed procedures in plastic surgery, in many ways symbolizes the art and practice of this discipline: attention to the psychosocial status of the patient, modification of form, and improvement in nasorespiratory function. It is the surgical procedure that the

trainee struggles to learn and the practitioner continues to modify throughout his career.

Occupying the most prominent position on the face, the nose has been the source of well-known sayings ("plain as a nose in a man's face") and has drawn the attention of writers through the ages:

*A great nose indicates a great man—
Genial, courteous, intellectual
Virile, courageous*

CYRANO DE BERGERAC

Different nasal appearances have elicited various social connotations: large nose—sinister personality, small nose—weak personality, red or erythematous nose—alcoholism or substance abuse, and deviated nose—criminal or psychopathic behavior.

The surgeon undertaking a rhinoplasty must take into consideration the psychologic motivation of the patient and the associated social attitudes, especially in planning a change in nasal form. He must also be prepared to repair deformities in any part of the nose: skin, lining, septum, airway, turbinates, and so forth. There is no place for the "cosmetic nasal surgeon"; the surgeon must be experienced in all aspects of nasal surgery.

HISTORY

The history of plastic surgery has paralleled the development of rhinoplastic techniques (see Chap. 1). However, as late as the twentieth century little faith in the success of purely corrective procedures was expressed by Nélaton and Ombredanne in their classic textbook *La Rhinoplastie* published in 1904: "The surgeon could not pretend to correct a

slight malformation. If a nose be slightly deviated or humped, or show a slight saddle deformity—these are unfortunate defects . . . but we do not believe that the correction of such defects can be achieved by surgery.” However, a review of the literature of the last decade of the nineteenth century and the early part of the twentieth century indicates that nasal corrective procedures were being performed but mostly through external incisions.

In the United States, corrective nasal surgery was pioneered by a small number of surgeons, among whom Roe, Goodale, and Mosher are outstanding. Roe appears to have been the first to employ an intranasal approach as early as 1887. Extracts from some of Roe's papers reveal his understanding of both the functional and psychologic aspects of corrective rhinoplasty (Converse, 1970; Rogers, 1986):

If the deformity of the nose is found to be associated with a local disturbance inside the nose, obstructing the passages, we should invariably remove or correct this local condition, whether it be deviation or thickening of the septum, enlargement of the turbinates, a polyp or other growths, or even adenoids and large tonsils. To preserve perfect nasal respiration is of the utmost necessity, not only to the health and comfort of the patient, but to the satisfactory correction of the nasal deformity.

While symmetrical relations of the different portions of the nose to one another are of the greatest importance, the symmetrical relation as to the size and shape of the nose to the general contour of the face must also be carefully considered, in order to approach the ideal from an artistic point of view.

We are able to relieve patients of a condition which would remain a lifelong mark of disfigurement, constantly observed, forming a never ceasing source of embarrassment and mental distress to themselves, amounting, in many cases, to a positive torture, as well as often causing them to be objects of greater or less aversion to others.

Roe was the first surgeon to use an intranasal approach, but it was Joseph (1931) who popularized corrective nasal surgery through internally placed incisions. His influence was predominant during the first third of this century (Natvig, 1982) and surgeons from around the world traveled to his clinic in Berlin to learn his technique. His teachings were collected in a widely read textbook published in 1931. The Joseph technique was introduced in the United States by Aufrecht and Safian. The literature concerned with corrective nasal plastic surgery is abundant.

A comprehensive bibliography was compiled by McDowell, Valone, and Brown (1952). In recent years the emphasis has been placed on modifying rhinoplastic techniques with refinements in incisions, instrumentation, and cartilage grafts (Sheen, 1978; Sheen and Sheen, 1987; Rees, 1980).

Before rhinoplastic procedures are undertaken, an understanding of the anatomy, esthetics, ethnic variations, and physiology of the nose is a prime requisite.

ANATOMY

The nose is shaped as a pyramid. The nasal pyramid is an osteocartilaginous structure, covered with soft tissues that include skin, subcutaneous tissue, muscle, and epithelium.

The surface anatomy of the nose is shown in Figure 35-1 and this is the terminology that will be used in the text. The osteocartilaginous framework of the nose is illustrated in Figure 35-2. The nose can be divided into three components (Sheen, 1978): the *bony vault* (frontal processes of maxilla and nasal bones), the *upper cartilaginous vault* (upper lateral cartilages), and the *lower cartilaginous vault* (medial and lateral crura, alae, alar lobules, nostril vestibules and sills, columella, and membranous septum).

The nasal pyramid has two openings at its base, the *external nares* (Fig. 35-3). These inlets for the nasal airway admit air into the nasal vestibules, delimited posteriorly by the *internal nares*, frequently referred to as the nasal valves (Mink, 1920). It is these valvelike structures that control the air flow into the nasal fossae proper, paired cavities separated in the midline by the nasal septum. The convergence and divergence of the nasal valves open and close the internal nares, thus controlling the air flow into the nasopharyngotracheal airway. The nasal fossae drain the accessory sinuses and the lacrimal apparatus. A small portion of the nasal mucous near the cribriform plate is specifically olfactory in function.

Covering Soft Tissues of Nose. At the tip, the skin of the nose is tightly bound to the alar cartilages; in contrast, the skin and musculature are loosely attached and mobile over the lateral cartilages and nasal bones. The skin is rich in sebaceous glands over the caudal portion of the nose. The arteries and veins of the nose are situated in the soft tissues; the plane of dissection in nasal operations should therefore be close to the os-

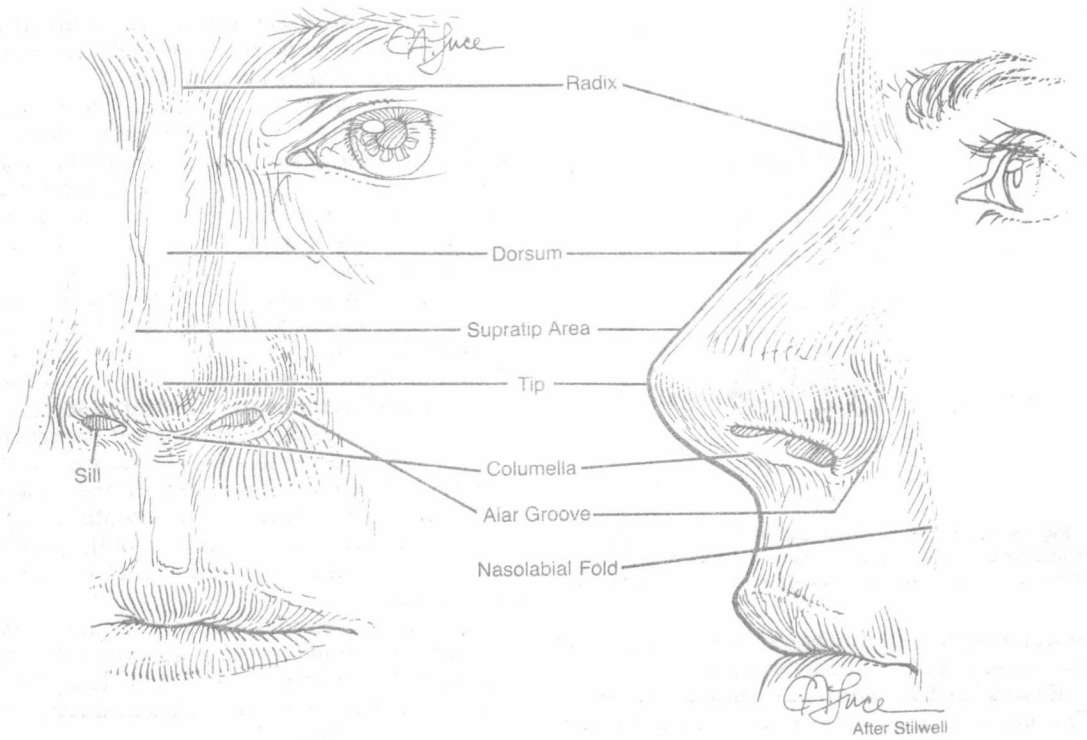


Figure 35-1. Surface anatomy of the nose.

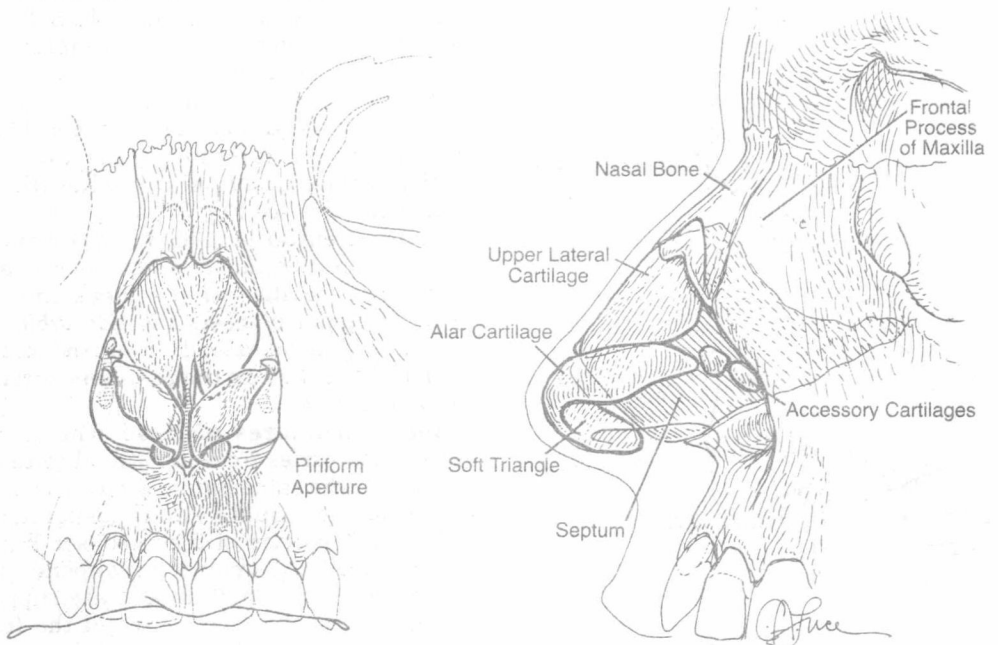


Figure 35-2. Osteocartilaginous framework of the nose.

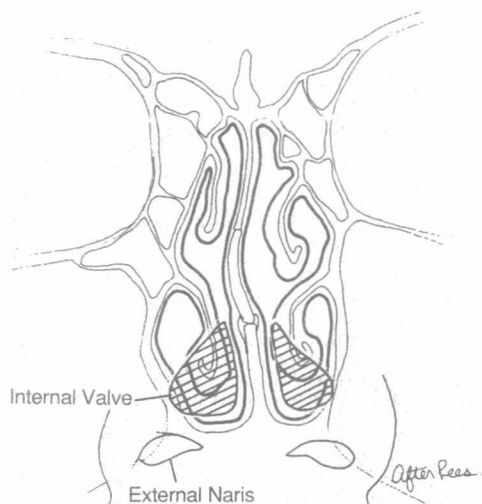


Figure 35-3. The external and internal nares. Note the relationship of the nasal vestibule (crosshatched) to the entire nasal cavity and especially to the inferior turbinate.

teocartilaginous framework to avoid injury to the vessels and unnecessary bleeding.

Essential External Landmarks of Nose.

The *dorsum* or *bridge* of the nose is formed in part by the bony nose and in part by the cartilaginous nose (see Fig. 35-1). It is essential that a uniform terminology be employed to designate the various portions of the nose.

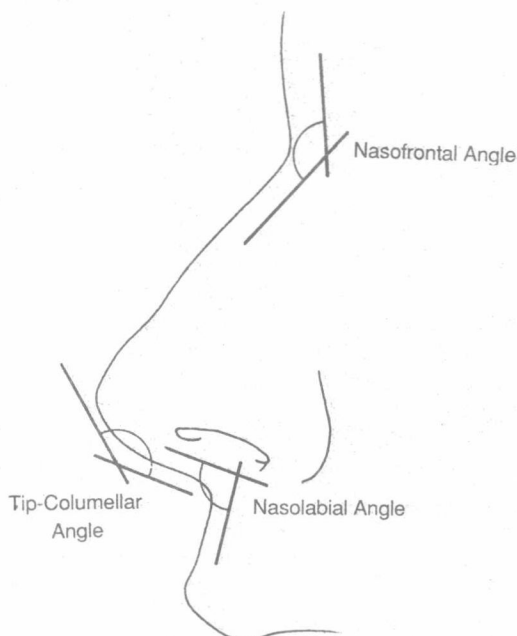


Figure 35-4. The surface angles of the nose.

The *nasofrontal angle* (Fig. 35-4) is the area where the nose joins the forehead, the *radix* or *root* of the nose (the *radix nasi*).

Above (cephalad to) the tip of the nose is the *supratip* area. This area usually overlies the septal angle of the quadrangular cartilage of the septum. The *septal angle* is a convenient term for the angle formed by the caudal and dorsal borders of the septal cartilage (Converse, 1955).

The *tip* of the nose is formed by the junction of the two alae of the nose. Confusion has resulted from the use of the term "lobule." The noun "lobule" originates from the Greek *lobos*, which became in late Latin *lobus*, a term that designated a hanging structure such as the lobe of the ear. The nose consists of fixed and mobile structures. If one wishes to use the term "lobule," it is acceptable as a descriptive term for the lower mobile part of the nose: tip, alae, columella, and membranous septum.

The base or caudal portion of the nasal pyramid is formed by the nostrils and the *columella*. The nostrils can also be designated as the external nares, in contradistinction to the internal nares.

The nostrils or nares are the point of entry of air into the nose. The columella joins the tip of the nose to the upper lip and separates the two external nares. The *sills* are the slightly protuberant floors of the nostrils. The junction of the base of the columella with the upper lip defines the *nasolabial angle*. Sheen (1978) emphasized the *columellar-lobular junction* as an important landmark in grafting techniques of the nasal tip. The *tip-columellar angle* is formed by the intersection of the surface plane of the columella with that of the tip (see Fig. 35-4).

Other essential landmarks of the external nose include the *alar groove*, which is at the junction of the ala with the cheek and which in its midportion meets the *nasolabial fold*. The alar groove extends over the cephalic border of the alar cartilage, where it forms a shallow furrow.

Bony Structures of Nose. The anatomy of the nose varies from individual to individual within the same ethnic group and according to the individual's ethnic background.

The bony portion of the nose (see Fig. 35-2) is formed by the paired nasal bones; these are joined in the midline and are supported posteriorly by the nasal spine of the frontal bone and laterally by the frontal process of the maxilla. The osseous lateral walls of the

nose are formed by the nasal bones and frontal processes of the maxilla (bony vault).

The nasal bones are quadrangular, thick, and narrow above and thin and wide below (Fig. 35-5 and see Fig. 35-2); their anterior surface is concave from above downward in the upper portion, convex from side to side. The thicker and stronger cephalic portion of the nasal bones is further reinforced by the nasal spine of the frontal bone, which lends additional support to this part of the bony bridge. The caudal borders of the nasal bones show a concave curve, the lateral portion of each bone extending downward along the edge of the piriform aperture (Fig. 35-5B). The frontal process of the maxilla is a plate of bone, thick below and thinner above, which projects upward and medially from the body of the maxilla, forming the edge of the piriform aperture (Fig. 35-5C), the lower boundary of the lateral nasal wall. The posterior border of the frontal process of the maxilla forms the lacrimal groove with the neighboring lacrimal bone (Fig. 35-5C).

The frontal process of the maxilla forms the anterior lacrimal crest. The medial canthal tendon inserts upon the anterior and posterior lacrimal crests, and some fibers reach the suture line between the nasal bone and the frontal bone.

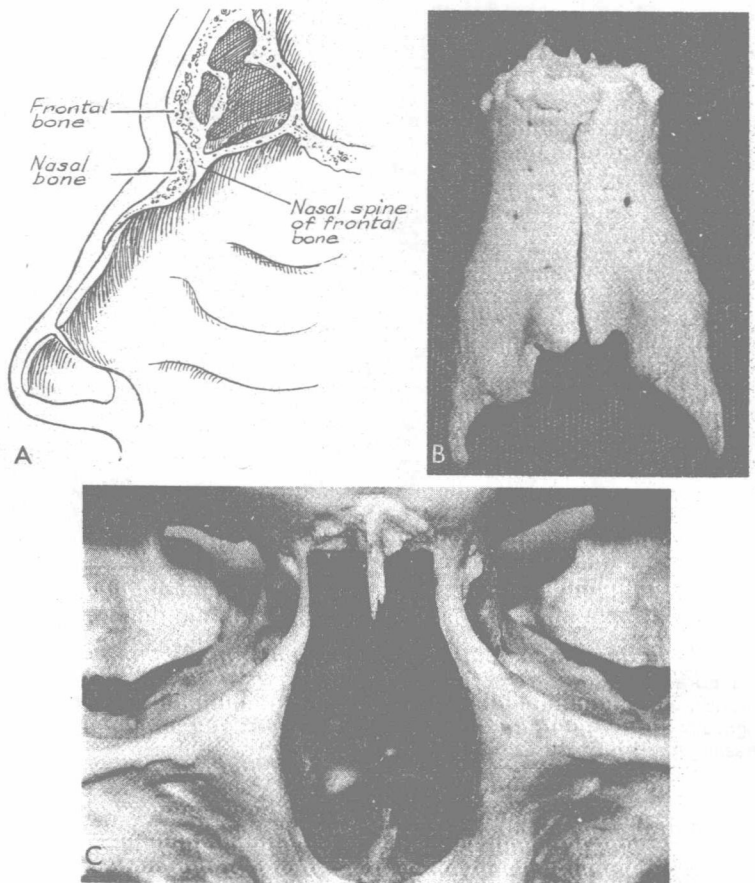
Cartilaginous Structures of Nose

Lateral (Upper Lateral) Cartilages.

During embryologic development, the nasal cartilages are formed from a portion of the chondrocranium, the cartilaginous nasal capsule, which is a paired structure. This explains embryologic abnormalities such as duplication of the septum or duplication of the entire nose as seen in midline cleft syndromes.

The lateral cartilages are paired structures, roughly triangular in shape, attached to the nasal bones and frontal processes of the maxilla above and to the septal cartilage in the midline (Fig. 35-6). The attachment of the lateral cartilages to these structures and to the septum is described later in the text. The lower third of the lateral cartilages diverges

Figure 35-5. The bony framework of the nose. A, Sagittal section illustrating the thicker cephalic portion of the nasal bones reinforced by the nasal spine of the frontal bone. B, The nasal bones. C, The piriform aperture.




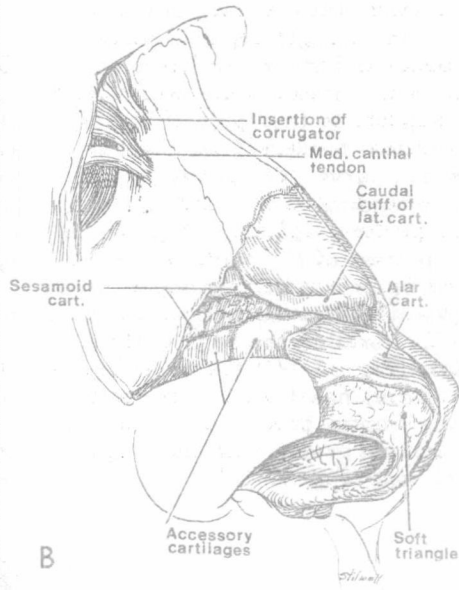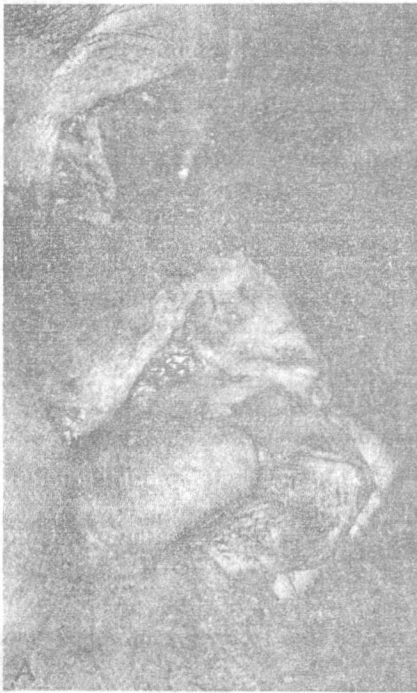


Figure 35-6. Dissection of the nose to demonstrate cartilage relationships. A, The nasal bone, frontal process of the maxilla, upper lateral and alar cartilage, and accessory cartilages are shown in the dissection and outlined in B. C, The right alar cartilage with the accessory cartilages. (From Firmin, F., and Le Pesteur, J.: *Reflexions sur l'ouvert cartilagineux nasal*. *Ann. Chir. Plast.*, 22:1, 1977.)

from the septum, becomes mobile, and constitutes the internal valves of the nose.

The lower portion of each lateral cartilage is thicker and turns on itself, forming a cuff (Fig. 35-6). This characteristic was noted by Testut and Jacob (1929) and other anatomists, who also described small sesamoid cartilages that are present between the lateral cartilage and the alar cartilage that overlaps the lateral cartilage. The small sesamoid cartilages appear to act as roller bearings, facilitating the movement of the alar cartilage over the lateral cartilage (Firmin and Le Pesteur, 1977).

The lateral margin of the lateral cartilage is joined to the edge of the piriform aperture except in its lower portion, where the area of the junction varies.

The cartilages of the nose are subjected to movements by the nasal musculature (Fig. 35-7) that play an important role in nasal physiology (Zide, 1985). The closure of the nasal valves is affected by compression of the cephalic portion of the lateral crura of the alar cartilages that overlap the lateral cartilages (Van Dishoek, 1937). The preservation of the mobility of the caudal portion of the nose is essential for the function of these muscles. Their function is inhibited in facial paralysis; the cartilages of the nose are immobile owing to paralysis of the musculature, and an inadequate nasal airway is noted on the paralyzed side (Fig. 35-8).

The alar cartilages are connected to the lateral cartilages by loose connective tissue that facilitates their cephalic displacement over the lateral cartilages.

The cartilaginous external nose is situated caudad and anterior to the piriform aperture. The piriform aperture, the base of the nasal pyramid, is a pear-shaped skeletal opening to the nasal fossae. It is bounded above by the lower borders of the nasal bones and laterally by the frontal processes of the maxilla, the thin, sharp margins of which extend downward, where they curve medially to join each other at the anterior nasal spine.

Nasal Septum and Septal Cartilage. The nasal septum is a midline structure that divides the nasal cavity into two lateral chambers. The septal framework is composed of bony and cartilaginous constituents: the four bony components of the osseous septum (the perpendicular plate of the ethmoid, the vomer, the nasal crest of the maxilla, the nasal crest of the palatine bone), and the

septal cartilage. The septal cartilage has a posterior extension into the ethmoid plate (Fig. 35-9).

The septal cartilage is a quadrangular lamina that forms the major portion of the framework of the caudal portion of the septum; it protrudes in front of the piriform aperture. The septal angle is located immediately cephalad to the alar cartilages in an area referred to as the supratip area. This finding can be demonstrated by digital pressure on the nasal tip applied in a caudal direction. Blanching of the overlying skin is observed at the septal angle.

The lower portion of the septal cartilage is firmly bound to the vomer and the premaxillary wings, the perichondrium of the cartilage being continuous with the periosteum of the vomer. The caudal part of the septal cartilage is more mobile and flexible. The perichondrium of the septal cartilage extends outward to join the periosteum of the wider groove in the premaxillary wings and the flat surface of the nasal spine, thus simulating a joint capsule within which lateral movements of the septal cartilage are possible. The plasticity of this portion of the septum increases the flexibility of the septal cartilage. The caudal margin of the septal cartilage is separated from the columella (and medial crura) by the juxtaposition of two mucocutaneous flaps that form the *membranous septum*.

The mobility of the lower portion of the septal cartilage and of the membranous septum permits side to side movement and, together with the resilient lateral and alar cartilages, accounts for the shock-absorbing role of these structures in preventing nasal fractures as well as more severe craniofacial injuries.

The cephalic portion of the dorsal border of the septal cartilage, intimately connected with the cephalic portion of the lateral cartilages, extends under the nasal bones, where it is received in a shallow bony groove. The posterior border is connected to the perpendicular plate of the ethmoid; the posterior extension of the septal cartilage separates a portion of the ethmoid plate from the vomer (see Fig. 35-9).

The cephalic portion of the septal cartilage is usually thicker, constituting at its junction with the ethmoid plate a strong, fixed, *central pillar* supporting the nasal bones. The preservation of the central pillar is of considerable importance in rhinoplasty when all the struc-

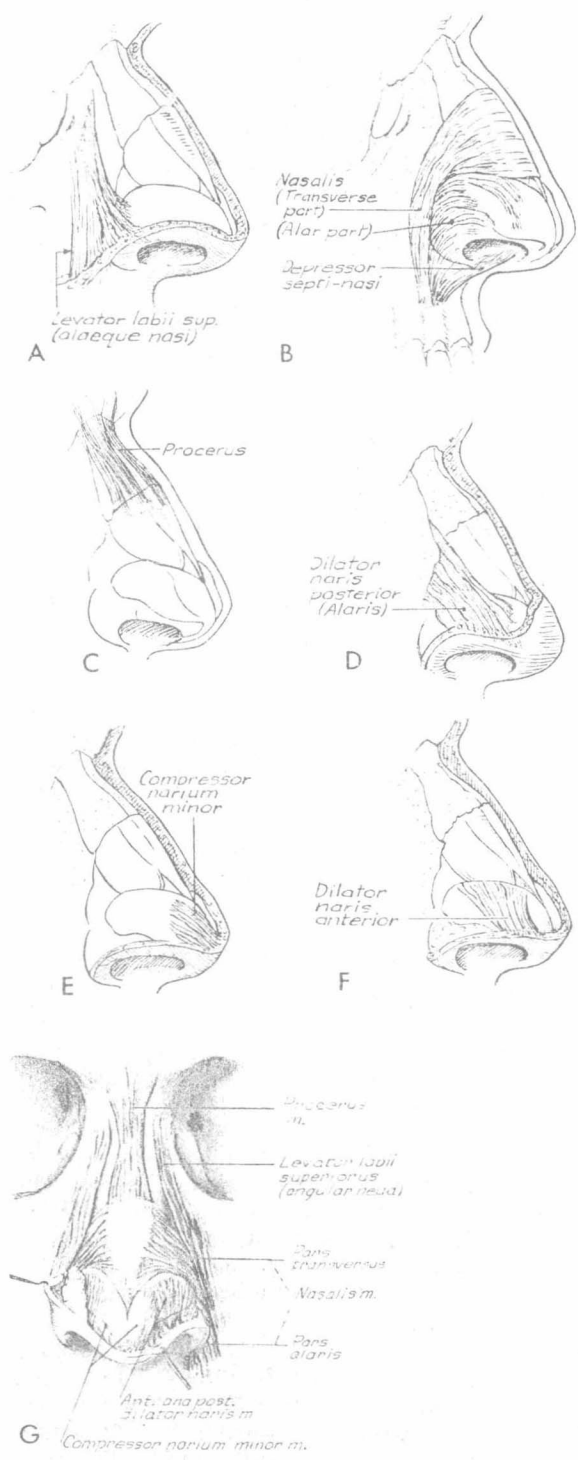


Figure 35-7. The muscles of the nose.

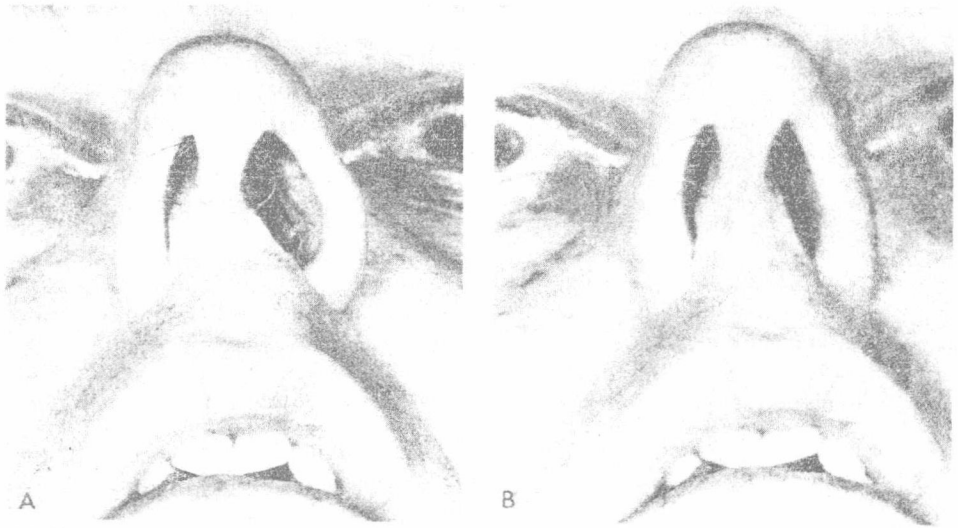


Figure 35-8. Loss of function of the ala in facial paralysis. *A*, The nose during inspiration. On the unaffected left side, the naris opens; on the paralyzed right side, the ala is immobile. *B*, The paralyzed right ala also remains collapsed during expiration.

tures of the nose have been mobilized and only the central pillar remains to support the dorsum.

The relationship of the upper lateral cartilages to the nasal bones is established during the embryologic development of these structures. The overlapping of the nasal bones over the cephalic portion of the lateral cartilages may extend for 8 to 10 mm (see Fig. 35-2; Fig. 35-10). The fusion of the perichondrium and the periosteum through dense connective tissue results in an intimate

relationship between the cartilage and bone. The overlapping area is oval in shape. The maximal length of the oval is at the junction of the nasal bones; as the frontal process is reached, the overlap is only a few millimeters. This intimate relationship is of clinical significance in fractures and in rhinoplastic procedures; it explains why the lateral cartilage is displaced medially with the bony lateral wall following lateral osteotomy.

The dorsal border of the cartilaginous nasal septum undergoes alteration in width and configuration in the area of the nasal bones and bifurcates into a Y, forming a supraseptal groove between the limbs of the Y (Fig. 35-10). The groove is readily seen and palpated in some individuals, but it is usually indistinguishable on the surface, being masked by the perichondrium, connective tissue, the aponeurosis of the nasalis muscle, and subcutaneous tissue. The supraseptal groove is wide near the junction with the nasal bones and tapers toward the septal angle.

The nasal hump, often a prominent portion of the dorsum, is formed by the nasal bones, the widened portion of the septal cartilage, and the lateral cartilages. The dorsal hump is fusiform, narrow above, wide near the junction of the lateral cartilages and nasal bones, and narrow above the septal angle. The nasal hump varies in its osseous and cartilaginous composition.

The lateral and septal cartilages are intimately connected near the nasal bones. In the series of sections obtained from cadaver

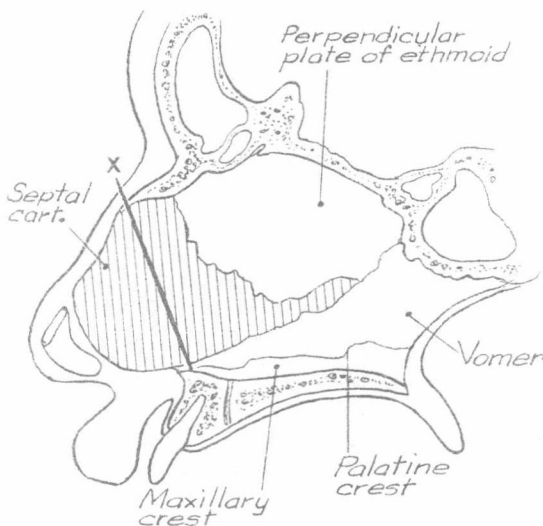


Figure 35-9. The nasal septum. The line X indicates the line of demarcation between the fixed and the flexible portion of the nasal septum.