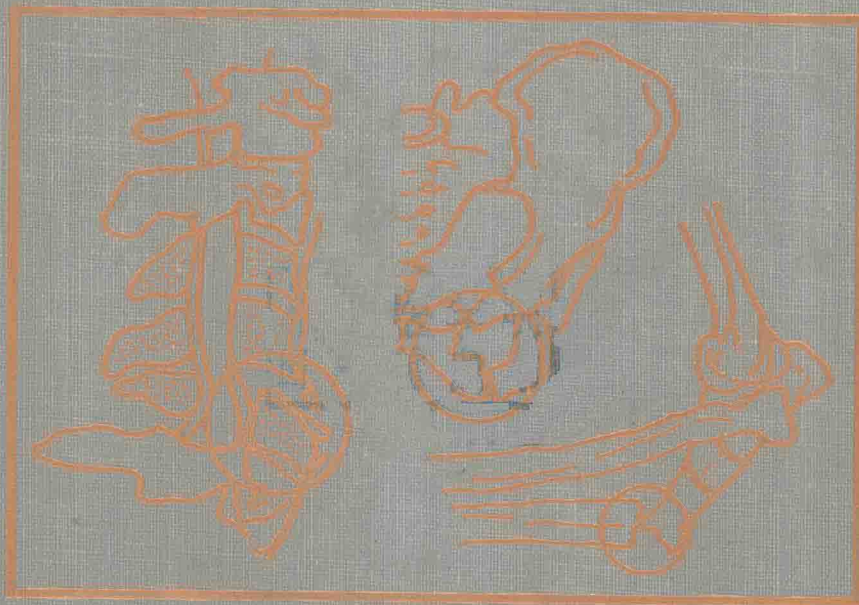


Second Edition

**IMAGING  
OF  
ORTHOPEDIC  
TRAUMA**

Edited by

**Thomas H. Berquist**



Raven Press

# Imaging of Orthopedic Trauma

---

*Second Edition*

---

· Editor

**Thomas H. Berquist, M.D., F.A.C.R.**

*Professor of Radiology  
Mayo Medical School  
Chairman  
Diagnostic Radiology  
Mayo Clinic Jacksonville  
Jacksonville, Florida*

Raven Press  New York

Raven Press, Ltd., 1185 Avenue of the Americas, New York, New York 10036

---

© 1992 by Mayo Clinic. All rights reserved. This book is protected by copyright. No part of it may be reproduced, stored in a retrieval system, or transmitted, in any form or by any means, electronic, mechanical, photocopying, recording, or otherwise, without the prior written permission of the publisher.

Made in the United States of America

Library of Congress Cataloging in Publication Data

Imaging of orthopedic trauma/editor, Thomas H. Berquist.—2nd ed.

p. cm.

Rev. ed. of: Imaging of orthopedic trauma and surgery.

Includes bibliographical references and index.

ISBN 0-88167-805-8

1. Radiography in orthopedics. 2. Musculoskeletal system—Wounds and injuries—Imaging. I. Berquist, Thomas H. (Thomas Henry), 1945–

II. Imaging of orthopedic trauma and surgery.

[DNLM: 1. Bone and Bones—injuries. 2. Bone and Bones—radiography. 3. Fractures—radiography. WE 200 I31]

RD734.5.R33143 1991

617.1'5—dc20

DNLM/DLC

for Library of Congress

91-21827

CIP

---

The material contained in this volume was submitted as previously unpublished material, except in the instances in which some of the illustrative material was derived.

Great care has been taken to maintain the accuracy of the information contained in the volume. However, neither Raven Press nor the editor can be held responsible for errors or for any consequences arising from the use of the information contained herein.

Materials appearing in this book prepared by individuals as part of their official duties as U.S. Government employees are not covered by the above-mentioned copyright.

9 8 7 6 5 4 3 2 1

Imaging  
of  
Orthopedic  
Trauma

---

*Second Edition*

To my wife, Kay,  
and sons, Aric, Matthew, and Andrew

# Contributors

---

---

- Claire E. Bender, M.D.,** *Department of Diagnostic Radiology, Mayo Medical School, Mayo Clinic, 200 First St. S.W., Rochester, Minnesota 55905*
- Thomas H. Berquist, M.D., F.A.C.R.,** *Department of Diagnostic Radiology, Mayo Medical School, Mayo Clinic Jacksonville, 4500 San Pablo Rd., Jacksonville, Florida 32224*
- Manuel L. Brown, M.D.,** *Department of Diagnostic Radiology and Laboratory Medicine, Mayo Medical School, Mayo Clinic, 200 First St. S.W., Rochester, Minnesota 55905*
- Miguel E. Cabanela, M.D.,** *Department of Orthopedic Surgery, Mayo Medical School, Mayo Clinic, 200 First St. S.W., Rochester, Minnesota 55905*
- Donald C. Campbell II, M.D.,** *Department of Orthopedic Surgery, Mayo Medical School, Mayo Clinic, 200 First St. S.W., Rochester, Minnesota 55905*
- Joseph R. Cass, M.D.,** *Orthopedic Center, 1301 South Ninth Ave., Sioux Falls, South Dakota 57105*
- Robert H. Cofield, M.D.,** *Department of Orthopedic Surgery, Mayo Medical School, Mayo Clinic, 200 First St. S.W., Rochester, Minnesota 55905*
- Kay L. Cooper, M.D.,** *Department of Diagnostic Radiology, Mayo Medical School, Mayo Clinic, 200 First St. S.W., Rochester, Minnesota 55905*
- Mark B. Coventry, M.D.,** *Department of Orthopedic Surgery, Mayo Medical School, Mayo Clinic, 200 First St., S.W., Rochester, Minnesota 55905*
- James K. DeOrio, M.D.,** *Department of Orthopedic Surgery, Mayo Medical School, Mayo Clinic Jacksonville, 4500 San Pablo Rd., Jacksonville, Florida 32224*
- Glenn S. Forbes, M.D.,** *Department of Diagnostic Radiology, Mayo Medical School, Mayo Clinic, 200 First St. S.W., Rochester, Minnesota 55905*
- E. Meredith James, M.D.,** *Department of Diagnostic Radiology, Mayo Medical School, Mayo Clinic, 200 First St. S.W., Rochester, Minnesota 55905*
- Kenneth A. Johnson, M.D.,** *Department of Orthopedic Surgery, Mayo Medical School, Mayo Clinic, 13400 E. Shea Blvd., Scottsdale, Arizona 85259*
- Gerald R. May, M.D.,** *Department of Radiology, Providence Hospital, 500 17th Ave., Seattle, Washington 98124*
- Bernard F. Morrey, M.D.,** *Department of Orthopedic Surgery, Mayo Medical School, Mayo Clinic, 200 First St. S.W., Rochester, Minnesota 55905*
- Douglas J. Pritchard, M.D.,** *Department of Orthopedic Surgery, Mayo Medical School, Mayo Clinic, 200 First St. S.W., Rochester, Minnesota 55905*
- James A. Rand, M.D.,** *Department of Orthopedic Surgery, Mayo Medical School, Mayo Clinic, 200 First St. S.W., Rochester, Minnesota 55905*
- John G. Stears, R.T.(R),** *Mayo School of Health Related Sciences, Radiology Program, Mayo Clinic, 200 First St. S.W., Rochester, Minnesota 55905*

**Timothy J. Welch, M.D.,** *Department of Diagnostic Radiology, Mayo Medical School, Mayo Clinic, 200 First St. S.W., Rochester, Minnesota 55905*

**Norlin T. Winkler, R.T.(R),** *Mayo School of Health Related Sciences, Mayo Medical School, Mayo Clinic, 200 First St. S.W., Rochester, Minnesota 55905*

**Michael B. Wood, M.D.,** *Department of Orthopedic Surgery, Mayo Medical School, Mayo Clinic, 200 First St. S.W., Rochester, Minnesota 55905*

# Preface

---

---

Since the first edition of this text, there have been many new developments in orthopedic radiology. New imaging techniques have progressed significantly, specifically magnetic resonance imaging. Other diagnostic and interventional techniques also have expanded over the last few years. The goal of this edition does not differ significantly from that of the first. Once again, communication between the imagers or radiologists and orthopedic surgeons is emphasized.

As in the first edition, the initial three chapters of this text discuss basic concepts in diagnostic imaging techniques, fracture healing, and soft tissue injury. The diagnostic technique section has been refined to concentrate more fully on those techniques used specifically for evaluation and follow-up of traumatic injuries. The chapter on diagnostic imaging, Chapter 1, is again intended to combine basic principles with sufficient detail to afford an understanding of the mechanics of these techniques so that repetition in later chapters is not necessary. A chapter on soft tissue injuries, Chapter 3, has been added largely because of the significant impact of MRI in evaluating these types of injuries. It is now important for the radiologist to understand the mechanisms of soft tissue injury and healing as well as certain classifications commonly used by orthopedic surgeons.

The main body of the text (Chapters 4–14) addresses imaging in adult trauma, including evaluation of post-reduction treatment techniques. The chapters are anatomically oriented with a review of essential musculoskeletal anatomy in the introductory section of each chapter, followed by a discussion of routine radiographic techniques and special techniques as they relate to the specific anatomic region. The clinical aspects of specific bone and soft tissue injuries are included in each section. The illustrations have been carefully selected to demonstrate how certain techniques are more pertinent for a specific clinical problem. Orthopedic classifications and treatment techniques are discussed as they apply to each anatomic area.

The final chapters, Chapters 15 and 16, discuss stress fractures and infection related to post-traumatic injury. Again, the emphasis is placed on imaging of these specific problems.

This text provides a comprehensive, well-referenced resource for radiologists, orthopedic surgeons and other clinicians, or residents in training who deal with trauma. The contributions of the radiologists and orthopedic surgeons in preparing each section of this text demonstrates the importance of communication and dialogue in daily clinical practice. The end result of this improved communication will be optimal use of the many imaging techniques in providing improved patient care.



# Acknowledgments

---

---

Preparation of a comprehensive reference text requires the support of numerous individuals. Many colleagues provided daily assistance in obtaining representative material. I especially want to thank the residents in diagnostic radiology and orthopedic surgery who assisted in collecting these cases. William Mundstock, Ken McEwen, Tim Kodet, and their technology staff provided invaluable assistance in obtaining radiographs of special views frequently used in orthopedic practice. Both Sue Ramthun and Tim Kodet deserve special mention for their assistance in posing for demonstrations of radiographic positioning techniques.

The department of photographics provided quality radiographic prints for publication. James Martin and Tom Flood were especially helpful in this regard. The expertise of Elman Hanken was valuable in filming patient positioning techniques.

The medial graphics department headed by Bob Benassi, with direct assistance from Tammy Bell, John Hagen, John Hutchison, and Jack Nelson, provided excellent illustrations demonstrating classifications and specific injuries.

The manuscript was prepared by secretaries in diagnostic radiology and orthopedic surgery. Special thanks are due to my secretaries, Cindy Franke and Rebecca Richmond, for their diligence and patience in preparing the manuscript, tables, and lengthy bibliography.

Finally, I wish to thank Mary Rogers, my editor and the president of Raven Press, and the production staff, especially Nicholas Radhuber.

# Contents

---

---

Contributors .....	ix
Preface .....	xi
Acknowledgments .....	xii
<b>1. Diagnostic Techniques</b> .....	<b>1</b>
<i>Claire E. Bender, Thomas H. Berquist, John G. Stears, Norlin T. Winkler, E. Meredith James, Manuel L. Brown, Timothy J. Welch, Gerald R. May, and Glenn S. Forbes</i>	
<b>2. Fracture Healing</b> .....	<b>39</b>
<i>James A. Rand and Thomas H. Berquist</i>	
<b>3. Soft Tissue Injuries</b> .....	<b>83</b>
<i>Thomas H. Berquist and James K. DeOrio</i>	
<b>4. The Spine</b> .....	<b>93</b>
<i>Thomas H. Berquist and Miguel E. Cabanela</i>	
<b>5. The Pelvis and Hips</b> .....	<b>207</b>
<i>Thomas H. Berquist and Mark B. Coventry</i>	
<b>6. The Femur and Thigh</b> .....	<b>311</b>
<i>Claire E. Bender, Donald C. Campbell II, and Thomas H. Berquist</i>	
<b>7. The Knee</b> .....	<b>333</b>
<i>James A. Rand and Thomas H. Berquist</i>	
<b>8. The Tibia, Fibula, and Calf</b> .....	<b>433</b>
<i>Claire E. Bender, Donald C. Campbell II, and Thomas H. Berquist</i>	
<b>9. The Foot and Ankle</b> .....	<b>453</b>
<i>Thomas H. Berquist, Bernard F. Morrey, Joseph R. Cass, and Kenneth A. Johnson</i>	
<b>10. The Shoulder</b> .....	<b>579</b>
<i>Robert H. Cofield and Thomas H. Berquist</i>	
<b>11. The Humerus and Arm</b> .....	<b>659</b>
<i>Claire E. Bender, Donald C. Campbell II, and Thomas H. Berquist</i>	
<b>12. The Elbow</b> .....	<b>675</b>
<i>Bernard F. Morrey and Thomas H. Berquist</i>	
<b>13. The Radius, Ulna, and Forearm</b> .....	<b>731</b>
<i>Claire E. Bender, Donald C. Campbell II, and Thomas H. Berquist</i>	
<b>14. The Hand and Wrist</b> .....	<b>749</b>
<i>Michael B. Wood and Thomas H. Berquist</i>	

<b>15.</b>	Imaging of Post-traumatic Infection .....	871
	<i>Thomas H. Berquist and Manuel L. Brown</i>	
<b>16.</b>	Stress Fractures .....	881
	<i>Thomas H. Berquist, Kay L. Cooper, and Douglas J. Pritchard</i>	
	Subject Index .....	895

## CHAPTER 1

# Diagnostic Techniques

Claire E. Bender, Thomas H. Berquist, John G. Stears, Norlin T. Winkler,  
E. Meredith James, Manuel L. Brown, Timothy J. Welch, Gerald R. May,  
and Glenn S. Forbes

---

---

### **Routine Radiography, 1**

- Equipment, 2
- Screen-Film Combinations, 3
- Radiation Protection, 7
- Film Labeling, 7

### **Tomography, 7**

- Blurring and Section Thickness, 7
- Tube Motion in Orthopedic Tomography, 8
- Summary, 9

### **Magnification Radiography, 11**

- Equipment and Principles of Magnification, 11
- Advantages and Limitations, 12

### **Ultrasound, 12**

- Real-time Scanners, 12
- Doppler, 13
- Orthopedic Applications, 13

### **Skeletal Scintigraphy, 16**

- Radiopharmaceuticals Used in Bone Scanning, 16
- Instrumentation, 17
- Clinical Applications, 17
- Trauma, 17
- Vascularity of Bone, 18
- Infection, 19
- Further Clinical Applications, 19

### **Computed Tomography, 19**

- Equipment, 19
- Techniques, 20
- Indications, 22

### **Magnetic Resonance Imaging, 22**

- Clinical Techniques, 23
- Patient Selection, 23
- Patient Positioning and Coil Selection, 24
- Pulse Sequences and Imaging Parameters, 25
- Clinical Applications, 25

### **Angiography, 26**

- Equipment, 26
- Technique, 28
- Indications, 28

### **Myelography, 28**

- Technique, 29
- Normal Myelographic Anatomy, 29
- Indications, 30

### **Introduction to Arthrography, 30**

- Equipment, 31
- Contrast Material, 33
- Complications, 33

### **References, 33**

---

There are multiple imaging techniques that are of diagnostic importance in evaluating orthopedic problems. Table 1-1 provides a list of the major techniques used in

musculoskeletal evaluation. Proper application of these techniques is essential in obtaining optimal diagnostic information. In this chapter we will provide the background information and indications for each of the modalities listed in Table 1-1. This information will be applied in subsequent chapters in discussing the radiographic evaluation of orthopedic problems.

---

C. E. Bender, J. G. Stears, N. T. Winkler, E. M. James, T. J. Welch, G. S. Forbes: Department of Diagnostic Radiology, Mayo Medical School, Mayo Clinic, Rochester, Minnesota 55905.

T. H. Berquist: Department of Diagnostic Radiology, Mayo Medical School, Mayo Clinic Jacksonville, Jacksonville, Florida 32224.

G. R. May: Department of Radiology, Providence Hospital, Seattle, Washington 98124.

## **ROUTINE RADIOGRAPHY**

Routine radiography remains the mainstay for diagnostic evaluation of orthopedic problems. This section will discuss equipment, radiation protection, film identi-

**TABLE 1-1.** *Diagnostic techniques in orthopedic trauma*

Routine radiography
Conventional tomography
Linear motion
Complex motion
Magnification radiography
Ultrasonography
Skeletal scintigraphy
Computed tomography
Magnetic resonance
imaging
Angiography
Myelography
Arthrography
Tenography

fication, and other background material necessary for radiography of consistently high quality. Specific positioning techniques will be discussed in future chapters as appropriate.

Thorough radiographic evaluation of any condition requires high quality films. These cannot be obtained without properly functioning equipment, proper screen-film combinations, and technical consistency. Communication between the examining physician, the radiologist, and the technologist performing the examination is essential. The proper views will be obtained only if the information concerning the patient's situation is properly distributed.

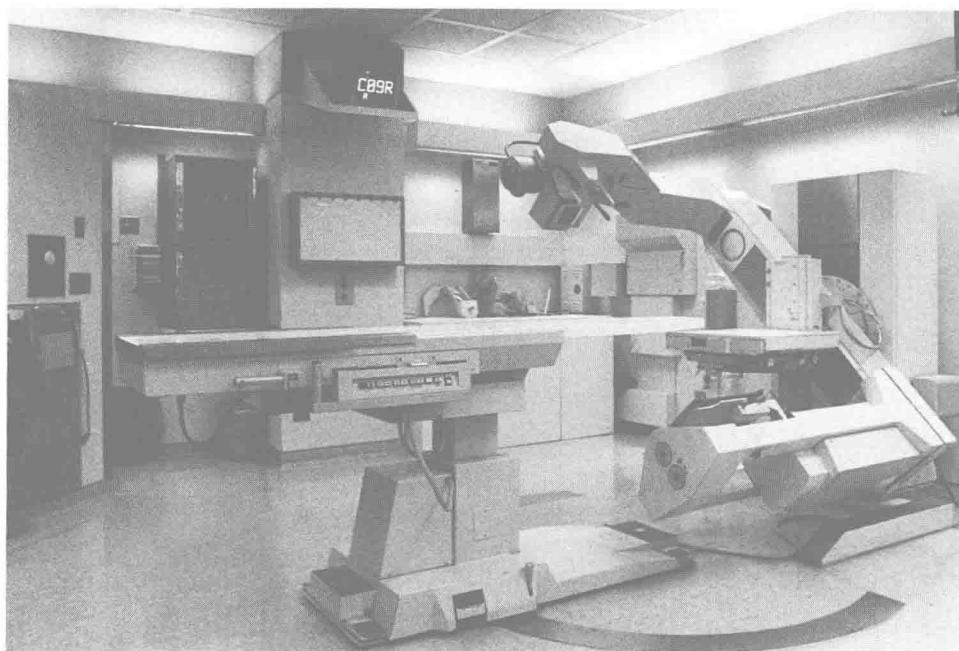
### Equipment

The following equipment is used in our department for routine orthopedic radiography: (1) a 3-phase, 12-

pulse x-ray generator, (2) Eimac AZ92 x-ray tubes with a 0.6-mm focal spot, and (3) 4-way floating tables. Radiography of the axial skeleton is performed at a 48-inch source-to-film distance (Bucky grid technique, 16:1 ratio), with Kodak X-omatic cassettes, Lanex medium screens, and Kodak TML film. Extremity radiographs are obtained with Kodak Lanex fine screens, and Kodak TML film.

For the acutely traumatized patient we use a dedicated radiographic room adjacent to the emergency room. The equipment includes a Kermath Versitome table with a U-arm system capable of performing all routine radiographs as well as tomography in the lateral, oblique, anteroposterior (AP), and transaxial directions (Fig. 1-1). The room is also equipped with a modern life-support system. With such a dedicated emergency unit we can obtain radiographs in all directions without moving the patient. The same film and screens are used in the trauma room.

Selection of the proper recording medium (films and screens) is essential in obtaining radiographs of consistently high quality. The choice of screen-film combinations is complicated by the number of combinations available. There are approximately 40 different screens and 80 different films on the market. Various screen-film combinations can produce radiographs with a broad spectrum of sensitivity, contrast, and resolution characteristics. Generally, the optimum combination will be a compromise between the image quality desired, available equipment, and patient-exposure factors. The ideal combination would insure high speed, high detail, high contrast, and wide latitude. However, these factors tend to oppose one another. High-speed systems tend to



**FIG. 1-1.** Radiographic trauma unit. Versigraph with multiple angle tomographic capability, life-support equipment, and ample space for managing critically injured patients.

have lower resolution characteristics, and high-contrast systems are low in latitude. Institutions with small generators may have to sacrifice resolution for a higher-speed system because of equipment limitations (2).

### Screen-Film Combinations

It is common to describe screen-film sensitivity or speed using a relative speed index (Fig. 1-2). The index is built around a par-speed calcium tungstate intensifying screen and par-speed film equaling 100, assuming optimal processing conditions. For comparison, a system is assigned a number that expresses its speed relative to the standard. Therefore, systems that are twice as fast as the standard (requiring half the exposure time) are 200 speed. Systems with one-half the speed (requiring twice the exposure time) are assigned a speed index of 50. Of the two components of the screen-film combination, the intensifying screen exerts the most influence on speed and resolution characteristics.

Many manufacturing processes are used in tailoring an intensifying screen for the desired characteristics. However, the phosphor material used in the screen is the major variable influencing the speed of the system. The currently used phosphors vary in their ability to convert photons to usable light and can be ranged in a scale of one to nine. In general, the calcium tungstate phosphors are least efficient and the rare earth phosphors most efficient, with other materials falling in between (6). Figure 1-2 lists some of the commonly used phosphor materials and the anticipated relative speed of the system.

The color of light emitted by the phosphor is an important consideration. Most of the phosphors, with the exception of the rare-earth family, emit light in the blue or ultraviolet range. Rare-earth phosphors emit light in the green region of the spectrum. However, activators used in the phosphors can be altered, resulting in a shift of the color into the blue portion of the spectrum. Care

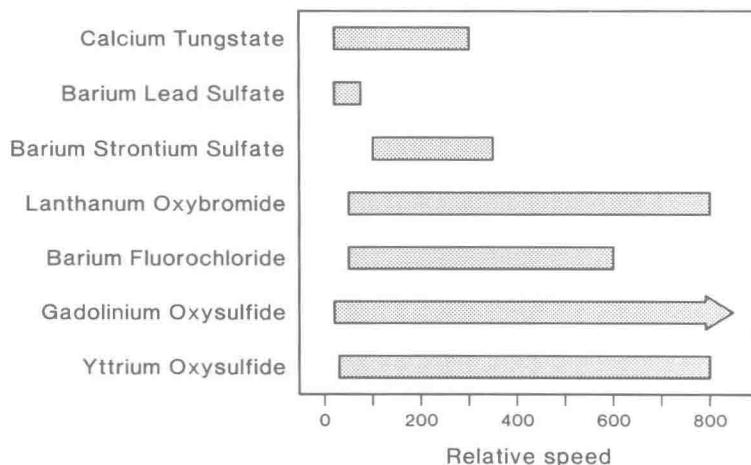
must be taken in selection of film to be certain that the film is sensitive to the color emitted by the screen.

In addition to the effects of spectral sensitivity, the film selected can also alter the speed of the system and the contrast of the radiographs. Excluding single-emulsion films, most manufacturers provide film that ranges in speed by a factor of two within the spectral-sensitivity groups. This variation in the speed of the film offers control over the contrast of the images, which can be adjusted through use of different types of film. These films are designated as latitude, medium-contrast, or high-contrast. Latitude films are designed to image a broad range of radiographic densities, such as soft tissue and bone. High-contrast films are designed to enhance subtle changes in contrast, and medium-contrast films range somewhere between latitude and high-contrast films.

In selecting a screen-film combination, the intensifying screen or screens should be chosen according to the required speed and resolution. Detail or extremity systems often use one intensifying screen. Desired image contrast and control of speed are options to be considered in the selection of radiographic films.

What is considered to be an optimal system should be determined within each institution. In theory, multiple screen-film combinations would be needed to obtain optimal results for each specific radiographic examination; however, this approach increases the potential for human error and inconsistency. Many departments select one screen-film system for all examinations or purchase different types of cassettes to assist in identification of the combinations within the department. In general, we use a 300-speed system for the axial skeleton and proximal extremities and an 80-speed system for the distal extremities. Proper choice of screen-film combinations will help maintain consistent radiographic quality. However, consistency in selecting proper exposure factors may be an even larger problem.

Patient size and the body part being examined specifi-



**FIG. 1-2.** Expected system speed by phosphor material for single or pairs of intensifying screens and single or double emulsion films. Exposure conditions, film processing, and match of spectral sensitivity are assured. The standard is the calcium tungstate screen (par speed) and par-speed film equaling 100.

**KILOVOLTAGE vs MEASURED CENTIMETER THICKNESS**

	SCALE 2	SCALE 1	CM	1/2 SCALE	1/4 SCALE	1/8 SCALE	
	47	52	6	58	63	72	
	48	53	7	59	64	73	
	49	54	8	60	66	74	
	50	55	9	61	68	76	
<b>SCALE 4</b>	51	56	10	62	70	78	
47	52	58	11	63	72	80	
48	53	59	12	64	73	82	
49	54	60	13	66	74	84	
50	55	61	14	68	76	87	
<b>SCALE 8</b>	51	56	62	15	70	78	91
47	52	58	63	16	72	80	95
48	53	59	64	17	73	82	98
49	54	60	66	18	74	84	101
50	55	61	68	19	76	87	105
51	56	62	70	20	78	91	110
52	58	63	72	21	80	95	115
53	59	64	73	22	82	98	120
54	60	66	74	23	84	101	125
55	61	68	76	24	87	105	130
56	62	70	78	25	91	110	135
58	63	72	80	26	95	115	140
59	64	73	82	27	98	120	
60	66	74	84	28	101	125	
61	68	76	87	29	105		
62	70	78	91	30	110		
63	72	80	95	31	115		
64	73	82	98	32	120		
66	74	84	101	33	125		
68	76	87	105	34	130		
70	78	91	110	35	135		
72	80	95	115	36	140		
73	82	98	120	37			
74	84	101	125	38			
76	87	105	130	39			
78	91	110	135	40			
80	95	115	140	41			

EXTREMITY CASSETTE	
CM	kVp
1	45
2	47
3	49
4	52
5	55
6	58
7	61
8	64
9	67
10	70

EXTREMITY — Non-Bucky	TIME	mA	kVp	TFD	CASSETTE
<b>REGULAR CASSETTE</b>					
Ankle/Elbow				48"	24 x 30 cm
Tibia-Fibula				48"	14 x 17 in
Calcaneous				48"	8 x 10 in
Wrist-Carpal Tunnel				48"	8 x 10 in
Cast - Plaster				48"	
Cast - Fiberglass				48"	
<b>EXTREMITY CASSETTE</b>					
			SM MED LG		
Hand/Wrist PA/OBL				48"	24 x 30 cm
Hand/Wrist LAT				48"	8 x 10 in
Forearm				48"	7 x 17 in
Toes				48"	24 x 30 cm
Foot				48"	24 x 30 cm

**FIG. 1-3.** Kilovoltage versus centimeter thickness of the body part being examined. Charts are available in each filming station. **A** kVp chart and extremity techniques. **B** Skull, spine, and abdomen chart. **C** Pelvis, shoulder, femur, knee, chest, and ribs.

## ROUTINE RADIOGRAPHIC TECHNIQUE

EXAMINATION	TIME	mA	kVp	mAs	TFD	CASSETTE
<b>SKULL</b>						
SKULL, AP, LAT Adult					48"	24 x 30 cm
<b>CERVICAL SPINE</b>						
Cervical AP 10°↑					48"	8 x 10 in
Lateral (Cross Table)					48"	24 x 30 cm
OBL (Table Top)					48"	24 x 30 cm
Swimmer's					48"	24 x 30 cm
Odontoid					30"	8 x 10 in
Piller 30°↓					48"	24 x 30 cm
<b>THORACIC SPINE</b>						
Thoracic AP (Filter)					48"	35 x 43 cm
Thoracic LAT (Filter)					48"	35 x 43 cm
	THIN _____mA	AVERAGE _____mA		PORTLY _____mA		
Thoracic Lower LAT (No Filter)					48"	24 x 30 cm
<b>LUMBAR SPINE/ABDOMEN</b>						
Lumbar AP 5°↑ and Abdomen						
- 18 cm					48"	35 x 43 cm
19 - 23 cm					48"	35 x 43 cm
24 cm -					48"	35 x 43 cm
Lumbar OBL 42° 5°↑						
- 18 cm					48"	24 x 30 cm
19 - 23 cm					48"	24 x 30 cm
24 cm -					48"	24 x 30 cm
Lumbar LAT Meas L-2					48"	30 x 35 cm
Lumbar Loc LAT Meas L-5					48"	8 x 10 in
Lumbar Graft LAT					48"	24 x 30 cm
Lumbar Flexion & Extension					48"	30 x 35 cm

B

FIG. 1-3. (Continued.)

cally affect exposure factors (kVp and mA-s) required for optimal radiographs. We prefer to use a system that can be applied throughout the department and provide uniform quality. Measuring the body part to be examined and referring to standardized charts (Fig. 1-3) available in each examining station results in more uniform quality. The charts remove the guesswork in deciding which exposure factors should be used.

In addition to using the proper exposure factors, certain basic principles of physics must be applied. The focal spot should be as small as practical in order to reduce

geometric unsharpness, or blurring. The central portion of the beam should be as perpendicular to the cassette as possible in order to minimize distortion of the object being radiographed. This also assures that adjacent structures will be recorded in their true spatial relationships (Fig. 1-4). The body part to be examined should be placed parallel to the film to minimize magnification, blurring, and distortion. The body part should be placed as close as possible to the cassette.

Motion of either the equipment or the body part during the examination results in blurring of the image.



Date:

EXAMINATION	TIME	mA	kVp	mAs	TFD	CASSETTE
<b>PELVIC REGION</b>						
Pelvis & Hips AP / OBL 5°↓					48"	35 x 43 cm
Hips LAT					48"	24 x 30 cm
Sacrum AP 5°↑					48"	24 x 30 cm
Coccyx AP 10°↓					48"	24 x 30 cm
Sacrum, Coccyx LAT					48"	24 x 30 cm
S-I Joints (R & LPO 20°)					48"	24 x 30 cm
<b>SHOULDER</b>						
Shoulder AP					48"	24 x 30 cm
Neer View					48"	24 x 30 cm
Transthoracic Lateral					48"	35 x 43 cm
Axillary (Grid)					48"	24 x 30 cm
Scapula AP & LAT OBL					48"	24 x 30 cm
Clavical					48"	24 x 30 cm
Humerus					48"	35 x 43 cm
<b>FEMUR, KNEE</b>						
Femur					48"	35 x 43 cm
LAT & OBL for Vessels					48"	35 x 43 cm
Knee					48"	24 x 30 cm
Intercondylar Notch					48"	Non-Bucky
Patella (Merchants)					48"	Non-Bucky
<b>CHEST</b>						
AP Supine, All					48"	Non-Bucky
Bucky Chest						
Lateral Supine (Bucky)					48"	35 x 43 cm
Lateral Decubitus (Grid)					48"	35 x 43 cm
Lateral Sternum					48"	30 x 35 cm
<b>RIBS</b>						
Ribs Above Diaphragm					48"	24 x 30 cm
	THIN _____mA	AVERAGE _____mA	PORTLY _____mA			
<b>Ribs Below Diaphragm</b>						
- 18 cm					48"	24 x 30 cm
19 - 23 cm					48"	24 x 30 cm
24 cm -					48"	24 x 30 cm

C

FIG. 1-3. (Continued.)