

TRANSACTIONS
OF THE
AMERICAN PHILOSOPHICAL SOCIETY

HELD AT PHILADELPHIA


FOR PROMOTING USEFUL KNOWLEDGE

NEW SERIES—VOLUME XXVII

ANATOMY OF THE RAT

EUNICE CHACE GREENE.

PHILADELPHIA
THE AMERICAN PHILOSOPHICAL SOCIETY
104 SOUTH FIFTH STREET



HAFNER PUBLISHING CO., NEW YORK

1955

COPYRIGHT 1935
AMERICAN PHILOSOPHICAL SOCIETY
PHILADELPHIA

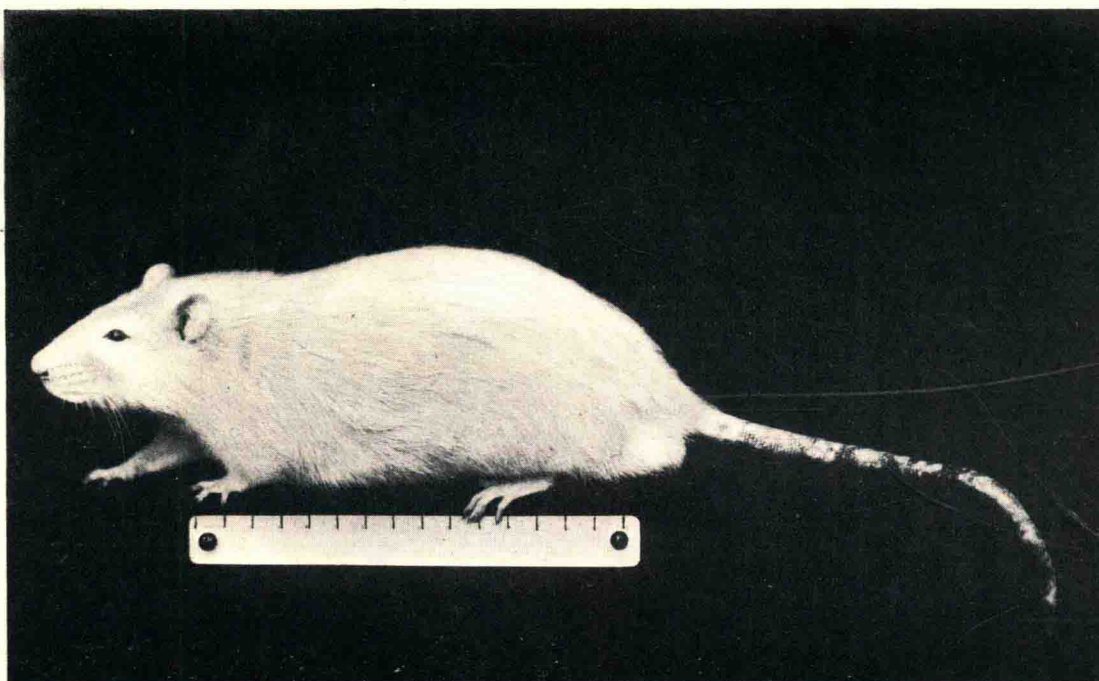REPRINTED BY PERMISSION
1955
HAFNER PUBLISHING CO. INC.
31 EAST 10TH STREET
NEW YORK 3, N. Y.

PRINTED IN THE UNITED STATES OF AMERICA

NOBLE OFFSET PRINTERS INC.
NEW YORK 3, N. Y.

ANATOMY OF THE RAT

EUNICE CHACE GREENE



Mus norvegicus albinus.

Extracted Albino Rat (Seventh generation inbred)

Dr. King's Colony of the Wistar Institute.

Male. Age 521 days. Weight 551 grams.

Reduced approximately $\frac{2}{3}$. Scale in Cm.

FOREWORD

This book is both an essay in Comparative Anatomy and also a guide to the dissection of the Albino rat.

During the past 40 years the use of the Albino or of the Pied rat for laboratory purposes has steadily increased and experiments involving operations have become more and more numerous.

The need for an anatomy of this animal is thus indicated. The present study was begun more than a decade ago. Despite handicaps it has been persistently pursued and so brought to its present form. It represents the most complete anatomical presentation of any of our laboratory animals and further is unique in that both the figures and the text are the work of the author, an unusual combination.

It is hoped that it will prove of value not only as an introduction to the Comparative Anatomy of the mammal but also in those operative studies in which the rat is used as the test animal.

HENRY H. DONALDSON

PREFACE

At the present time there is no general treatise on the normal anatomy of the rat with the exception of Martin and Moale's "Vertebrate Dissection, Part III, How to Dissect a Rodent" (1884), and Hunt's "Laboratory Manual of the Anatomy of the Rat" (1924). The former is, of course, too elementary to be considered adequate, and the latter is designed solely for student use. A third book, Howell's "Anatomy of the Wood Rat" (1926), while serving as a valuable reference is obviously not directly applicable to the albino rat, and furthermore, treats the subject mainly from the point of view of muscle function, omitting entirely the circulatory, nervous, and endocrine systems. All three books differ radically in aim and scope from the present work, which is designed in no sense as a text book, but as a reference book or atlas for research workers, instructors and advanced students in Comparative Anatomy. It is hoped that it may prove of value either for the dissection of a mammal, for operative work, or for pathological studies. For ordinary laboratory use the superficial dissections will be found sufficient.

With these ends in view, and presupposing a general knowledge of mammalian anatomy on the part of the reader, the author has attempted to show the most important gross anatomical structures by numerous drawings and to avoid lengthy descriptions wherever possible. Structures not visible to the naked eye have been omitted as not coming within the scope of the present work. It will be readily understood, however, that for purposes of careful dissection, especially of the nervous and circulatory systems in so small an animal, some slight magnification was highly desirable. The lowest power obtainable with the binocular dissecting microscope was therefore freely used in making the preparations.

The author has been impressed throughout the work by the close structural similarity of the rat to man and by the fact that only the texts on human anatomy were useful when it came to the identification of details of structure. In many cases relationships which occur as variations in man are found to be the usual condition in the rat. This is undoubtedly due in large measure to the difference in posture. In a few of the cases where such relationships occur, they have been described in more detail. In fact man has been made the basis of comparison throughout. The author is however fully cognizant of the fact that the standard works on human anatomy are based upon large numbers of individuals and that many more rats must be examined before it can be stated finally what is the usual condition and what are the variations. For the present purpose it was deemed sufficient to make some preliminary dissections, then to select not less than ten animals, usually more males than females, and make a thorough dissection of each. This was done for each system and the drawings show the conditions found in the majority of these specimens. Care must be taken, therefore,

not to jump to the conclusion that variations from the condition described, or shown, are necessarily anomalies. In general the variations are few and, when they occur, slight.

Treatment of the subject from the standpoint of regional anatomy was considered, but this method of approach is only satisfactory when an anatomical text book is available for reference. It has therefore seemed more appropriate to follow a systematic arrangement, and thus to make the information more easily accessible for other investigators. In view of this the arrangement of chapters follows the order commonly found in the standard text books of human anatomy. Within the chapters the figures follow the pages of description and are arranged, as far as possible, in the order of head, trunk, limbs, and from superficial to deep.

In the index, where reference to several figures is given, the more important ones are shown in heavy type.

The bibliography includes not only anatomical references dealing directly with the rat, but also those dealing in a more general way with comparative anatomy, together with the familiar texts of human anatomy which have served as a constant source of reference in the present study.

The B. N. A. has been used as far as possible. Following Emmel's 1927 edition of this nomenclature, some terms have been anglicized in accordance with the "majority of the standard English and American anatomical texts." In many instances terms taken from comparative anatomy or from the older nomenclature are given in parentheses following the B. N. A. terms.

For a few drawings where size seemed important, for example in the skeletal system and for some of the endocrines, the camera lucida was used. The majority of drawings are freehand and may be considered semi-diagrammatic inasmuch as there is doubtless some slight distortion where parts are drawn aside to show relationships more completely. For permission to use the diagram of the lymph channels, I wish to thank Dr. Thesle T. Job of Loyola University.

As far as practicable, labels have been placed on each figure but where these are too numerous and were in danger of obscuring the details they have been removed to one side or to adjacent key figures.

The specimens used were all albino norway rats (*Mus norvegicus albinus*) from the rat colony of the Wistar Institute. Some of the specimens used for the study of the circulatory system were injected by Dr. F. D. Lambert, of the Botany Department of Tufts College. The rest of the material used for this purpose was injected by Dr. I. E. Gray at the Supply Department of the Marine Biological Laboratory, Woods Hole, Massachusetts.

The majority of the material was preserved in formalin. It was found desirable to tie the animal in an extended position on coarse wire netting before immersing in formalin to prevent the contraction of the ventral and limb muscles during the hardening process, thus greatly facilitating the dissection.

For the studies of the vascular system either a starch or gelatin injection mass

such as is commonly used in most laboratories, was employed. The animals were injected through the heart or the femoral vessels.

In a smaller group of animals a different method was used. The animals were injected through the femoral artery with embalming fluid followed by a non-bleeding arterial injection mass, Murphy's artery-red lacquer. For such a small animal this was diluted slightly with the usual lacquer thinner. The specimens were then stored in a tank and covered with cloths soaked in 2% carbolic. This gives a flexible specimen which makes for greater ease in dissection but is, in the author's opinion, not so satisfactory for visceral studies as the formalin method which leaves the viscera in a firmer condition.

This work was begun at the suggestion of Dr. Harris H. Wilder of Smith College, by whose death the author lost a most valued friend and teacher. The chapters on muscles and skeleton were done under his direction. These chapters were then submitted to Dr. M. J. Greenman, Director of the Wistar Institute, and at his suggestion it was decided to complete this study with the idea of publishing an anatomical atlas of the albino rat. The remainder of the work was carried on under the guidance of Dr. Henry H. Donaldson to whom more than to anyone else I am deeply indebted for his continued support of the work and for his constant encouragement and advice. To Dr. Greenman and Dr. Donaldson I wish to express my appreciation of their generosity in supplying material from the colony of the Institute, and in extending laboratory privileges at the Institute and at Woods Hole.

I am also under obligation to Dr. Harold D. Senior for invaluable suggestions and criticisms with regard to the circulatory system.

Further acknowledgment is also due Dr. Wayne J. Atwell of the School of Medicine of Buffalo University, and Dr. Henry W. Stiles of the College of Medicine, Syracuse University, for the use of laboratory facilities.

To my husband, Walter F. Greene, without whose generous and unfailing interest this work would never have reached completion, I am especially grateful.

Finally I wish to acknowledge with gratitude the publication of the present work by the American Philosophical Society.

These conditions have made it possible to produce an anatomy of the rat which is more complete than that available for any other of the lower mammals, and the results should have a value not only for the anatomist, but also for an interpretation of the evolutionary development of the mammalian series.

Syracuse

EUNICE CHACE GREENE

1935

CONTENTS

	PAGE
FOREWORD	vii
PREFACE	ix
CHAPTER I. GENERAL APPEARANCE	1
<i>Figs. 1-5</i>	
CHAPTER II. SKELETON	5
<i>Figs. 6-50</i>	
CHAPTER III. MUSCLES	31
<i>Figs. 51-102</i>	
CHAPTER IV. VISCERA	85
<i>Figs. 103-123</i>	
CHAPTER V. ENDOCRINES	109
<i>Figs. 124-137</i>	
CHAPTER VI. NERVOUS SYSTEM	115
<i>Figs. 138-196</i>	
CHAPTER VII. CIRCULATORY SYSTEM	177
(a) Lymphatics	
<i>Figs. 197-339</i>	
BIBLIOGRAPHY	337
INDEX	343

CHAPTER I

GENERAL APPEARANCE

(Figs. 1-5)

Mus norvegicus albinus (Frontispiece) is an albino mutant from the wild gray form (*Mus norvegicus*) which is represented in the laboratory of the Wistar Institute by several color varieties of which the albino is most common. The albino race differs from the gray race in the relative development of some of the viscera (Donaldson '24). The albino has a span of life of about three years, and is nearly completely grown at six to eight months of age, when the male may weigh 250 grams and the female somewhat less. When fully mature the albino rat weighs from 200-400 grams.

The description which follows applies to the more conspicuous features of the external appearance, as they appear in the mature animal.

The albino is characterized by small and thick ears and the length of the tail is about 85% of the length of the body, being relatively a little longer in the female than in the male. The fact that the tail is somewhat shorter than the body serves to distinguish this species from the house rat (*Mus rattus*) in which the tail is distinctly longer than the body.

Fraser ('31) who has made a careful histological study of the hair pattern states, "On each surface there are two conspicuous lengths of hair, the longer being the more sparse. The hairs are arranged in two classes of groupings, that with and that without a long hair, which is usually quite centrally located. According to their location within a group, follicles may be divided into three kinds. They may be central; adjacent, grouped with a central; or associated, grouped without a central follicle. Follicles other than the central are mostly of composite nature, that is, there is more than one hair to a follicle. The central follicle is only occasionally composite."

Butcher ('34) who has worked out the hair cycles in the rat, confirms Fraser's account and goes on to state that, "hair growth in the young albino rat is cyclic. These cycles occur approximately every 35 days, the resting period and the growing stage each being about 17 days in length. The elongated follicles of the growth period in the first cycle in the dorsum last from birth until the sixteenth or seventeenth day of life. Quiescence during which the follicles are inactive and short, then continues until the thirty-second to thirty-fourth day when active growth and lengthening begin again. It is remarkable that practically all the follicles are in the same stage at the same time and that the resting condition is established within a very short interval."

"The hair cycles in the prepubertal rat parallel the growth activity in the ovary. The gonad, however, is not responsible for this hair growth, since the hair cycles occur in ovariectomized animals as in normal rats."

"In the rat new hairs in their growth do not normally push out the old hairs.

Of course, this results in an additional hair in the follicle with each new growth. Finally, a follicle with several hairs, a composite follicle is established. Composite follicles are not present in the first coat."

It is further shown that "the growth and quiescent stages in the venter are quite similar to those in the dorsum, with the exception that the comparable condition in the venter is 4 or 5 days in advance of the similar stage in the dorsum. In other words growth begins first in the venter and spreads dorsally. Likewise, quiescence in the venter would be observed 4 or 5 days before there was any evidence of it in the dorsum."

In certain regions the bristles are developed as long vibrissae (Fig. 1). In the rodents these are arranged in four groups, and in accordance with Pocock's terminology (1914), may be described as follows. The *buccal* vibrissae are those around the muzzle. These are divided into two groups, the *mystacial* and *submental*. The mystacial in the rat grow in five or six parallel rows, running from the nose backward along the upper lip. The number in a row varies from five to ten. Some of this group are longer than the whole head of the animal. The skin in this region is very thick to accommodate the exceptionally large hair follicles, and forms what is known as the vibrissae or mystacial pad. Inasmuch as the vibrissae serve as tactile organs they are richly supplied with nerves, branches of the maxillary division of the trigeminal. The *submental* group of vibrissae, on the chin, is composed of two rather definite rows and a few smaller more scattered vibrissae. In addition to these there are usually three just above the eye, the *superciliary*, while the *genal* group is doubled and represented by a single bristle a little below the outer corner of the eye, and two more near the corner of the mouth. The *interramal* group consists of an unpaired tuft of three or four vibrissae in the midline between the rami of the mandibles.

The eyelids are well developed, and except for the nictitating membrane (supported by a semilunar cartilage) in the medial corner of the eye, only the cornea is visible. The eyelashes are very fine and short, while the tarsal, or Meibomian glands, are large and readily seen. By rather frequent winking, the eye is kept moist with secretions from the lacrimal and Harderian glands.

The nares, which are shaped like a reversed comma, open laterally and may be closed under water. Unlike the rat, most Murine and Sciurine rodents have the nostrils separated by a vertical groove. In this animal, however, the vertical groove begins just below the nares and forms a cleft in the upper lip, exposing the superior incisors, even when the mouth is closed. Back of the incisors the hairy lip extends inward toward the midline, and the opposite halves practically meet, thus excluding the upper incisors from the mouth cavity proper.

Both fore and hind feet are pentadactyle (Figs. 2, 3, 4, 5). The "thumb" or pollex (Fig. 4) is much reduced in the forefoot. Nevertheless it must be considered a distinct digit since it has a fully developed nail which is peculiarly flattened unlike the nails of the other digits. Furthermore it has two perfectly distinct phalanges as shown in serial sections through the paw. Typical walking pads are evident (Fig. 4), five apical pads on the tips of the digits, three interdigital pads on the palm (the first interdigital seems to have disappeared with the reduction of the pollex), and two at the

base of the palm, the hypothenar pad on the ulnar side and the thenar pad on the radial side. The hind foot (Figs. 3, 5) has its full quota, five apical, and four interdigital pads, with two more, one medial and one lateral, in the region of the metatarsals.

The palms and soles are devoid of hair but the backs of the paws are sparsely covered with short thin hair.

The tail, which is actively used as a balancing organ, relative to the body length is shorter than in *Mus rattus*. Scales overlapping like shingles cover the tail, while the hairs are reduced to three rather short bristles emerging from under the edge of each scale.

In the female the teats of *Mus norvegicus* are usually twelve in number, three pairs in the pectoral and three pairs in the abdominal region (Fig. 109). Just anterior to the anus is the vagina which is closed by a plug until the time of puberty, which occurs on the average between 70 and 90 days. Anterior to the vagina is the orifice of the urethra at the base of the clitoris which is enclosed in a small prepuce (Fig. 109).

In the male the testes descend between the 30th and 40th day into the thin-walled scrotal sacs. Externally the sacs are not distinctly separated, but beneath the skin the division is complete. On the tip of the scrotal sacs the hair is sparse and fine. The penis is enclosed in a loose sheath, the prepuce, and upon being extruded is found to have a single cartilaginous or bony process, the *os penis* (Figs. 92, 280), on its ventral wall.

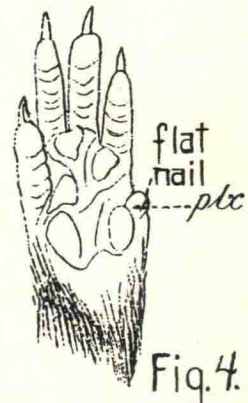
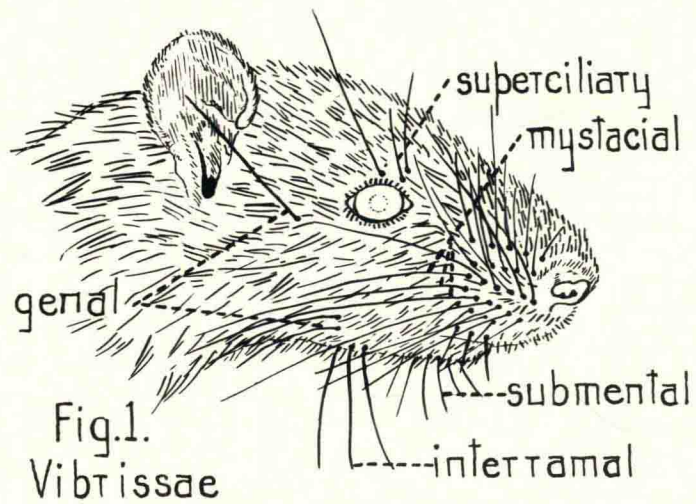
LIST OF FIGURES

Frontispiece—*Mus Norvegicus Albinus*

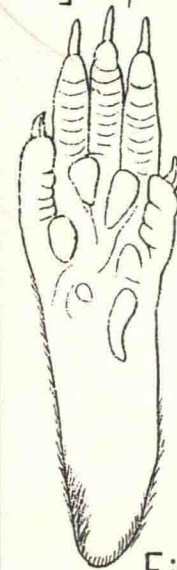I. GENERAL APPEARANCE

Fig.

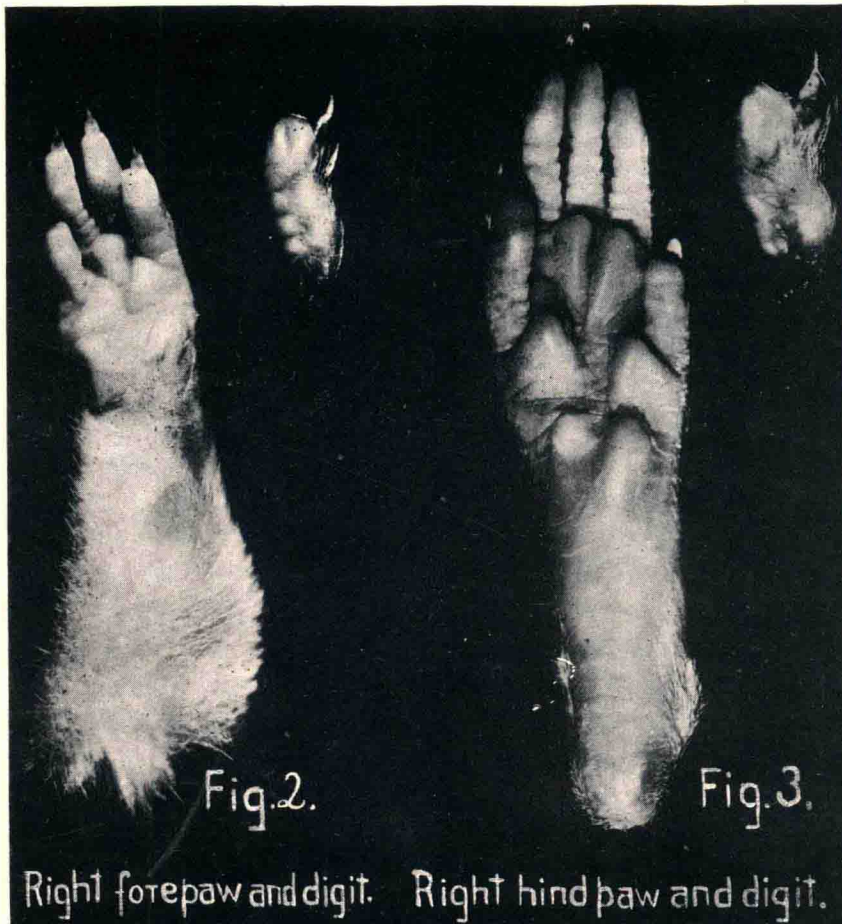
1. Vibrissae
2. Right Forepaw and Digit
3. Right Hindpaw and Digit
4. Drawing of Right Forepaw
5. Drawing of Right Hindpaw



Drawing of
Right forepaw



Drawing of
Right Hindpaw.



CHAPTER II

SKELETON

(Figs. 6-50)

The following order has been followed:

Axial skeleton

Skull

Vertebral column

Thorax

Appendicular skeleton

Anterior appendage

Posterior appendage

Descriptions and figures are based on adult but not senile specimens. In senile material some fusion occurs as in man, although in the long bones there is scarcely a time when the line of diaphysis and epiphysis is not visible.

An attempt has been made to show as many of the essential features as possible by drawings without resorting to lengthy descriptions. A few points will, however, need further elucidation, especially where the structure or arrangement differs markedly from human anatomy.

In all figures, names of bones are capitalized to distinguish them from names of features.

AXIAL SKELETON

SKULL

(Figs. 7-20)

TABLE OF COMPARISON OF THE BONES OF THE RAT AND HUMAN SKULL

<i>Rat</i>	<i>Human</i>
2 Nasals (Figs. 7-10)	2 Nasals
2 Premaxillaries (Figs. 9-12)	
2 Maxillaries (Figs. 7-12)	2 Maxillaries
2 Zygomatics (Figs. 7-12)	
2 Palatines (Figs. 11-12)	2 Palatines
1 Vomer (Fig. 14)	1 Vomer
2 Lacrimals (Figs. 7-10)	2 Lacrimals
1 Ethmoid (Figs. 13-18)	1 Ethmoid
2 Frontals (Figs. 7-10)	1 Frontal
1 Basisphenoid (Figs. 9-12)	

ANATOMY OF THE RAT

<i>Rat</i>	<i>Human</i>
1 Presphenoid (Figs. 9-12)	1 Sphenoid
2 Parietals (Figs. 7-10)	2 Parietals
1 Occipital (Figs. 7-12)	1 Occipital
1 Interparietal (Figs. 7-10)	
2 Squamosals (Figs. 7-12)	
2 Periotic capsules (Figs. 9, 10, 12)	2 Temporals
2 Tympanic bulla (Figs. 9-12)	
6 Auditory ossicles (Fig. 154)	6 Auditory ossicles
2 Malleus	2 Malleus
2 Incus	2 Incus
2 Stapes	2 Stapes
4 Turbinates (Fig. 15)	2 Turbinates
2 Naso-turbinals	
2 Maxillo-turbinals	
1 Hyoid (Fig. 21)	1 Hyoid
2 Mandibles (Figs. 19, 20)	1 Mandible

The *craniopharyngeal canal* (Figs. 11-13) pierces the basisphenoid bone. According to Donaldson, "the canal is patent, in the albinos, in from 3 to 5 percent of the cases. In addition, the foramina can be located in another 3 to 5 percent, and these might be considered patent if you could get bristles slender enough, and at the same time strong enough, to be pushed through the canal. There are all gradations from this to complete disappearance of foramina, both endo-cranially and on the outside."

VERTEBRAL COLUMN

(Figs. 6, 22-27)

The vertebral column consists of seven cervical, thirteen thoracic, six lumbar, four sacral, and from twenty-seven to thirty caudal vertebrae. Since a typical vertebra of each region has been shown, a few features only, deserve mention here. The spinous process of the second thoracic vertebra is longer than that of any other vertebra and is further extended by a small triangular piece, which articulates with it.

The *sixth* cervical vertebra displays a marked peculiarity. Extending ventrally and slanting caudally from the transverse process is a thin plate of bone, quite thin medio-laterally but in its antero-posterior dimension almost as broad as the centrum and with its ventral edge somewhat thickened. It lies directly ventral to the vertebrarterial foramen. This *carotid* or *Chassaignac's tubercle* is apparently an enlarged costal element and would seem to correspond to the anterior tubercle of the transverse process in man. No hint of such a process appears in either of the adjacent vertebrae. Howell (1926), calls this an inferior lamella and states that, "the longus colli muscle extends both ways from this process and may be chiefly responsible for the variation which it exhibits, but the latter is believed to be phylogenetic as well."

In the *seventh cervical* vertebra a vertebrarterial foramen may be small or lacking.

The *sacro-iliac joint* is made by the first two sacral vertebrae with the auricular surface of the ilium.

Chevron bones are present as far caudad as the fifth or sixth vertebra from the tip of the tail (Fig. 6).

THORAX

Numerous bony elements make up the thoracic basket (Figs. 31, 32). It is conical in shape, smaller at the anterior end, and larger posteriorly. In cross section it is practically circular. Dorsally it is composed of the thirteen thoracic vertebrae and the dorsal extremities of the ribs, while the dorsal segments of the ribs form the lateral walls, and the ventral segments, with the sternum, constitute the ventral elements.

Beginning with the sixth thoracic vertebra there is apparently a slight differentiation of the transverse process into (1) tubercular articular process for the rib articulation, and (2) a more dorsally located process, a metapophysis, which in the vertebrae of the posterior region of the thorax becomes more and more closely associated with the anterior surface, until, in the last three thoracic vertebrae, this process and the anterior articular process are indistinguishable.

The dorsal segments of the ribs are, in the case of the rat, completely ossified, while the ventral elements are calcified, thus the animal has no true costal cartilages.

APPENDICULAR SKELETON

ANTERIOR APPENDICULAR SKELETON

(Figs. 28-30, 33-40)

The clavicle and associated elements (Figs. 29, 30). Attaching the lateral end of the clavicle to the acromion process of the scapula is a thin disc of cartilage, usually considered the distal portion of the primitive procoracoid, and called by Parker the mesoscapular segment. At the medial end is a disc of cartilage which is also a vestige of the procoracoid cartilage. There thus extends between the sternum and the scapula a chain of skeletal elements: omosternum, proximal procoracoid piece, clavicle, distal procoracoid piece (mesoscapular segment of Parker). Of these the clavicle and omosternum are ossified in the rat, the others remaining cartilaginous. At this point I wish to acknowledge information received from Dr. Alden B. Dawson based on his histological studies, verifying the above statement. Dawson finds that, "the omosternum begins to ossify at three months and at the end of the fourth month, ossification has proceeded to considerable extent."

The *humerus*, *ulna*, and *radius* (Figs. 33-38), present no marked peculiarities or variations from the general mammalian type.

The *carpus* (Figs. 39, 40). A series of nine rather nodular bones, with more or less irregular surfaces and flattened articular areas, forms the carpus. Some fusion has taken place and certain modifications from the more generalized primitive condition have occurred. The following table will serve as a comparison of the carpal bones of the rat with the more generalized form of primitive vertebrates and with that of man.