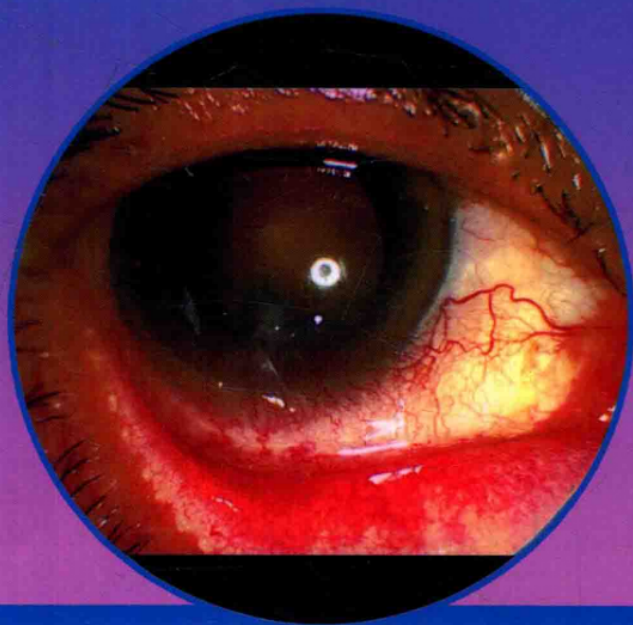


王开文  
编著



# 眼红斑痤疮

O C U L A R     R O S A C E A

上海科学技术出版社  
Shanghai Scientific & Technical Publishers

# 眼 红 斑 痤 疮

OCULAR ROSACEA

王开文 编著

上海科学技术出版社

---

图书在版编目(CIP)数据

眼红斑痤疮 / 王开文编著. —上海: 上海科学技术出版社, 2016. 8

ISBN 978 - 7 - 5478 - 3116 - 8

I. ①眼… II. ①王… III. ①眼睑疾病—皮肤病  
IV. ①R777. 1

中国版本图书馆 CIP 数据核字(2016)第 144176 号

---

眼红斑痤疮

王开文 编著

上海世纪出版股份有限公司 出版  
上海科学技术出版社

(上海钦州南路 71 号 邮政编码 200235)

上海世纪出版股份有限公司发行中心发行

200001 上海福建中路 193 号 www. ewen. co

上海中华商务联合印刷有限公司印刷

开本 787×1092 1/16 印张 11

字数 140 千字

2016 年 8 月第 1 版 2016 年 8 月第 1 次印刷

ISBN 978 - 7 - 5478 - 3116 - 8/R · 1149

定价: 148.00 元

---

本书如有缺页、错装或损坏等严重质量问题, 请向工厂联系调换

## 内容提要

本书是首部专门论述眼红斑痤疮的专著,对该病从基础医学到临床实践进行了全面系统地阐述。全书共 11 章,前两章阐述本病的流行病学、预防和病因学,以及皮肤和眼红斑痤疮的病理生理、临床表现等。第三章论述眼病的中医辨证论治。第四章到第十章分别论述睑皮炎及睑腺疾病,睑板腺功能障碍,干眼,结膜、角膜、巩膜乃至眼内组织损害。第十一章介绍了至今了解甚少的儿科眼红斑痤疮。书中列举了临床实例进一步证实眼红斑痤疮疾病的多发性,指出确诊的依据。本书是眼科医生从事医疗、教学、研究工作的必备用书,亦可供皮肤科、病理科、儿科以及中西医结合方面的医生参考,还可作为家庭、个人养生保健用书。

书中内容大部分为作者临床研究经验总结,多为国内首次发表和报道;部分为国际首次发现和确定,如结膜下出血、炎性及非炎性血管增生和纽结、并发性白内障以及泪腺封闭疗法等。

## Author Biography

Dr. Wang was the Dean of the Ophthalmology Department at the Medical School of Shihezi, Xinjiang, China and served as president of the Affiliate Hospital of the Medical School of Shihezi. He graduated from China Medical University in 1952.

His career as a clinical doctor, professor, and research scientist in the field of ophthalmology spans more than 60 years. He pioneered the clinical research in ocular rosacea and published a series of papers on the disease in China. Dr. Wang was honored as Expert who receives special government allowances of the State Council of China for life time in 1992.

## 前 言

20 世纪 90 年代笔者在大学附属医院接诊了一位老年患者,他年轻时即在酒厂工作,每日品尝鉴定白酒质量。接诊时已双目失明,双眼粘连性角膜白斑,邻近的巩膜变薄,鼻面部皮肤有许多新生血管。还有一位 60 岁男性患者,10 年来左眼每年发病,角膜溃疡已穿孔,视力只有光感。在省城 4 所医院按细菌、病毒感染治疗,一直未愈,备受折磨,感到无望。经检查,发现其面部皮肤普遍有毛细血管扩张和增生,脸呈枣红色。按眼红斑痤疮治疗不久,角膜溃疡愈合。面对如此严重的眼病,笔者感触颇深,便开始重视此病的研究。

红斑痤疮是一种病因并非十分清楚的常见炎症性皮肤病。作为红斑痤疮四种主要临床亚型之一的眼红斑痤疮,其发病率占红斑痤疮患者的 3%~58%。眼科医生接诊时往往忽视对患者面部的检查,易造成漏诊、误诊。国外虽出版过皮肤科红斑痤疮专著,但尚无眼红斑痤疮专著问世,国内眼科教科书中亦无有关本病的论述。有鉴于此,笔者感到有责任根据自己多年对此病的临床研究结果编撰一本专著。本书除了介绍本病国内外临床及基础医学研究的最新进展外,还阐述了笔者的临床研究新发现,譬如血管异常包括炎性和非炎性血管扩张、增生,在结膜、角膜,尤其是在球结膜特别触目。这些扭曲的血管形成攀状、团块或结节,可发生渗漏和出血,是诊断眼红斑痤疮的主要体征之一。同时书中也以一定篇幅描述了笔者用中医药治疗本病的方法,譬如对难治的眼红斑痤疮睑缘结角膜炎,用口服中药治疗取得了满意效果。

眼红斑痤疮虽为常见眼疾,但对其临床医学及基础医学关注度有待提高。编撰本书的另一目的是抛砖引玉,吸引更多临床医生及基础医学研究者

参与此病的研究。期望在不太长的时间内深化病因学研究,积累丰富的临床经验和资料。那时,该病发病机制将被进一步阐明,被漏诊、误诊的患者亦会减少。累足成步,磨杵成针,相信辛勤耕耘会获得丰硕成果。

笔者尝试撰写这部关于眼红斑痤疮的专集,因无范本可循,编撰有一定难度,为适应具体疾病的不同特点和背景,书中相应章节的编排格式略有不同。

本书编写过程中,得到了上海科学技术出版社的大力支持。因本书为首次出版,难免挂一漏万,亟望眼科及医学同仁不吝赐教,予以斧正。

王开文

2016年4月



## Preface

In the early 1990s, I treated an aged male patient at the university-affiliated hospital where I practiced. Both of his eyes were blind with adherent leukoma of the cornea and thinning near the sclera. His facial and nasal skin presented many more neovessels than normal. He worked at a wine factory from a young age, tasting and evaluating wine properties every day. Another male patient, aged sixty, suffered from attacks on his left eye every year during the prior ten years by a perforated corneal ulcer, reducing his vision to just light perception. He was treated based on bacterium and viral infection at four hospitals in the metropolis of province and still was not cured. He was left feeling troubled and hopeless. Upon examination, diffuse telangiectasia with proliferation was found on his face, presenting with a purplish red color. In accordance with treatment for ocular rosacea, the corneal ulcer was soon cured. In the face of such a serious ocular disorder, I felt strongly that an ocular rosacea investigation was necessary.

Rosacea is a common inflammatory skin disease, but its etiology is not very clear. Ocular rosacea is one of the four subtypes of rosacea and neither clinical nor research medicine have given it much attention in China. Oculists often neglect to examine the patient's skin, thus leading to missed diagnoses or misdiagnoses. Dermatologic texts on rosacea have been published, while ocular rosacea monographs have not appeared. One purpose for writing this book is to give clinicians and researchers more information so that they can make more accurate diagnoses. The other



purpose is to encourage more research and study into the disease. The hope is that in the near future more scientists and ophthalmologists will have more data to determine the cause of this disease and better treat patients who suffer from it.

This book not only presents research that has been published, but new findings resulting from my own clinical investigations were elucidated as well. Vascular anomaly including its dilatation and proliferation in conjunctiva and cornea, especially in the bulbar conjunctiva, is very striking. These tortuous vessels may form a loop, mass or lacey with leakage as well as hemorrhage. These are among the primary indicators for the diagnosis of ocular rosacea.

Treating for ocular diseases with internal therapy of Traditional Chinese Medicine (TCM) is a complementary alternative medicine approach. For intractable blepharo-keratoconjunctivitis, satisfactory efficacies were attained with oral Chinese medicine. For those recurrent diseases, tetracyclines are not exclusively adopted, applying TCM therapy will reduce their side effects and increase the therapeutic efficacies.

I want to acknowledge the support of Shanghai Scientific & Technical Publishers during the process of publishing this book. Although I have done my best to present a complete text based on my accumulated knowledge, I welcome comments or corrections from my colleagues in the clinical and research community.

Kaiwen Wang  
Foshan, China  
April, 2016

# 目 录

<b>第 1 章 红斑痤疮流行病学、预防及病因学</b> <b>Epidemiology, Prophylaxis and Etiology of Rosacea</b>	<b>001</b>
1 红斑痤疮的流行病学(Epidemiology of Rosacea)	001
2 红斑痤疮的预防(Prophylaxis of Rosacea)	002
3 红斑痤疮的病因学(Etiology of Rosacea)	004
3.1 蠕形螨的寄生( <i>Demodex</i> Infestation)	004
3.2 蠕形螨作为细菌的载体( <i>Demodex</i> as a Vector for Other Bacteria)	006
3.3 细菌的致病作用(Bacterial Pathogenicity)	008
3.4 血管异常(Vascular Abnormality)	009
<b>第 2 章 皮肤红斑痤疮及眼红斑痤疮</b> <b>Cutaneous and Ocular Rosacea</b>	<b>014</b>
1 皮肤红斑痤疮(Cutaneous Rosacea)	014
1.1 皮肤红斑痤疮的临床表现(Clinical Manifestations of Cutaneous Rosacea)	014
1.2 皮肤红斑痤疮的病理生理(Pathophysiology of Cutaneous Rosacea)	016
2 眼红斑痤疮(Ocular Rosacea)	018
2.1 皮肤红斑痤疮与眼红斑痤疮的关系(Relationship of Cutaneous and Ocular Rosacea)	018
2.2 眼红斑痤疮的临床表现和诊断(Clinical Manifestations and Diagnosis of Ocular Rosacea)	019

2.3	眼红斑痤疮的组织病理(Histopathology of Ocular Rosacea)	023
2.4	眼红斑痤疮的免疫病理(Immunopathology of Ocular Rosacea)	026
2.5	眼红斑痤疮的分子病理(Molecular Pathology of Ocular Rosacea)	028

第3章 眼病中医辨证论治

Treatment Based on Syndrome Differentiation in Ocular Diseases with TCM

032

1	眼病辨证论治(Treatment Based on Syndrome Differentiation in Ocular Diseases)	032
1.1	眼病的辨证论治与诊断(Treatment Based on Syndrome Differentiation and Diagnosis in Ocular Diseases)	032
1.2	眼病的局部辨证与全身辨证(Differentiation of Local Syndrome and General Syndrome in Ocular Diseases)	034
1.3	眼病治疗的标、本、缓、急与舍局部证从全身证或舍全身证从局部证(The Cause and the Symptom, the Chronic Case and the Acute Condition of Treatment in Ocular Disease, Precedence of General Syndrome over Local Syndrome or Precedence of General Local Syndrome over Common Syndrome)	036
1.4	异病同治,同病异治,同证异治与异证同治(Treating Different Diseases with the Same Therapy, Treating the Same Disease with Different Therapies, and Treating the Same Syndrome with Different Therapies, Treating Different Syndromes with the Same Therapy)	037
1.5	中医内治疗法治愈眼红斑痤疮例证(Illustrative Case of Curing Ocular Rosacea with Internal Treatment of TCM)	037
2	眼病中医内治疗法(Internal Treatments for Ocular Diseases with TCM)	038
2.1	祛风清热法(Method of Dispelling Pathogenic Wind and Clearing up Pathogenic Heat)	038

2.2	祛风散寒法(Method of Dissipating Pathogenic Wind and Cold)	039
2.3	清热解毒法(Method of Clearing Heat and Removing Toxicity)	039
2.4	清热降火法(Clearing Heat and Lowering Fire)	039
2.5	泻下降火法(Method of Relaxing Bowels and Lowering Fire)	039
2.6	滋阴降火法(Method of Nourishing Yin and Lowering Fire)	040
2.7	祛湿法(Method of Eliminating Dampness)	040
2.8	化痰法(Method of Resolving Phlegm)	040
2.9	止血法(Method of Blood-Stanching)	041
2.10	活血化瘀法(Method of Promoting Blood Circulation and Removing Blood Stasis)	041
2.11	疏肝理气法(Method of Dispersing Depressed Liver-Qi)	042
2.12	平肝潜阳法(Method of Suppressing Hyperactive Liver and Subsiding Yang)	042
2.13	益气养血法(Method of Benefiting Qi and Nourishing Blood)	042
2.14	补益肝肾法(Method of Nourishing Liver and Kidney)	043
2.15	软坚散结法(Method of Softening and Resolving Hard Masses)	043
2.16	退翳明目法(Method of Removing Nebula for Improving Eyesight)	043

## 第4章 红斑痤疮睑皮炎及睑腺疾病

Eyelid Dermatitis in Rosacea and Diseases of Eyelid Glands	045
--	-----

1	红斑痤疮睑皮炎(Eyelid Dermatitis in Rosacea)	045
1.1	红斑痤疮睑皮炎例证及鉴别诊断(Illustrative Cases of Eyelid Dermatitis and Its Differential Diagnosis in Rosacea)	045
1.2	红斑痤疮睑皮炎的西医治疗(Treatment of Eyelid Dermatitis in Rosacea)	048
1.3	红斑痤疮睑皮炎的中医辨证论治(Treatment Based on Syndrome Differentiation of Eyelid Dermatitis with TCM)	048

2 睑腺疾病(Diseases of Eyelid Glands)	050
2.1 睑板腺囊肿(Meibomian Gland Cyst)或称霰粒肿(Chalazion)	050
2.2 睑腺炎(Hordeolum)	051

**第5章 眼红斑痤疮睑板腺功能障碍**  
**Meibomian Gland Dysfunction in Ocular Rosacea** 054

1 睑板腺的解剖生理(Anatomy and Physiology of the Meibomian Gland)	054
2 眼红斑痤疮睑板腺功能障碍的发病机制(Pathogenesis of Meibomian Gland Dysfunction in Ocular Rosacea)	056
2.1 蠕形螨的寄生(Demodex Infestation)	056
2.2 细菌的致病作用(Bacterial Pathogenicity)	057
3 睑板腺功能障碍的组织病理(Histopathology of Meibomian Gland Dysfunction)	058
4 眼红斑痤疮睑板腺功能障碍的临床表现(Clinical Manifestations of Meibomian Gland Dysfunction in Ocular Rosacea)	059
5 眼红斑痤疮睑板腺功能障碍及睑缘炎的西医治疗(Treatment of Meibomian Gland Dysfunction and Blepharitis in Ocular Rosacea)	061
6 睑板腺功能障碍及睑缘炎的中医辨证论治(Treatment Based on Syndrome Differentiation of Meibomian Gland Dysfunction and Blepharitis with TCM)	063
6.1 风热型(Wind-heat Type)	063
6.2 湿热型(Damp-heat Type)	064
6.3 心火上炎型(Flaring up of Heart Fire Type)	064

**第6章 干眼及神经反射性流泪**  
**Dry Eye and Nervous Reflective Tearing** 066

1 干眼(Dry Eye)	066
1.1 干眼的分类及病因(Classification of Dry Eye and Its Causes)	066
1.2 红斑痤疮干眼的病理生理(Pathophysiology of Dry Eye in	



Rosacea)	068
1.3 干眼的临床表现(Clinical Manifestation of Dry Eye)	069
1.4 干眼的临床检查(Clinical Examination of Dry Eye)	070
1.5 干眼的西医治疗(Treatment of Dry Eye)	070
1.6 干眼的中医辨证论治(Treatment Based on Syndrome Differentiation of Dry Eye with TCM)	073
2 神经反射性流泪(Nervous Reflective Tearing)	075
2.1 泪腺分泌的神经控制(Nerve Control of Lacrimal Secretion)	075
2.2 泪腺分泌的激素调节(Hormone Regulation of Lacrimal Secretion)	075
2.3 炎性细胞因子的作用(Inflammatory Cytokine Effect)	076
2.4 泪液分泌过多(Lacrimal Hypersecretion)	076
2.5 泪腺封闭疗法(Therapy of Blocking the Lacrimal Gland)	077

## 第7章 眼红斑痤疮结膜疾病

### Diseases of the Conjunctiva in Ocular Rosacea 080

1 结膜血管异常(Vascular Abnormality of the Conjunctiva)	080
1.1 结膜的血管系统及淋巴系统(Vascular and Lymphatic System of the Conjunctiva)	080
1.2 结膜血管异常的原因(Causes of Vascular Abnormality of the Conjunctiva)	082
1.3 眼红斑痤疮结膜血管异常例证(Illustrative Cases of Vascular Abnormality of the Conjunctiva in Ocular Rosacea)	082
1.4 眼红斑痤疮结膜血管异常的中医辨证论治(Treatment Based on Syndrome Differentiation of Vascular Abnormality of the Conjunctiva in Ocular Rosacea with TCM)	085
2 结膜下出血(Subconjunctival Hemorrhage)	086
2.1 结膜下出血的原因(Causes of Subconjunctival Hemorrhage)	086
2.2 眼红斑痤疮结膜下出血例证(Illustrative Cases of Subconjunctival Hemorrhage in Ocular Rosacea)	087
2.3 结膜下出血的中医辨证论治(Treatment Based on Syndrome Differentiation of Subconjunctival Hemorrhage with TCM)	088

3	结膜炎(Inflammations of the Conjunctiva)	089
3.1	结膜的防卫功能(Defense Function of the Conjunctiva)	089
3.2	慢性结膜炎(Chronic Conjunctivitis)	090
4	结节性结膜炎(Nodular Conjunctivitis)	094
4.1	肉芽肿性结膜炎的原因(Causes of Granulomatous Conjunctivitis)	094
4.2	结节性结膜炎的临床表现及鉴别诊断(Clinical Manifestations and Differential Diagnosis of Nodular Conjunctivitis)	095
4.3	结节性结膜炎例证(Illustrative Cases of Nodular Conjunctivitis)	096
5	泡性结膜炎(Phlyctenular Conjunctivitis)	098
5.1	泡性结膜炎的病因(Causes of the Phlyctenular Conjunctivitis)	098
5.2	泡性角膜结膜炎的临床表现(Clinical Manifestation of Phlyctenular Keratoconjunctivitis)	099
5.3	泡性结膜炎的西医治疗(Treatment of Phlyctenular Conjunctivitis)	100
5.4	结节性结膜炎及泡性结膜炎的中医辨证论治(Treatment Based on Syndrome Differentiation of the Conjunctivitis Nodosa and Phlyctenular Conjunctivitis with TCM)	100

## 第8章 眼红斑痤疮角膜疾病

### Disorders of the Cornea in Ocular Rosacea 104

1	角膜的防卫功能(Defensive Functions of the Cornea)	104
2	浅层点状角膜病变(Superficial Punctate Keratopathy)	105
2.1	丝状角膜病变(Filamentary Keratopathy)	106
2.2	眼红斑痤疮丝状角膜炎的例证(Illustrative Cases of Filamentary Keratitis in Ocular Rosacea)	107
2.3	浅层点状角膜病变的中医辨证论治(Treatment Based on Syndrome Differentiation of Superficial Punctate Keratopathy with TCM)	108
3	边缘性角膜炎(Marginal Keratitis)	109
3.1	边缘性角膜炎或溃疡的原因(Causes of Marginal Keratitis and Ulcer)	109



3.2	边缘性角膜炎或溃疡的临床表现(Clinical Manifestations of Marginal Keratitis or Ulcer)	110
3.3	边缘性角膜炎或溃疡例证(Illustrative Cases of Marginal Keratitis or Ulcer)	111
3.4	边缘性角膜炎或溃疡的中医辨证论治(Treatment Based on Syndrome Differentiation of Marginal Keratitis or Ulcer with TCM)	112
4	角膜基质炎(Interstitial Keratitis)	114
4.1	角膜基质炎的原因(Causes of Interstitial Keratitis)	114
4.2	角膜基质炎的临床表现(Clinical Manifestations of Interstitial Keratitis)	115
4.3	眼红斑痤疮角膜基质炎例证(Illustrative Cases of Interstitial Keratitis in Ocular Rosacea)	116
4.4	角膜基质炎的中医辨证论治(Treatment Based on Syndrome Differentiation of Interstitial Keratitis with TCM)	118

## 第9章 眼红斑痤疮及相关结缔组织疾病巩膜炎

### Scleritis in Ocular Rosacea and Associated Connective Tissue Diseases

121

1	巩膜外层炎(Episcleritis)	121
1.1	巩膜外层炎的发病机制(Pathogenesis of Episcleritis)	121
1.2	巩膜外层炎的临床表现(Clinical Manifestations of Episcleritis)	122
1.3	眼红斑痤疮巩膜外层炎例证(Illustrative Case of Episcleritis in Ocular Rosacea)	122
1.4	巩膜外层炎的西医治疗(Treatment of Episcleritis)	123
2	巩膜炎(Scleritis)	123
2.1	巩膜炎的发病机制(Pathogenesis of Scleritis)	123
2.2	巩膜炎的临床表现(Clinical Manifestations of Scleritis)	124
2.3	巩膜炎的并发症(Complications of Scleritis)	125
2.4	巩膜炎的西医治疗(Treatment of Scleritis)	126
3	巩膜外层炎和巩膜炎的中医辨证论治(Treatment Based on Syndrome Differentiation of Episcleritis and Scleritis with TCM)	127
3.1	巩膜外层炎的中医辨证论治(Treatment Based on	

Syndrome Differentiation of Episcleritis with TCM	127
3.2 巩膜炎的中医辨证论治 (Treatment Based on Syndrome Differentiation of Scleritis with TCM)	127

**第 10 章 眼红斑痤疮眼内组织损害**  
**Intraocular Tissue Involvement in Ocular Rosacea 131**

1 前葡萄膜炎 (Anterior Uveitis)	131
1.1 前葡萄膜炎的病因 (Causes of Anterior Uveitis)	131
1.2 眼红斑痤疮前葡萄膜炎的临床表现及分析 (Clinical Manifestations and Analysis of Anterior Uveitis in Ocular Rosacea)	132
1.3 红斑痤疮前葡萄膜炎的西医治疗 (Treatment of Anterior Uveitis in Rosacea)	133
1.4 前葡萄膜炎的中医辨证论治 (Treatment Based on Syndrome Differentiation of Anterior Uveitis with TCM)	133
2 并发性白内障 (Complicated Cataract)	135
2.1 眼红斑痤疮并发白内障例证 (Illustrative Case of Complicated Cataract in Ocular Rosacea)	135
2.2 与酒精中毒并发白内障的鉴别诊断 (Differential Diagnosis with Complicated Cataract from Alcoholism)	136
2.3 白内障的西医治疗 (Treatment for Cataract)	136

**第 11 章 儿科眼红斑痤疮**  
**Pediatric Ocular Rosacea 138**

1 儿童眼红斑痤疮病例回顾 (A Review of Child Ocular Rosacea Cases)	138
2 儿童眼红斑痤疮鉴别诊断 (Differential Diagnosis of Child Ocular Rosacea)	152
2.1 睑缘角结膜炎 (Blepharokeratoconjunctivitis, BKC)	152
2.2 特应性皮炎 (Atopic Dermatitis)	153
2.3 脂溢性皮炎 (Seborrheic Dermatitis)	153
3 儿童眼红斑痤疮例证 (Illustrative Cases of Child Ocular Rosacea)	154