

Jerzy Olszewski and Donald Baxter

Cytoarchitecture
of the Human Brain Stem

2nd Edition



Cytoarchitecture of the Human Brain Stem

by

JERZY OLSZEWSKI

M.D. (Wilno), Dr. med. (Freiburg/Br.), Ph.D. (McGill)

Assistant Professor of Neuroanatomy, Department of Neurology and Neurosurgery, McGill University,
and Associate Neuroanatomist, Montreal Neurological Institute

and

DONALD BAXTER

M.D., C.M. (Queen's), M.Sc. (McGill)

Research Fellow, Montreal Neurological Institute

2nd Edition, 1982



S. Karger · Basel · München · Paris · London · New York · Sydney

Cytoarchitecture of the Human Brain Stem
1st Edition, 1954

National Library of Medicine, Cataloging in Publication

Olszewski, Jerzy

Cytoarchitecture of the human brain stem by

Jerzy Olszewski and Donald Baxter -

2nd ed. - Basel; New York; Karger, 1982

1. Brain Stem - cytology - atlases

I. Baxter, Donald II. Title

WL 17 052c

ISBN 3-8055-2210-X

All rights reserved.

No part of this publication may be translated into other languages,
reproduced or utilized in any form or by any means, electronic or mechanical,
including photocopying, recording, microcopying, or by any information
storage and retrieval system, without permission in writing from the publisher.

© Copyright 1982 by S. Karger AG, P. O. Box, CH-4009 Basel (Switzerland)

ISBN 3-8055-2210-X

TABLE OF CONTENTS

	Page		Page
I. <i>Introduction</i>	7	Nucleus paramedianus dorsalis	124
Cytoarchitectonics	7	Nucleus subventricularis	126
Reticular formation	12	Griseum pontis	127
II. <i>Material</i>	14	Nucleus interpeduncularis	129
III. <i>Method</i>	14	Nucleus substantiae nigrae	131
IV. <i>Alphabetical Index of Nuclei</i>	16	Nucleus ruber	132
V. <i>Serial Semischematic Drawings and Photomicrographs</i>	17	Colliculus superior	136
VI. <i>Cranial Nerve Nuclei</i>	61	VIII. <i>Nuclei of Unknown Connections</i>	141
Nucleus nervi hypoglossi	62	Area postrema	142
Nucleus supraspinalis	64	Nucleus retroambigualis	144
Nucleus ambiguus	65	Nucleus conterminalis	145
Nucleus dorsalis motorius nervi vagi	66	Nucleus medullae oblongatae centralis	146
Nucleus tractus solitarii	68	Nucleus subtrigeminalis	148
Nucleus cochlearis dorsalis	72	Nucleus intercalatus	149
Nucleus cochlearis ventralis	72	Nucleus of Roller	150
Nucleus vestibularis medialis	74	Nucleus interfascicularis hypoglossi	151
Nucleus vestibularis spinalis	75	Nucleus praepositus hypoglossi	152
Nucleus vestibularis lateralis	76	Nucleus suprageniculatus	154
Nucleus vestibularis superior	78	Nucleus parvocellularis compactus	155
Nucleus nervi facialis	80	Nucleus gigantocellularis	156
Nucleus nervi abducentis	82	Nucleus paragigantocellularis lateralis	159
Nucleus tractus spinalis trigemini caudalis	83	Nucleus paragigantocellularis dorsalis	160
Nucleus tractus spinalis trigemini interpolaris	85	Nucleus raphae pallidus	161
Nucleus tractus spinalis trigemini oralis	86	Nucleus raphae obscurus	163
Nucleus nervi trigemini sensibilis principalis	88	Nucleus supravestibularis	164
Nucleus nervi trigemini motorius	88	Nucleus interpositus	165
Nucleus nervi trigemini mesencephalicus	90	Nucleus parvocellularis	166
Nucleus nervi trochlearis	93	Nucleus ovalis	167
Nucleus oculomotorius principalis	94	Nucleus pontis centralis caudalis	168
Nucleus caudalis centralis	95	Nucleus pontis centralis oralis	169
Nucleus of Perlia	96	Nucleus locus coeruleus	170
Nucleus Edinger Westphal	98	Nucleus subcoeruleus	173
Nucleus retrofacialis	100	Nucleus papillioformis	174
Nucleus nervi facialis accessorius	100	Griseum centrale pontis	175
Nucleus retrotrigeminalis	102	Nucleus centralis superior	177
VII. <i>Relay Nuclei</i>	103	Nucleus parabrachialis medialis	178
Nucleus gracilis	104	Nucleus parabrachialis lateralis	179
Nucleus cuneatus medialis	104	Griseum centrale mesencephali	181
Nucleus cuneatus lateralis	106	Nucleus compactus suprafascicularis	182
Nucleus medullae oblongatae lateralis	108	Nucleus compactus interfascicularis	182
Nucleus olivaris inferior	111	Nucleus intercollicularis	183
Nucleus trapezoidalis	113	Nucleus sagulum	184
Nucleus olivaris superior	114	Nucleus paralemniscalis	185
Nucleus lemnisci lateralis ventralis	116	Nucleus supratrochlearis	186
Nucleus lemnisci lateralis dorsalis	117	Nucleus of Darkschewitsch	188
Nucleus colliculi inferioris	118	Nucleus interstitialis (Cajal)	190
Nucleus arcuatus	120	Nucleus intracapsularis	191
Nuclei pararaphales	121	Nucleus cuneiformis	192
Nucleus corporis pontobulbaris	123	Nucleus subcuneiformis	193
		Nucleus intracuneiformis	194
		Nucleus tegmenti pedunculopontinus	195
		Nucleus parabrachialis pigmentosus	196
		Nucleus paranigralis	197
		Nucleus peripeduncularis	198
		IX. <i>General References</i>	199

Cytoarchitecture of the Human Brain Stem

by

JERZY OLSZEWSKI

M.D. (Wilno), Dr. med. (Freiburg/Br.), Ph.D. (McGill)

Assistant Professor of Neuroanatomy, Department of Neurology and Neurosurgery, McGill University,
and Associate Neuroanatomist, Montreal Neurological Institute

and

DONALD BAXTER

M.D., C.M. (Queen's), M.Sc. (McGill)

Research Fellow, Montreal Neurological Institute

2nd Edition, 1982



S. Karger · Basel · München · Paris · London · New York · Sydney

Cytoarchitecture of the Human Brain Stem
1st Edition, 1954

National Library of Medicine, Cataloging in Publication
Olszewski, Jerzy

Cytoarchitecture of the human brain stem by
Jerzy Olszewski and Donald Baxter -
2nd ed. - Basel; New York; Karger, 1982

I. Brain Stem - cytology - atlases

I. Baxter, Donald II. Title

WL 17 052c

ISBN 3-8055-2210-X

All rights reserved.

No part of this publication may be translated into other languages,
reproduced or utilized in any form or by any means, electronic or mechanical,
including photocopying, recording, microcopying, or by any information
storage and retrieval system, without permission in writing from the publisher.

© Copyright 1982 by S. Karger AG, P. O. Box, CH-4009 Basel (Switzerland)
ISBN 3-8055-2210-X

TABLE OF CONTENTS

	Page		Page
I. <i>Introduction</i>	7	Nucleus paramedianus dorsalis	124
Cytoarchitectonics	7	Nucleus subventricularis	126
Reticular formation	12	Griseum pontis	127
II. <i>Material</i>	14	Nucleus interpeduncularis	129
III. <i>Method</i>	14	Nucleus substantiae nigrae	131
IV. <i>Alphabetical Index of Nuclei</i>	16	Nucleus ruber	132
V. <i>Serial Semischematic Drawings and Photomicrographs</i>	17	Colliculus superior	136
VI. <i>Cranial Nerve Nuclei</i>	61	VIII. <i>Nuclei of Unknown Connections</i>	141
Nucleus nervi hypoglossi	62	Area postrema	142
Nucleus supraspinalis	64	Nucleus retroambigualis	144
Nucleus ambiguus	65	Nucleus conterminalis	145
Nucleus dorsalis motorius nervi vagi	66	Nucleus medullae oblongatae centralis	146
Nucleus tractus solitarii	68	Nucleus subtrigeminalis	148
Nucleus cochlearis dorsalis	72	Nucleus intercalatus	149
Nucleus cochlearis ventralis	72	Nucleus of Roller	150
Nucleus vestibularis medialis	74	Nucleus interfascicularis hypoglossi	151
Nucleus vestibularis spinalis	75	Nucleus praepositus hypoglossi	152
Nucleus vestibularis lateralis	76	Nucleus suprageniculatus	154
Nucleus vestibularis superior	78	Nucleus parvocellularis compactus	155
Nucleus nervi facialis	80	Nucleus gigantocellularis	156
Nucleus nervi abducentis	82	Nucleus paragigantocellularis lateralis	159
Nucleus tractus spinalis trigemini caudalis	83	Nucleus paragigantocellularis dorsalis	160
Nucleus tractus spinalis trigemini interpolaris	85	Nucleus raphae pallidus	161
Nucleus tractus spinalis trigemini oralis	86	Nucleus raphae obscurus	163
Nucleus nervi trigemini sensibilis principalis	88	Nucleus supravestibularis	164
Nucleus nervi trigemini motorius	88	Nucleus interpositus	165
Nucleus nervi trigemini mesencephalicus	90	Nucleus parvocellularis	166
Nucleus nervi trochlearis	93	Nucleus ovalis	167
Nucleus oculomotorius principalis	94	Nucleus pontis centralis caudalis	168
Nucleus caudalis centralis	95	Nucleus pontis centralis oralis	169
Nucleus of Perlia	96	Nucleus locus coeruleus	170
Nucleus Edinger Westphal	98	Nucleus subcoeruleus	173
Nucleus retrofacialis	100	Nucleus papillioformis	174
Nucleus nervi facialis accessorius	100	Griseum centrale pontis	175
Nucleus retrotrigeminalis	102	Nucleus centralis superior	177
VII. <i>Relay Nuclei</i>	103	Nucleus parabrachialis medialis	178
Nucleus gracilis	104	Nucleus parabrachialis lateralis	179
Nucleus cuneatus medialis	104	Griseum centrale mesencephali	181
Nucleus cuneatus lateralis	106	Nucleus compactus suprafascicularis	182
Nucleus medullae oblongatae lateralis	108	Nucleus compactus interfascicularis	182
Nucleus olivaris inferior	111	Nucleus intercollicularis	183
Nucleus trapezoidalis	113	Nucleus sagulum	184
Nucleus olivaris superior	114	Nucleus paralemniscalis	185
Nucleus lemnisci lateralis ventralis	116	Nucleus supratrochlearis	186
Nucleus lemnisci lateralis dorsalis	117	Nucleus of Darkschewitsch	188
Nucleus colliculi inferioris	118	Nucleus interstitialis (Cajal)	190
Nucleus arcuatus	120	Nucleus intracapsularis	191
Nuclei pararaphales	121	Nucleus cuneiformis	192
Nucleus corporis pontobulbaris	123	Nucleus subcuneiformis	193
		Nucleus intracuneiformis	194
		Nucleus tegmenti pedunculo-pontinus	195
		Nucleus parabrachialis pigmentosus	196
		Nucleus paranigralis	197
		Nucleus peripeduncularis	198
		IX. <i>General References</i>	199

FOREWORD TO THE 1ST EDITION

Recent physiological studies have shown the importance of a system of cells, distributed throughout the brain stem, and somewhat loosely called "the reticular formation". But up till now no atlas of the human brain stem has described, in at all adequate fashion, either the distribution or the histological appearance of the nerve cells which constitute this formation. The need to fill this gap was the primary stimulus to the study of the cytology of the brain stem which has resulted in this atlas.

The authors have not only brought together what was already known about the *formatio reticularis*, but have added several fresh observations on its structure. While this may be the only original part of the atlas, in many other ways it helps to fill the constantly growing need for more detailed knowledge of the structure of the central nervous system. It is a truism that the acquisition of this knowledge is the most difficult part of the training of a neuropathologist; indeed there are few, if any, whose knowledge is so complete that they can dispense with frequent references to atlases of the normal. Most of those which deal with the brain stem are based on sections stained for myelin, and although the position of the various nerve cell nuclei is indicated, neither the peculiar grouping of the cells, nor the special characters of the individual cells in the different nuclei, is described. The present atlas is arranged to supply both these needs. It includes photomicrographs in three or more magnifications; the lowest indicates the position and extent of the nuclei in sections at right angle to the long axis of the brain stem; a medium magnification shows the details of grouping of the cells in the various nuclei, and higher magnifications give detailed views of the structure of the individual cells with Nissl's stain. The importance of being able to recognise the cells belonging to a certain system, not only by their position but also by their peculiarities of structure, has always been stressed by Cecile and Oskar Vogt, in whose laboratory the senior author was trained. It has long been recognised for such special cells as the pigmented nerve cells in the floor of the 4th ventricle and surrounding the nucleus ruber, and those of the mesencephalic trigeminal nucleus, but it is here applied also to nuclei in which the nerve cells have less obvious characteristics. This aspect of the work is of special value as it helps both in distinguishing nuclei in sections cut in unusual planes, and in assessing departures from the normal in pathological material.

The production of a first class atlas of the central nervous system requires from its authors both profound anatomical knowledge, brought up to date as far as possible, and a high degree of artistic skill. This atlas meets both requirements, satisfying the eye as well as the mind, and it may be hoped that it will soon take its place in most libraries alongside the classical atlases of the nervous system.

J. G. Greenfield

FOREWORD TO THE 2ND EDITION

The closing sentence of the foreword to the first edition of this atlas in 1954 by Greenfield has been fully confirmed in the past years. Greenfield wrote: "This atlas meets both requirements, satisfying the eye as well as the mind, and it may be hoped that it will soon take its place in most libraries alongside the classical atlases of the nervous system." Indeed, the Olszewski atlas means a hallmark and became an indispensable auxiliary of the neuroscientist and neuropathologist in their daily work. For description of the site, extension and intensity of focal lesions in the brain stem of any kind it is necessary to identify exactly the many individual cell groups which only can be done appropriately on sections stained for cells. The recognition of defined nuclei in not-serial sections and on atypical plans also for the experienced scientist requires certain help by neurohistological documentation. Furthermore it has become relevant to perceive and to distinguish the kind of changes of the fine cellular structure for defining the quality or peculiarity of a pathological process. That, too, is only possible on the basis of comparison with the normal appearance of the affected nerve cell. These pathohistological functions of the atlas recently became still more important because of the increased application of electron microscopical studies also in human neuropathology. For evaluation and interpretation of so-called semithin sections regarding the selection of relevant sites for high power preparations the cytological details are fundamental. This means a new field of use of the Olszewski atlas in human neuropathology.

The arrangement of the atlas represents the localization and the size of a nucleus in the plan perpendicular to the brain stem axis as well as by higher magnifications the kind of cell grouping and the particular structure of individual cells: This pattern has equally proved very practicable.

The undertaking of a reprint of the atlas will be highly appreciated by all workers in the field of neuroanatomy and neuropathology because of the great need of that topographic guide through the complicated three-dimensional cytological structures of the human brain stem.

August, 1981

F. Seitelberger

ACKNOWLEDGEMENTS

The preparation of this monograph over a relatively short period of time has required the co-operation and labor of many persons, apart from the authors. It is with great pleasure that we acknowledge our debt to these individuals.

Dr. Wilder Penfield allowed us the use of the extensive facilities available at the Montreal Neurological Institute. His interest and advice in the many problems encountered during the past year, and his help in obtaining the funds necessary for publication are greatly appreciated.

Dr. Francis McNaughton's advice, in regard to anatomical and other features of the work, was frequently sought and generously given.

Our greatest debt is to Mrs. M. Legewie-Heymann. As a highly skilled neurohistological technician, Mrs. Heymann was responsible for the preparation of most of the histological material used in this investigation. In addition, she has provided invaluable assistance in almost every aspect of our work. Without her skill, intelligence and good humor this atlas would have been much longer in the making.

Our problems regarding Latin nomenclature and the inconsistencies of the English language were referred to Dr. W. W. Francis, Curator of the Osler Library, McGill University. His valuable comments have saved us many hours of labor.

The interest which Dr. F. Mettler, Columbia University, New York, and Dr. D. White, Queen's University, Kingston, have shown in our work is greatly appreciated.

Dr. J. Stratford, Dr. D. Ingvar and Dr. C. Bélanger have read portions of the manuscript and offered valuable suggestions.

All photographs and photomicrographs were prepared in the Department of Photography of the Montreal Neurological Institute by Mr. Charles Hodge and Mr. Ronald Haram. The quality and uniformity of the illustrations is ample evidence of their skill and patience.

Valuable technical assistance in the preparation of histological sections was given by Mrs. A. Szczeniowska, and in the preparation of semischematic drawings by Mr. K. Wyllie and Mr. M. Munnich. The final typing and checking of the manuscript was done with meticulous care by Mrs. D. C. Spicer.

Publication of this atlas has been made possible by grants from the National Research Council of Canada and from the Francis McNaughton Neuroanatomical Research Fund of the Montreal Neurological Institute. The co-operation and advice of Dr. G. H. Ettinger and of Dr. J. B. Marshall both of the National Research Council are gratefully acknowledged. The junior author has an additional debt to the National Research Council of Canada in that he held a Medical Research Fellowship during the past year.

Finally, we wish to thank the publisher, especially Mr. Thomas Karger for his co-operation in fulfilling our numerous wishes and for his personal interest and care in making book publishing an art.

June, 1953.

J. O. and D. B.

I. INTRODUCTION

This work had its inception in 1945 when C. and O. Vogt suggested to one of us (J. O.) the need for investigation of the reticular formation of the brain stem. The Vogts felt that their studies of the extrapyramidal diseases, limited to an investigation of the basal ganglia, had illuminated only one aspect of the problem. In their opinion thorough knowledge of the morphological and functional organization of the reticular formation was indispensable for the understanding of the regulation and co-ordination of motor activity by the extrapyramidal systems. Accordingly, a study of the normal cytoarchitecture of the reticular formation was commenced at the Brain Research Institute, Neustadt, with the intention of applying this knowledge in the investigation of pathological material at a later date. For various reasons this work was interrupted for a period of several years, and it was not until 1952 that it was resumed at the Montreal Neurological Institute.

It soon became apparent that it was advisable to extend the scope of the project to include the cytoarchitecture of all the gray masses of the lower brain stem. This conclusion was based largely on the lack of precise definition of the boundaries of the reticular formation and the insufficient data available concerning the cytoarchitecture of many nonreticular nuclei.

At the present time the most comprehensive descriptions of the cytoarchitecture of the human brain stem are to be found in Jacobsohn's "Über die Kerne des menschlichen Hirnstamms" (1909) and in Ziehen's "Anatomie des Centralnervensystems" (1933). Jacobsohn's widely utilized drawings of cross sections of the brain stem constitute the most accurate guide at present available for delineation of the various nuclear masses. These drawings are necessarily overschematized due to their small size, and neither they nor the descriptions of nuclei are supplemented by photomicrographs. Ziehen's exhaustive description of the cyto- and myeloarchitecture and fiber connections of the brain stem, supplemented by an extensive bibliography, suffers from the lack of representative serial cross sections stained for nerve cells. In addition the photomicrographs presented are limited to a few myelin stained preparations.

Marburg devotes a considerable part of his atlas to the description of the cytoarchitecture of the human brain stem, but presents only five schematic representations of Nissl stained cross sections and includes no photomicrographs of this region.

More cytoarchitectural detail of various regions of the human brain stem may be found in the monographs of Gagel and Bodechtal (1930), Stern (1936) and Crosby and Woodburne (1943), all of which are illustrated by excellent photomicrographs. Riley's "Atlas of the Basal Ganglia, Brain Stem and Spinal Cord" (1943), although not directly concerned with cytoarchitecture, should be mentioned as an invaluable guide to any student of these regions. Apart from these comprehensive reviews, innumerable other investigators have confined their studies to the anatomy of individual brain stem nuclei.

The present work is an attempt to portray adequately and objectively the cytoarchitecture of all the nuclear structures of the medulla oblongata, pons and midbrain. In addition to the presentation of formerly recognized nuclei, several previously undescribed cell groups have been delineated on the basis of cytoarchitectonic criteria. The majority of these lie within the reticular formation.

The contents of the monograph fall naturally into two parts. The first consists of a series of nineteen semischematic representative cross sections of the brain stem, accompanied by low power photomicrographs. Descriptions of the individual nuclei, supplemented by photomicrographs of higher magnifications, compose the second part. It is hoped that this atlas will prove of value to the neuroanatomist who is interested in the position and morphology of the individual nuclei, and to the neuropathologist in his attempts to localize pathological processes and to distinguish abnormal cell forms from the confusing array of morphologically different normal cells found within various regions of the brain stem. Further, the neurophysiologist may find it useful to have available detailed human morphological data which can be correlated with that of experimental animals, and with which his functional concepts may be integrated.

Cytoarchitectonics

The term cytoarchitectonics is applied to a method of anatomical investigation which is primarily concerned with patterns of arrangement and morphological details of nerve cells as revealed by magnifications within the range of the ordinary light microscope. The staining method almost exclusively used is the Nissl technique or one of its innumerable variants. The

primary objective of the cytoarchitectonic method is the subdivision of the cellular masses of the nervous system into regions with distinctive morphological characteristics. Such regions are referred to as "areas" in the cortical gray matter, and as "nuclei" in the sub-cortical gray matter. The value of the method rests on the hypothesis that the criteria used for cytoarchitectonic subdivisions are of biological significance. In other words, groups of cells delineated by this method presumably possess certain properties of biological importance which distinguish them from their neighbors. Such properties include a differential reaction to disease processes, a characteristic developmental and evolutionary cycle, and a distinctive functional import.

It follows from the above that, by definition, a nucleus is characterized not only by distinctive morphological features but also by a distinctive function. Accordingly, a major value of the cytoarchitectonic approach is that it allows the anatomist to postulate that nuclei possessing different morphological characteristics must differ in their function and other biological properties. This brings us to the important problem of the correlation of the morphology of a neurone and its function.

The concept of the function of a neurone differs, depending upon whether it is considered as a single isolated unit (basic function) or as a constituent of an integrated cell population (specialized function). In the light of present knowledge, it seems probable that the basic function of all neurones is essentially the same. This function is the generation of nerve impulses when the cell is adequately stimulated. However, several recent concepts, if proved correct, may make modification of this statement necessary. These include (1) the possibility that chemical transmitters released by different cell types of the central nervous system may differ; (2) the suggestion that certain neurones may exert inhibitory influences as contrasted to excitatory influences of other neurones; and (3) the possibility that the physicochemical processes essential for generation and propagation of a nerve impulse may be different in different neurones. In regard to this third point it must be borne in mind that the identity of electrical side effects of nerve impulses need not, of necessity, indicate the identity of the basic underlying physicochemical phenomena.

The concept of a specialized neuronal function is applied when reference is made to the activity of cells as constituents of a particular nucleus. For example, the cells of the lateral geniculate body are concerned with the reception, integration and transmission of visual impulses, those of the hypoglossal nucleus with the motor innervation of the tongue, and those of the main sensory nucleus of the trigeminal nerve with the reception, integration and transmission of tactile im-

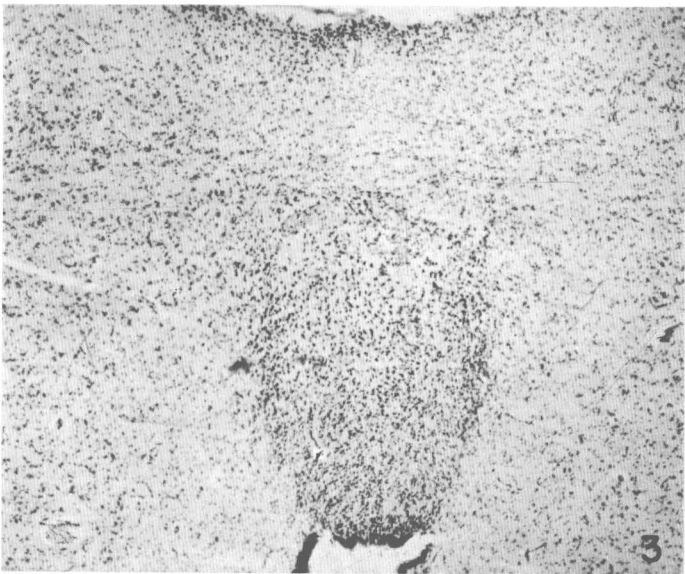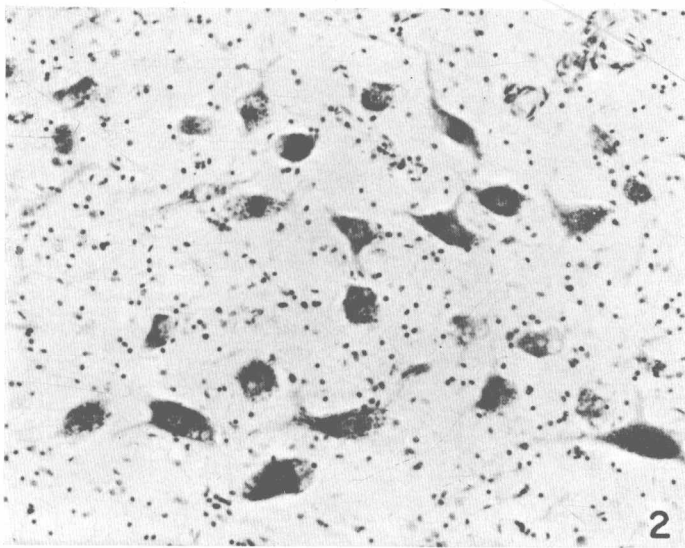
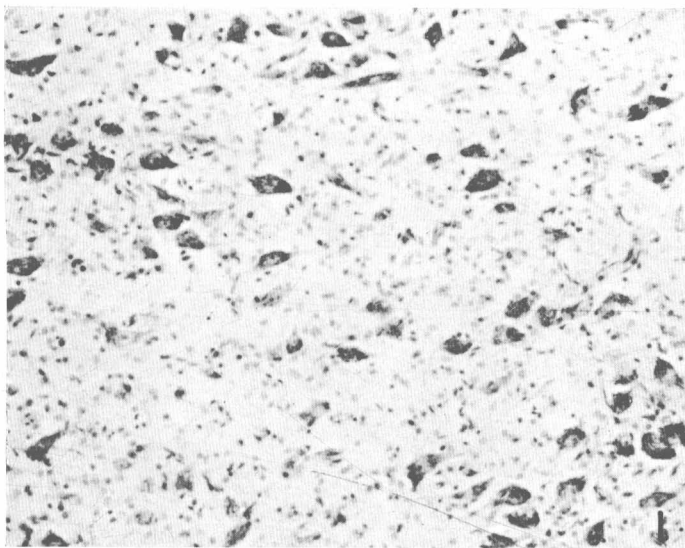
pulses from the face. It is apparent that the function of neurones in this sense is determined predominantly by their efferent and afferent connections.

Returning now to the discussion of the relationship between structure and function it is probable that both the basic and the specialized function of a cell may be correlated with its structure. At the moment, however, most emphasis is placed on the specialized functions, and many instances of such correlation may be found within the brain stem. Thus the nuclei which give rise to fibers supplying the motor innervation to somatic and branchiomeric musculature are composed of neurones which are morphologically similar; the cells composing the nuclei of the visceral efferent column, i.e. the dorsal motor nucleus of the vagus and the nucleus of Edinger Westphal, belong to the same morphological type; and the cells of the nucleus of the mesencephalic trigeminal root resemble closely those found in the dorsal root ganglia. The question now arises whether this correlation is sufficiently valid to allow us to postulate that cell groups of similar morphology must possess similar functional significance. For example, is it permissible to assume that the nucleus supratrochlearis, the cells of which possess morphological features similar to those of the visceral efferent nuclei, must give rise to preganglionic autonomic fibers? In our opinion such suggestions, although valuable, must be advanced very cautiously. The final answer to such questions may be obtained only by the application of other neuroanatomical as well as neurophysiological methods.

Nevertheless, the postulate that morphological differences between two nuclei invariably indicate a difference in the function of the constituent cells remains valid. The apparent contradictions which one occasionally encounters should not be accepted with indifference but rather should serve as incentive to further study. The observation that the cells of the ventral and dorsal cochlear nuclei are different in structure, in spite of the fact that their efferent and afferent connections appear to be similar, is one such example. It is conceivable that different integratory mechanisms within each of these nuclei, or different and as yet unknown connections may be responsible for this morphological dissimilarity.

Addendum

The cytoarchitectural features characteristic of the individual nuclei which compose the human brain stem remain remarkably constant from one brain stem to another. This is true not only of the overall appearance of the nucleus, but also of those morphological features which characterize the various cell types such as the size and shape of the cell, the position of the nucleus, the length and stainability of the processes and the



- Fig. 1. Motor trigeminal nucleus of a premature baby (7th month). Mag. 150 \times .
- Fig. 2. Motor trigeminal nucleus of a 47-year-old male. Mag. 150 \times .
- Fig. 3. Dorsal portion of the griseum centrale mesencephali of a premature baby (7th month). Note the clear delineation of the subnucleus dorsalis. Compare with plate XXXIX.

pattern of distribution of Nissl granules. One does occasionally, however, note quite marked differences in the *size* of the cells of homologous nuclei in the brain stems of adult humans of comparable ages. It seems possible that slight variations in the technique of preserving and embedding the blocks may partially account for this observation.

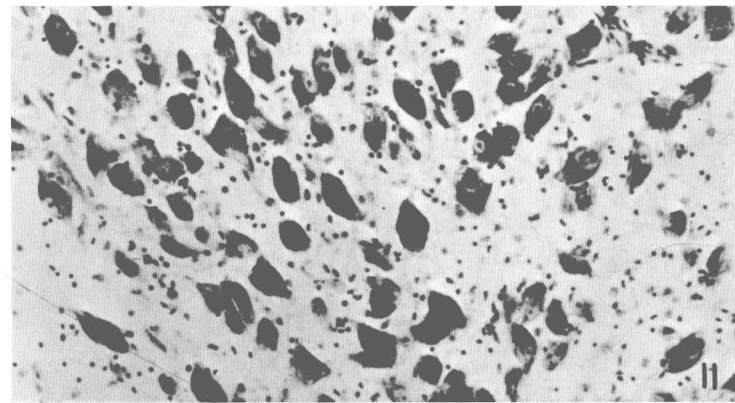
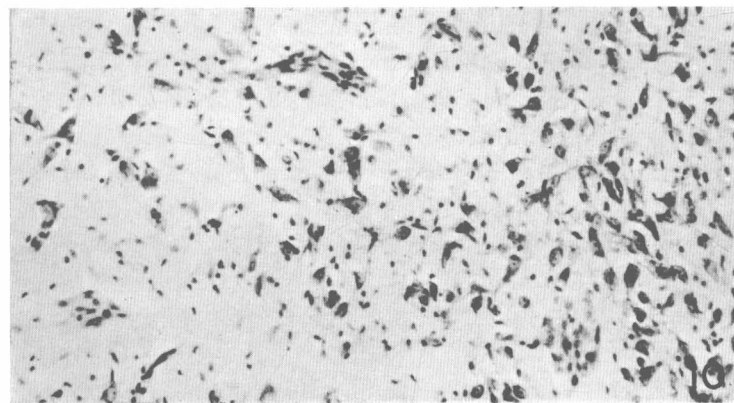
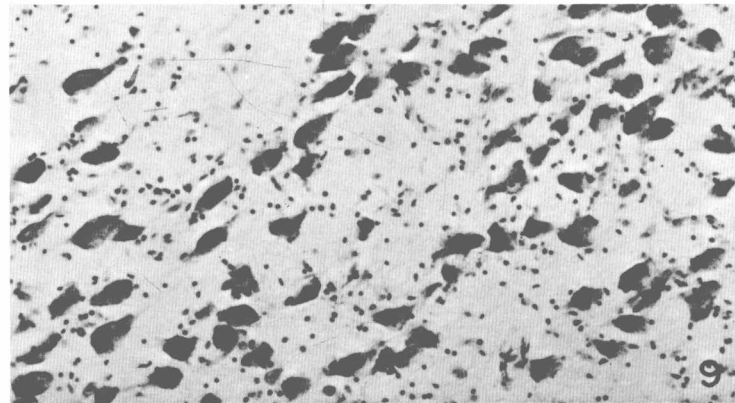
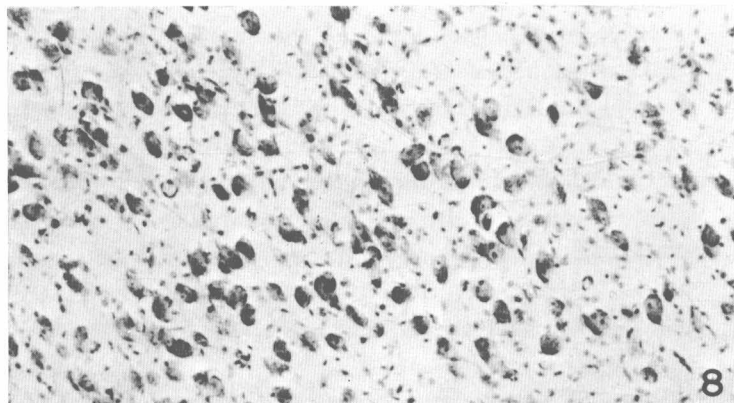
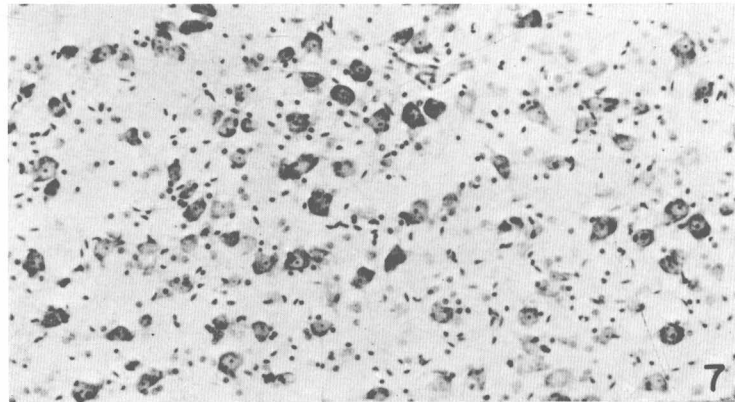
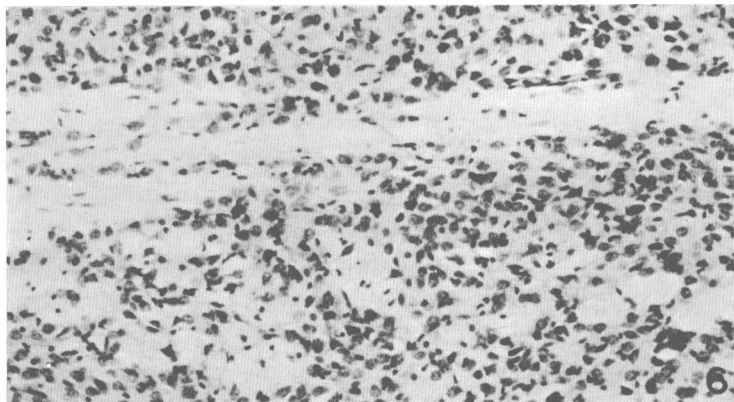
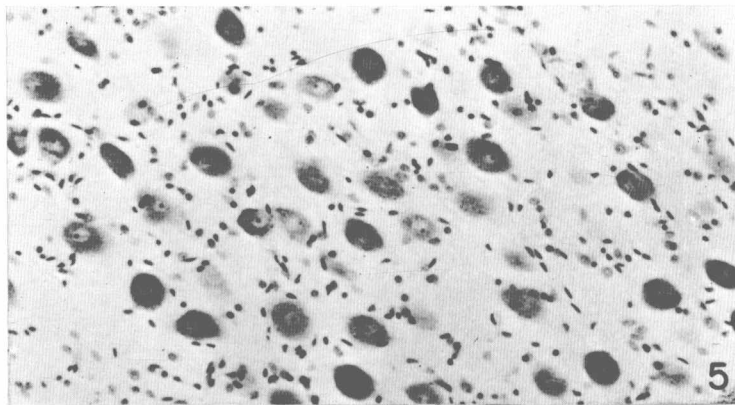
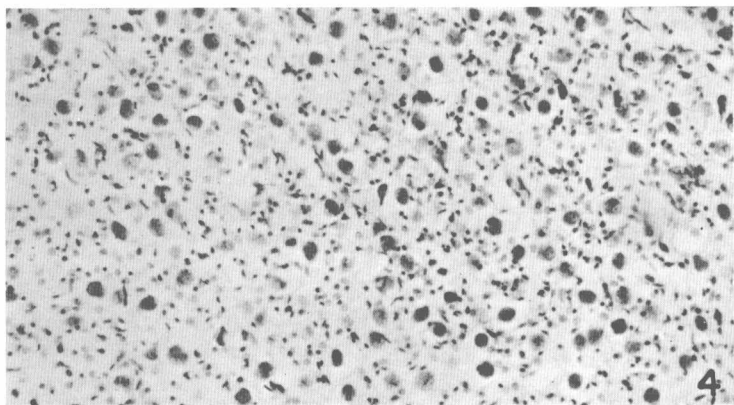
If one examines the brain stems of individuals at the extremes of life, certain cytoarchitectural features characteristic of both the infant and the elderly adult may be observed.

The most notable difference, as viewed through a microscope, between a baby's brain stem and that of an adult is the impression of compactness that one gains from the former. Here the cells composing the nuclei are relatively small and closely arranged and the glial background is much more dense than it is in the adult. This compact arrangement of both cells and glia, which is probably largely due to the unmyelinated state of the majority of fibers in the infant's brain stem, serves to emphasize the borders of structures characterized by the accumulation either of cells or of glial nuclei (figs. 1 to 7).

In general, cells composing the nuclei of an infant's brain stem are similar to those which compose the homologous nuclei in the adult. One notable exception to this statement is the lack of visible melanin pigment in the cytoplasm of any nerve cells of the infant or young child—a feature noted particularly in the cells of the locus coeruleus and the nucleus substantiae nigrae (figs. 8 to 11). This pigment, the significance of which is not known, does not begin to accumulate until the fourth or fifth year of life.

The most striking characteristic of the aging nerve cell is the accumulation of the pigment lipofuscin. This pigment, which first appears in some cells in early adult life, becomes more and more abundant in an ever increasing number of nerve cells as the individual ages. It accumulates in the form of small yellowish-brown, intracytoplasmic granules which either displace or replace the Nissl substance (fig. 12). Certain nerve cells appear particularly susceptible to the accumulation of lipofuscin. This is true of the cells of the inferior olive where this pigment appears at a relatively early age and, with increasing age, accumulates in some cells to such a degree that the cytoplasm is completely replaced, and the nerve cell is no longer visible in Nissl preparations. This accounts for the relative acellularity of the inferior olive of an elderly human when compared with that of a young adult. Different degrees of accumulation of lipofuscin in the cells of the inferior olive are represented in figures 16 to 18. On the other hand, cells such as the Purkinje cells of the cerebellum rarely, if ever, accumulate lipofuscin.

Lipofuscin is usually considered to be insoluble in



Figs. 4 to 11. In the left column the following nuclei of a premature baby (7th month) are represented: ventral cochlear nucleus (fig. 4), griseum pontis (fig. 6), nucleus of the locus coeruleus (fig. 8) and nucleus substantiae nigrae (fig. 10). In the right column the corresponding nuclei of an adult are pictured. Magnification of all photomicrographs 150 \times .

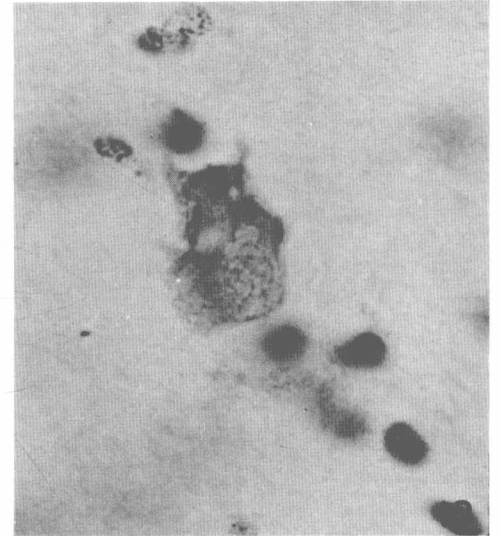
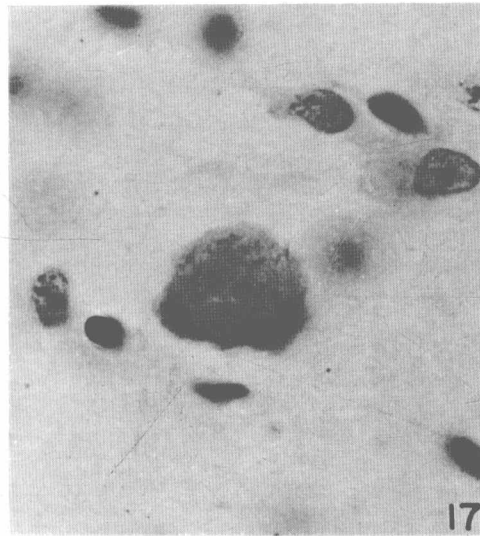
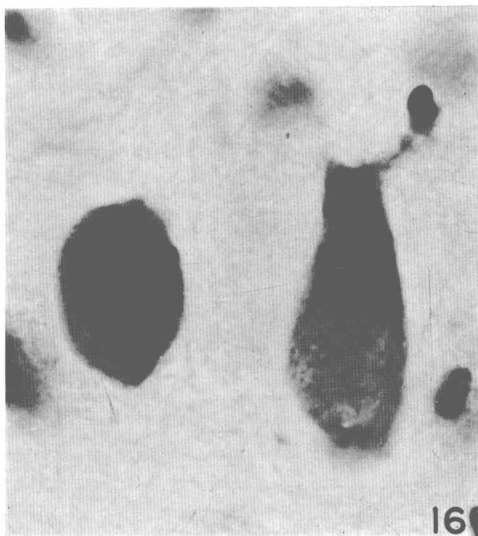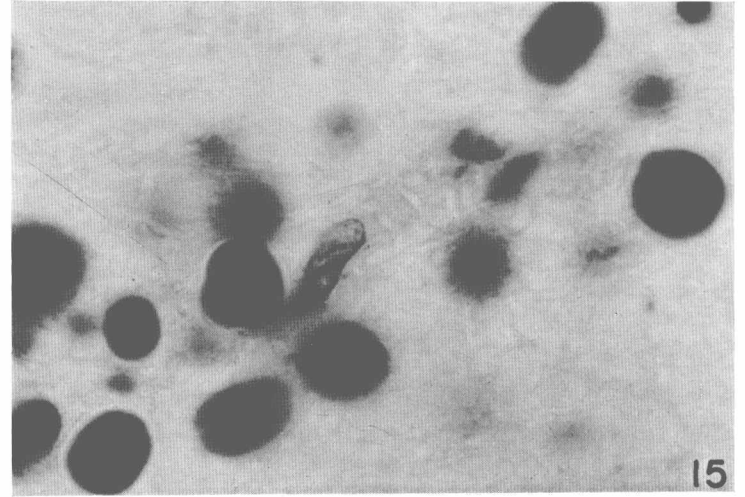
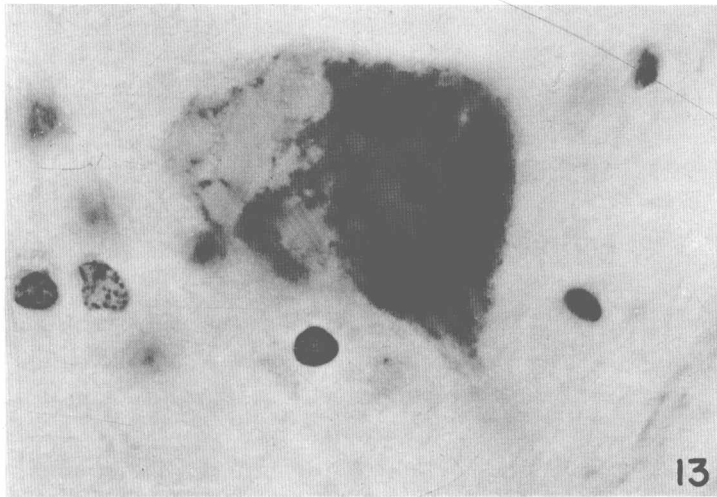
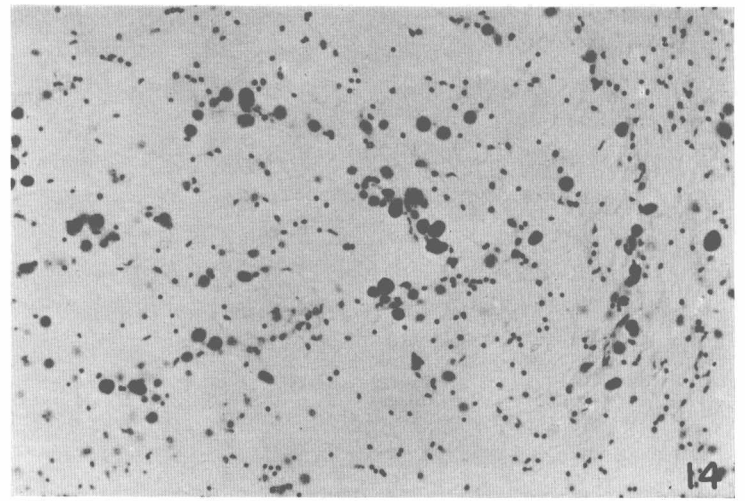
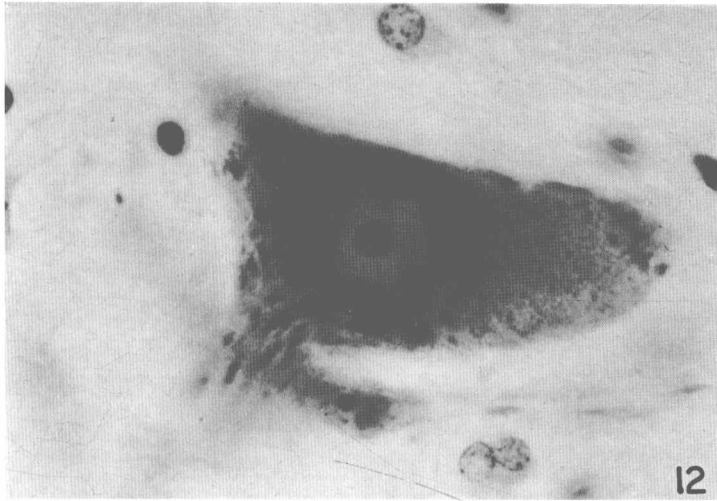


Fig. 12. Nerve cell from the hypoglossal nucleus of a 77-year-old male. Note the accumulation of lipofuscin in the right third of the perikaryon. Mag. 1000 \times .
 Fig. 13. Nerve cell from the abducens nucleus of a 77-year-old male. Note the vacuolization of the perikaryon. Mag. 1000 \times .
 Fig. 14. Amyloid bodies in the posterior funiculi of the medulla of a 75-year-old male. Mag. 150 \times .

Fig. 15. Amyloid bodies. Mag. 1000 \times .
 Figs. 16 to 18. Nerve cells from the inferior olive of a 75-year-old male. Note the accumulation of lipofuscin, the progressive replacement of Nissl substance and the apparent disappearance of the nucleus and nucleolus.

fat solvents such as toluol and benzol. However, it is our impression that, if blocks of nervous tissue are subjected to procedures involving the prolonged use of fat solvents, the lipofuscin may be dissolved out of an occasional cell. This would serve to explain the appearance of vacuolated nerve cells in persons in whom there is no reason to suspect a pathological process (fig. 13). The pattern of distribution of the remaining Nissl substance in such cells remains normal and thus allows their differentiation from cells exhibiting pathological vacuolization.

A further peculiarity of aging nervous tissue is the presence of amyloid bodies (figs. 14 and 15). These are small round structures of unknown constitution and significance. They stain purplish blue in Nissl preparations and usually exhibit a darkly stained central portion surrounded by a more lightly stained halo. Amyloid bodies tend to accumulate particularly in the nervous tissue immediately underlying pial surfaces.

Reticular Formation

The vital importance of the reticular formation of the brain stem has long been recognized on the basis of innumerable observations that interference with the function of this region by stimulation or coagulation produces respiratory, cardiovascular, postural and autonomic responses. Within the past several years even more attention has been focussed on the reticular formation by the observations of Magoun and his associates that by stimulating various areas of the reticular formation they were able either to facilitate or to inhibit cortically or reflexly induced movements. Further, it has been demonstrated that collaterals from all the known sensory systems enter the central core of the brain stem reticular formation and that here a multisynaptic pathway is formed over which impulses are conducted to wide areas of the cortex. On entering this multisynaptic system the sensory impulses are believed to lose their specific modalities. The ascending system from reticular formation to cortex "does not function specifically . . . , but its ascending influences in initiating and maintaining the conscious state provide the necessary background of activity without which no integrated sensory, motor or adaptive function is possible. Moreover, the medial system may be involved in management of gradations of attention superimposed upon inattentive wakefulness" (French, Verzeano and Magoun)¹.

Despite this obvious fundamental physiological significance of the reticular formation, surprisingly little detail is available concerning its morphology. It is

regrettable that the intensive physiological investigations of this region have not stimulated a corresponding degree of anatomical interest. The inadequate information which the anatomist is prepared to offer concerning the reticular formation would serve as poor ground upon which to base the simplest hypothesis, let alone the complicated concepts of modern neurophysiologists.

One need not look far to determine several factors which have contributed to the present lack of knowledge in regard to the anatomical organization of the reticular formation.

Perhaps the most significant of these is the simple fact that the term "reticular formation" represents no precise anatomical concept. To the anatomist the term refers to those areas of a myelin stained section which are characterized by an interlacing network of myelinated fiber bundles, and the "reticular neurones" are those cells which lie between such bundles. Such a definition, however, is actually of very little value for it is most difficult, even on a myelin stained section, to delineate accurately the borders of the reticular formation. And if, by means of a little imagination, one does succeed in accomplishing such a feat, examination of the corresponding Nissl stained section will show, in many instances, that the boundary line has subdivided areas of apparently uniform cytoarchitecture. The study of the myeloarchitecture of such regions as the reticular formation is probably of very little value for purposes of delineation and subdivision of the gray matter. This is due to the fact that innumerable "fibres de passage" obscure the intrinsic fiber pattern which forms the basis for myeloarchitectonic subdivisions.

When the physiologist, on the other hand, speaks of the reticular formation, he is almost invariably referring only to those areas which, on the basis of physiological observations, he knows to be concerned with the fundamental functions referred to above. This is a much more precise and limited concept than that of the anatomist and the two by no means correspond. The lateral reticular nucleus of the medulla, for example, is from the anatomical point of view one of the most reticulated of all the reticular nuclei and yet it has been demonstrated that this nucleus functions predominantly as a relay station in pathways between spinal cord, brain stem and cerebellum. Thus the lateral reticular nucleus falls within the anatomist's but not within the physiologist's concept of a reticular nucleus.

A third factor which has contributed to this confused picture has been the tendency on the part of anatomists to describe and name certain morphologically distinct groups within the reticular formation without prefixing the proper names of such nuclei with the term "reticularis". The nucleus of Roller, the nucleus

¹ French, J. D., M. Verzeano and H. W. Magoun. An extralemniscal sensory system in the brain. *Arch. Neurol. & Psychiat.*, 69: 505-518, 1953.

interfascicularis hypoglossi and the nucleus raphae pallidus, among others, certainly lie within the boundaries of the reticular formation yet rarely if ever does one hear them referred to as reticular nuclei.

A fourth and very important factor which has retarded the anatomical investigation of the reticular formation has been the pessimistic attitude which has prevailed regarding the practical value of any further subdivision of this region. This attitude is the product of two observations. (a) It is apparent even to the casual observer that cells of many different sizes, shapes, staining qualities and Nissl patterns are to be found within the reticular formation and that there appears to be little tendency for cells of a single type to congregate into a compact group. Thus the delineation of the most reticular nuclei is much more difficult than the delineation of cranial nerve nuclei, the majority of which are composed predominantly of morphologically similar cells. (b) It has long been observed that similar physiological responses can be obtained by interfering with the function of widely divergent regions of the reticular formation and that such regions may differ markedly in their cytoarchitecture. Thus the notion has arisen that the cells of many different functional types are intermingled haphazardly throughout the entire reticular formation and that this simple fact renders any attempt to delineate and classify reticular nuclei on the basis of morphological criteria, a waste of time.

Having reviewed the major difficulties in the way of a clear conception of the morphology of the reticular formation, it is well to consider the steps necessary to rectify the situation.

To begin with, an attempt should be made to subdivide the reticular formation into regions of specific cytoarchitecture and to classify all such regions as nuclei. Many nuclei of the reticular formation are easily delineated since they are composed predominantly of compactly arranged cells of a single type. The major part of the reticular formation, however, is populated by loosely distributed cells of more than one type. The subdivision of such areas into nuclei is possible by the application of strict cytoarchitectonic criteria with particular attention paid to the morphological features of the individual cell types and to the general pattern of cell arrangement. For example, region A may be composed of cell types y and z, whereas the neighboring region B may differ only in that cells of type w replace these of type y. We believe that the difference in the morphological patterns of the regions A and B, due to the substitution of cells of type w for those of

type y, is indicative of a difference in functional organization and thus justifies the delineation and classification of such regions as nuclei.

Due to the extreme complexity of organization of the reticular formation, physiological procedures probably elucidate only a part of the total functional significance of any area investigated. It is quite conceivable that regions of different structure may possess common functional properties. However, more detailed physiological investigations of such regions would certainly disclose functional differences as well. It should also be borne in mind that the actual functional organization of the reticular formation may be different from that of current concept. If such proves to be the case, present physiological data will require reinterpretation.

Once a subdivision of the reticular formation is accomplished, the problem of nomenclature must be considered. As mentioned above, the prefix "reticularis" is included in the proper name of many but not of all the nuclei of the brain stem reticular formation. In order to avoid such inconsistencies one should either utilize the prefix in the proper name of each of the reticular nuclei or else avoid it altogether. We believe, for several reasons, that the latter choice is the most practical. First, it is often difficult to decide from a strictly anatomical point of view whether or not a given nucleus lies within the boundaries of the reticular formation. Second, the prefix "reticularis" at the present time carries a physiological implication which is not justified in regard to some nuclei. Third, and most important, since the anatomical and physiological concepts of the reticular formation do not coincide, it would be extremely difficult to consistently utilize the prefix "reticularis" in a manner compatible with both points of view. For these reasons we have decided not to use the prefix "reticularis" in our nomenclature.

Further, it is hoped that once an adequate classification of all nuclei of the brain stem based on their connections and functions is established, the term "reticular formation" will become obsolete. In the meantime, the use of specific names for nuclei, the functions and connections of which remain unknown, should prove helpful in attaining this goal.

Finally, it must be stressed that the subdivision of uncharted regions and the precise delineation of nuclei are only introductory steps in the anatomical investigation of any region. The elucidation of fiber connections is the second step, and one which must precede an adequate understanding of the functional significance of any region.