

主编◎周琳 刘向前 主审◎王小丽

医学组织学 实验指导

(双语版)

Medical Histology Laboratory Manual
(Bilingual edition)



Medical Histology Laboratory Manual
(Bilingual edition)

主编◎周琳 刘向前 主审◎王小丽

医学组织学 实验指导

(双语版)

图书在版编目(CIP)数据

医学组织学实验指导(双语版)/周琳,刘向前主编.
—武汉:湖北科学技术出版社,2012.9

ISBN 978-7-5352-5147-3

I. ①医… II. ①周… ②刘… III. ①人体组织学—
实验—医学院校—教学参考资料 IV. ①R32-33

中国版本图书馆CIP数据核字(2012)第184533号

责任编辑:熊木忠

封面设计:戴 旻

出版发行:湖北科学技术出版社

电 话:027-87679468

地 址:武汉市雄楚大街268号

邮 编:430070

(湖北出版文化城B座13-14层)

网 址:<http://www.hbstp.com.cn>

印 刷:荆州市翔羚印刷有限公司

邮 编:430000

787×1092

1/16

8印张

182千字

2012年9月第1版

2012年9月第1次印刷

定 价:35.00元

本书如有印装问题 可找本社市场部更换

《医学组织学实验指导》

主 编 周 琳 刘向前

主 审 王小丽

编 者 (以姓名拼音为序)

贺 军 李 和 李宏莲 刘胜洪
刘向前 彭 挺 沈建英 汪薇曦
王小丽 杨世明 叶翠芳 张敏海
张亦农 周 琳

编者单位 华中科技大学同济医学院

前言

组织学是研究人体组织结构及这些组织如何组成各个器官的一门课程，其中组织切片的实习在课程中占据举足轻重的地位。在过去几十年的组织学实验教学中，针对中文不同专业的学生和留学生，我们编写了一系列的中文及英文实验课辅助资料，包括实习指导、图谱等。这本综合了实习指导和组织学图谱的双语实验课辅助教材，虽然是第一次正式出版，其实是对我们以往相关实验课教学辅助材料的一个归纳、总结和更新。

本辅助教材的内容包括了四大基本组织和各器官系统的基本结构，及如何在显微镜下对其进行判定，适用于临床医学、预防、法医、口腔、护理、药学等各专业学生的组织学实验。需要注意的是该教材的中英文部分由于中、英文教学的学时不同，侧重点稍异，且由不同教师编写，故内容不完全对应。另外，本教材中的切片编号源自华中科技大学同济医学院组织胚胎学教研室编制的切片号。

在本书的编写过程中，首先感谢历年来我们教过的学生，是他们使我们在实验课教材、教学方法上不断修正，教学相长。感谢本教研室的前辈们对早期相关资料的撰写及对本书的指导和建议。感谢本校外语教研室资深教授洪班信老师对本书英文部分的审阅、修正。

我们希望这本辅助教材能使组织学实验变得轻松。编写中的疏漏之处，敬请批评指正。

Preface

Histology is the study of the tissues of the body and how these tissues are arranged to constitute organs. The lab practice is essential for this course. Through the past few decades of Histology teaching, we have developed a series of practical guides and histologic microphoto gallery for both Chinese and foreign students. This bilingual manual for lab practice, which combines practical guide and microphotoes, though for the first publication, is based on the previous teaching materials.

This lab manual is designed to aid medical students in identifying the various components of each tissue and organ correctly and quickly. It applies to the students majoring in clinical medicine, preventive medicine, forensic medicine, dentistry, nursing, pharmacy, etc. Note: the English part and Chinese part of this book are not always comparable, due to being illustrated from different aspects and being written by different teachers. In addition, the serial number of slices in this manual was originated from the histological slices prepared by the department of Histology and Embryology, Tongji Medical College, Huazhong University of Science and Technology.

For the present manual, we wish to thank the students we have taught, who have helped us in devising our teaching materials and improving our teaching methods. Especially, we would like to give our thanks to our predecessors who produced the original materials and have given us the benefit of their expertise in reading the drafts of this text and suggesting ways we might improve it. Also we are grateful to Mr. Hong, the professor in the English Department of our University for serving as consultant for the English part.

We hope this book will be useful in the students' learning as a genuine laboratory manual and will make the students' lab practice going on smoothly and effectively. Feedback is always welcome.

目 录

Chapter 1

第 1 章 组织学实验方法 Histological experimental method/001

Chapter 2

第 2 章 上皮组织 Epithelial tissue/005

- No.6 单层扁平上皮, 大网膜 Simple squamous epithelium, omentum/005
- No.46 单层扁平上皮, 小肠 Simple squamous epithelium, small intestine/006
- No.46 单层柱状上皮 Simple columnar epithelium/007
- No.54 假复层纤毛柱状上皮 Pseudostratified ciliated columnar epithelium/008
- No.43 未角化复层扁平上皮 Nonkeratinized stratified squamous epithelium/009
- No.60 变移上皮 Transitional epithelium/010

Chapter 3

第 3 章 结缔组织 Connective tissue/011

- No.12 疏松结缔组织, 皮下组织 Loose connective tissue, subcutaneous tissue/011
- No.43 疏松结缔组织, 食管 Loose connective tissue, esophagus/012
- No.13 浆细胞与成纤维细胞 Plasma cell and fibroblast/013
- No.12B 肥大细胞 Mast cell/014
- No.37B 网状纤维 Reticular fiber/015
- No.14 黄色脂肪组织 Yellow adipose tissue/015

Chapter 4

第 4 章 血液 Blood/016

- No.9 血涂片 Blood smear/016

Chapter 5

第 5 章 软骨与骨 Cartilage and bone/018

- No.54 透明软骨 Hyaline cartilage/018
- No.16 弹性软骨 Elastic cartilage/019



- No.17 骨磨片 Ground section of compact bone/020
No.19 软骨内成骨, 长骨 Endochondral ossification, long bone/021

Chapter 6

第6章 肌组织 Muscle tissue/024

- No.20 平滑肌 Smooth muscle/024
No.21 骨骼肌 Skeletal muscle/025
No.22 心肌 Cardiac muscle/026
No.22C 心肌闰盘 Intercalated disk of cardiac muscle/028

Chapter 7

第7章 神经组织和神经系统 Nerve tissue and nervous system/029

- No.23 大脑锥体细胞 Pyramidal cell of the cerebral cortex/029
No.24 小脑蒲肯野细胞 Purkinje cell of the cerebellar cortex/030
No.26 尼氏体 Nissl body/031
No.25 神经原纤维及突触扣结 Neurofibril and synaptic bouton/032
No.27 有髓神经纤维 Myelinated nerve fiber/032
No.28 运动终板 Motor end plate/034
No.56 环层小体和触觉小体 Lamellar corpuscle and tactile corpuscle/035
No.1 脊神经节 Spinal ganglion/036

Chapter 8

第8章 眼和耳 Eye and ear/038

- No.84 眼球 Eyeball/038
No.85 眼睑 Eyelid/043
No.86 内耳 Internal ear/045

Chapter 9

第9章 循环系统 Circulatory system/048

- No.31 中等动静脉 Medium-sized artery and vein/048
No.30 大动脉 Large artery/050
No.30A 大动脉, 醛复红染色 Large artery, aldehyde fuchsin staining/051
No.32 小血管 Small blood vessels/052
No.33 左心壁纵切面 Longitudinal section of left heart/053

Chapter 10

第10章 皮肤 Skin/056

- No.56 手指皮 Skin of the finger/056

No.57 头皮 Scalp/059

Chapter 11

第 11 章 免疫系统 Immune system/062

No.76 胸腺 Thymus/062

No.35 淋巴结 Lymph node/063

No.37 脾 Spleen/066

No.36 腭扁桃体 Palatine tonsil/067

Chapter 12

第 12 章 内分泌系统 Endocrine system/068

No.74 甲状腺 Thyroid gland/068

No.78 肾上腺 Adrenal gland/069

No.77 垂体 Hypophysis/071

No.77A 垂体, 三色法 Hypophysis, Masson's trichrome/074

Chapter 13

第 13 章 消化管 Digestive tract/075

No.43 食管 Esophagus/075

No.44 胃底 Gastric fundus/077

No.45 胃幽门 Gastric pylorus/079

No.46 空肠 Jejunum/080

No.91 十二指肠 Duodenum/082

No.90 回肠 Ileum/083

No.47 结肠 Colon/083

No.48 阑尾 Appendix/084

No.51 潘氏细胞 Paneth cell/084

No.89 小肠绒毛毛细血管 Vascular plexus in intestinal villus/085

Chapter 14

第 14 章 消化腺 Digestive gland/086

No.40 下颌下腺 Submandibular gland/086

No.41 腮腺 Parotid gland/087

No.49 胰腺 Pancreas/088



No.50 肝脏, 猪 Liver, Pig/089

No.50A 肝脏, 人 Liver, Human/091

No.50C 肝巨噬细胞 Kupffer cell/092

No.50B 胆小管 Bile canaliculi/092

Chapter 15

第15章 呼吸系统 Respiratory system/093

No.53 喉 Larynx/093

No.54 气管 Trachea/094

No.55 肺 Lung/095

Chapter 16

第16章 泌尿系统 Urinary system/099

No.58 肾 Kidney/099

No.60 膀胱, 空虚状态 Bladder, non-distended state/103

No.61 输尿管 Ureter/104

Chapter 17

第17章 男性生殖系统 Male reproductive system/105

No.62 睾丸 Testis/105

No.63 附睾 Epididymis/108

No.64 输精管 Ductus deferens/109

No.65 前列腺 Prostate gland/109

No.99 精液涂片 Sperm smear/110

Chapter 18

第18章 女性生殖系统 Female reproductive system/112

No.67 卵巢 Ovary/112

No.68 黄体 Corpus luteum /115

No.69 输卵管 Oviduct/116

No.70 子宫体, 增生期 Body of uterus, proliferative stage/117

No.70A 子宫颈 Uterine cervix/118

No.72 乳腺, 静止期 Mammary gland, inactive state/119

No.71 乳腺, 活动期 Mammary gland, active state/120

第1章 Chapter 1

组织学实验方法

Histological experimental method

(一) 如何正确使用显微镜观察组织标本

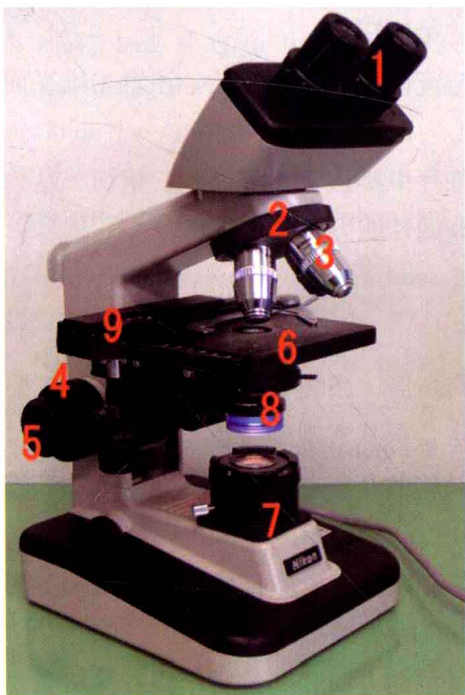


Fig.1-1 显微镜 Microscope

1. 目镜 eyepiece
2. 物镜转换器 nose piece
3. 物镜 objective lens
4. 粗调旋钮 coarse focus
5. 微调旋钮 fine focus
6. 载物台 stage
7. 光源 light source
8. 光阑和聚光器 iris diaphragm and condenser lens
9. 推进器 coaxial stage controls

1. 对照图片，结合实物，熟悉显微镜的构件。
2. 将显微镜轻轻地移至观察者的前方，使镜座的后缘距实验台边缘大约 10 cm。
3. 旋开显微镜电源开关，并使光线亮度适当。
4. 旋转物镜转换器，将 10 倍物镜旋至镜筒下方，对准载物台中央的孔。
5. 打开聚光镜孔径光阑，可见光线经聚光器→载物台中央的孔→10 倍物镜→目镜。
6. 注意身体坐姿，睁开双眼，把观察注意力集中于显微镜的视场内，可见两个不完全重合的视场光斑，双手推移两目镜，使两光斑合二为一。
7. 按照实习指导和切片标本目录，从标本盒内取出要观察的标本，进行肉眼观察，



初步了解该标本的大小、形状和染色等。

8. 将载玻片放在载物台上，盖玻片朝上，标签位右侧，用切片夹夹好。旋转推进器移动旋钮，将载玻片上的组织标本移至物镜下方。调节电源开关，将视野亮度调至适中。在右手旋转推进器移动旋钮移动切片的同时，左手慢慢地旋转粗调旋钮和微调旋钮聚焦（先旋粗调旋钮，后旋微调旋钮）。因推进器位置在不同显微镜可能不同，左右手分工可能互换。

9. 显微观察标本常规是从低倍放大开始，这样视场大，有利于对标本进行全面观察。使用低倍物镜时，观察者左手转动粗调旋钮，使载物台缓慢上升或下降，同时，观察者用双眼从目镜中观察视场，当见到组织标本像轮廓时，转动微调旋钮直至组织标本像清晰。

10. 当要进一步放大观察时，则直接旋转物镜转换器，将更高倍物镜（如4倍转成10倍，或10倍转成40倍）旋至镜筒下方。此时，只需转动微调旋钮调焦（必要时升降聚光器或调节聚光镜光阑的孔径），便可获得更清晰的进一步放大的标本像。在不同切片和不同放大倍数下观察时，应注意随时调节亮度，使之最适宜。

11. 移动切片观察时，要注意片中组织标本与镜像方位完全相反。注意二维平面标本像与其三维立体图像的关系。

12. 观察完一张切片后，应回忆总结一下在该片中辨认了几种细胞、组织、结构或该器官的特征性结构，每片如此积累，可以大大提高阅片能力和学习效率。

（二）如何观察和理解切片物像

观察切片的步骤 应养成由肉眼到低倍，再到高倍，系统观察标本的习惯。先要了解标本的取材部位、制片方法、切片方位和染色方法，再从宏观到微观，由浅入深逐步观察组织、细胞的微细结构。在掌握组织、细胞光镜结构的基础上，可结合观察某些细胞或结构的电镜照片，并联系机能融会贯通深入理解。

正确理解切片的立体形象 人体结构极为复杂，就同一个器官或细胞来说，所切的部位不同或者所切的方向不同，则切片所显示的物像就不相同。

我们将一个煮熟的鸡蛋示意为一个细胞，通过不同方向和部位所作的各种切面，则可得不同的物像，如 Fig.1-2 所示。若对呈辐射状排列的细胞群体作各种切面，其各种物像如 Fig.1-3 所示。若对呈管状的器官作各种切面，其形状如 Fig.1-4、Fig.1-5 所示；若对呈束状的器官作各种切面，其形状如 Fig.1-6 所示。

切片中的人为现象 在切片中出现的一些人为假象，并非组织结构，应予鉴别：①刀痕：因切片刀锋有缺口造成组织标本纵行刀痕。②裂纹：组织透明、浸蜡的时间过长，组织脆硬，切片时可引起组织裂开，呈不规则裂纹。在制片过程中，由于组织或细胞各部分结构的收缩不一致，或贴片时水温过高，也可导致某些人为裂隙。③皱褶：贴片时组织未充分展平。④气泡：封片时将少许空气封入切片树胶中。⑤异留物：如染色时残留的染料沉渣等。

I. How to use a microscope to examine the slides

Step 1. Locate each part of your microscope according to the above image.

Step 2. Check the glass slides in the box and inform the teacher if there is any one broken or missing.

Step 3. Procedure for examination of the slides using the microscope

A. Gently move the microscope towards you, keeping the distance of about 10 cm between the rim of microscope base and your bench edge.

B. Turn on the power switch, make sure that your light source is functioning, and ensure that the lens nosepiece is rotated properly and the 10X objective lens is fixed.

C. Hold the slide up and examine it first with the naked eye to get an overview of the tissue size, shape and placement on the slide.

D. Put the slide on the stage and fasten it with the stage clip.

E. Look at the stage from the side and turn the coarse focus knob so that the stage goes upward. Move it as close as possible to the objective lens, without touching it!

F. Now, look through the eyepiece, meanwhile turn the coarse knob so that the stage moves away from the objective lens. Continue until the image comes into focus. Then use the fine knob for fine focusing.

G. Move the interesting image in the center of the field of view, then change to the 40X objective lens for further observation.

II. How to examine and understand microscopic images

Tips for examination:

1. Observe the section with naked eyes first for orientation and then at the lower magnification, and increasingly higher magnifications.

2. Be familiar with the sampling site and staining method, which is helpful in understanding the structure.

3. Electron micrograph available in the lab is valuable in connecting the morphology with function of some cells and tissues.

Transition from 3D to 2D:

When viewing a histological sample or specimen, you have to bear in mind that the tissue has been reduced from being three-dimensional to two-dimensional. You are no longer viewing a full specimen or even the exterior of a specimen, but rather a sliver of tissue taken from a specimen.

The following diagrams demonstrate various sectional shapes of a tissue sample cut from different orientations.

Artifacts:

Be aware that each step of tissue preparation introduces artifacts by altering or distorting the natural appearance of cells. Artifacts in slides may result from improper fixation and dehydration, paraffin infiltration, and poor microtome sectioning.

1. Bubbles: The air is sucked in under the coverslip when the mounting media is too

thin or dries off.

2. Black precipitates: Formalin-heme pigment forms when the formalin buffer is exhausted and the tissue becomes acidic.

3. Ripples and wrinkles: They can be introduced during cutting and handling of sections when the tissue section stretches unevenly around structures of differing consistencies.

4. Scratches and "chatter": Scratches are caused by flaws or dirt on the cutting edge, and appear as straight slashes or ragged tears across the specimen. "Chatter" is the visible record of knife vibration. The process of slicing sometimes induces vibrations in the knife edge, which then cause variations in thickness in the section. These appear as narrow parallel bands, usually evenly spaced, across a tissue specimen.

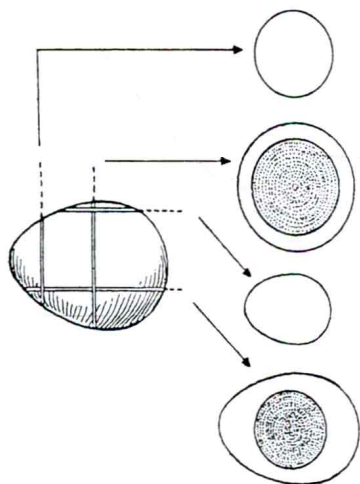


Fig.1-2 鸡蛋的各种断面
sections of an egg

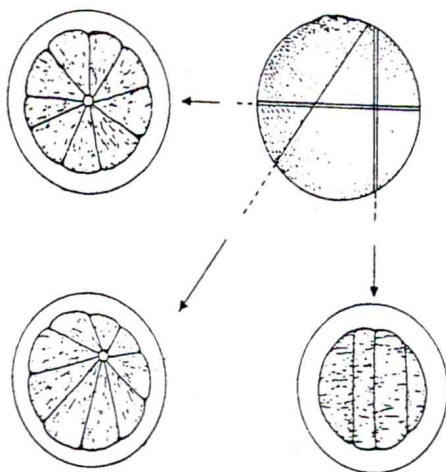


Fig.1-3 辐射状排列的细胞群的各种断面
sections of the radiate shaped cell clusters

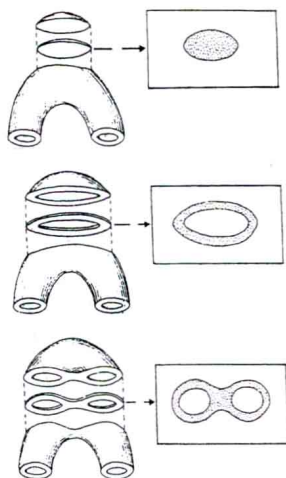


Fig.1-4 弓形管状结构的各种断面
sectional shapes of
arched tubular frame

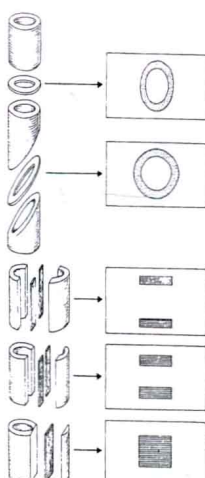


Fig.1-5 管状器官的各种断面
sectional shapes of
tubular organs

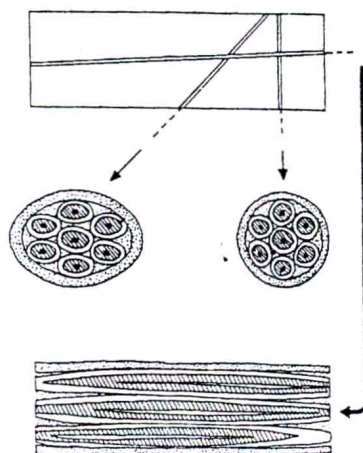


Fig.1-6 束形器官的各种断面
sectional shapes of
bunched organs

第2章 Chapter 2

上皮组织

Epithelial tissue

No.6 单层扁平上皮 Simple squamous epithelium

大网膜铺片，兔，银染法 Spread preparation of omentum, rabbit, silver staining

取动物大网膜经硝酸银浸染，剪成小块平铺于载玻片上而制成。用其观察单层扁平上皮的正面形态结构。

〔4 倍物镜〕选择大网膜铺成单层，且背景较清楚的部分观察。

〔10 倍物镜〕上皮细胞呈不规则形或多边形，相邻细胞之间有棕黑色的硝酸银颗粒沉积。

〔40 倍物镜〕细胞之间的硝酸银颗粒较大且多，故着色深；胞质内的硝酸银颗粒细小而分散。细胞核呈椭圆形，着蓝色（苏木素复染）。

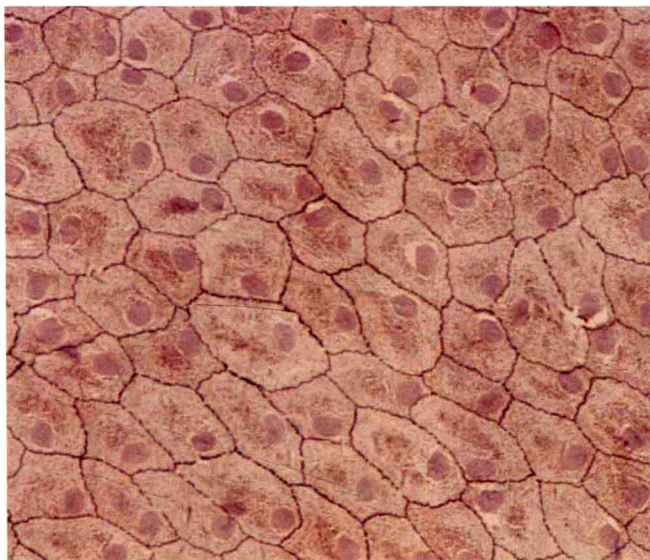


Fig.2-1 单层扁平上皮 simple squamous epithelium

In this preparation, the mesothelial lining of the peritoneal cavity has been stripped from the underlying connective tissues and spread onto a slide thus permitting a surface view of simple squamous epithelium.

Low and high power: Simple squamous epithelium (the mesothelium) is observed with surface view. The intercellular substance has been stained with silver outlining the closely interdigitating cell boundaries. The nuclei of the cells are centrally or eccentrically located, which have been stained with the dye, hematoxylin.

No.46 单层扁平上皮 Simple squamous epithelium

小肠, 狗 Small intestine, dog, H&E

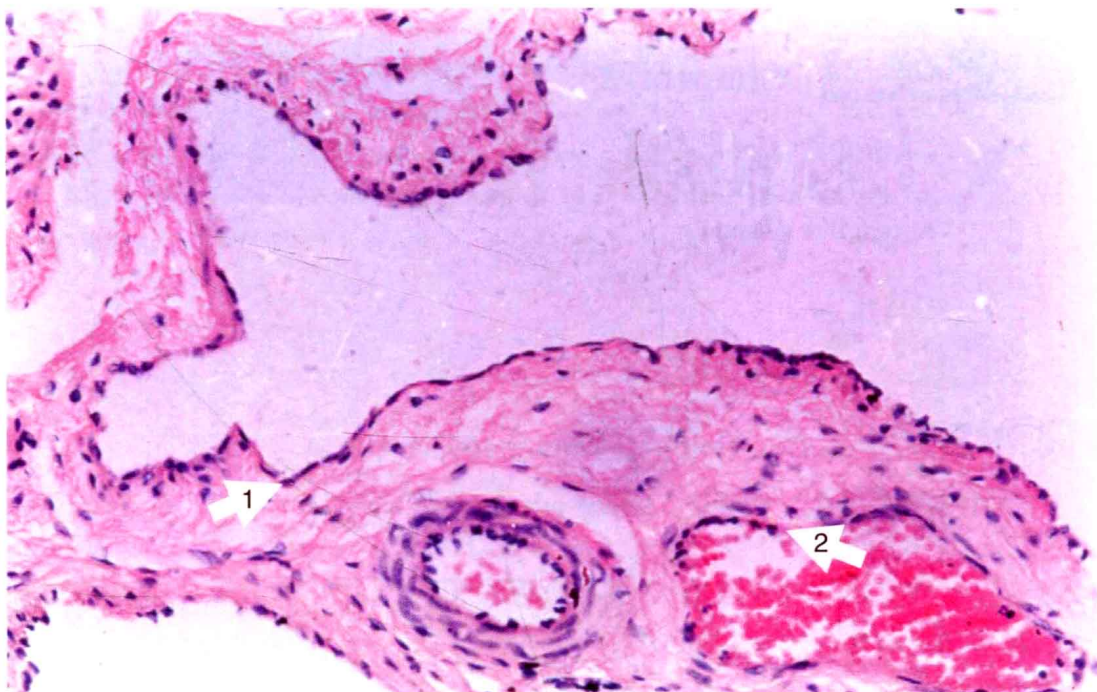


Fig.2-2 单层扁平上皮 simple squamous epithelium

1. 间皮 mesothelium
2. 内皮 endothelium

[4 倍物镜] 呈指状突起的一面为小肠黏膜, 与其相对的另一面是小肠的腹腔面, 被覆单层扁平上皮。

[10 倍物镜] 在切片的边缘有一条弯曲, 且着浅红色的细带, 为单层扁平上皮的侧面观, 其内断续的紫蓝色的点状结构, 此即单层扁平上皮细胞核。选细胞核较多、排列较整齐的部位, 换 40 倍物镜进一步观察。

[40 倍物镜] 单层扁平上皮的侧面观, 其细胞核呈扁椭圆形或卵圆形, 胞核的长轴与上皮的表面平行。因上皮细胞呈薄片状, 故仅见胞核周围少量的嗜酸性胞质。

Naked eye: The wave-like violet band is the intestinal mucosa. The opposite margin is the outer surface of the small intestine covered by the simple squamous epithelium, called mesothelium.

Low and high power: The mesothelial lining cells are so flattened that they can only be recognized by their nuclei which are basophilic and bulge into the lumen. The supporting basement membrane is very thin and can not be seen in this micrograph. In the underlying connective tissue, another type of simple squamous epithelium, called endothelium, can be found to line some small blood vessels.

No.46 单层柱状上皮 Simple columnar epithelium

小肠, 狗 Small intestine, dog, H&E

〔4 倍物镜〕这是空肠的纵切面组织切片, 平坦的一边是空肠的外表面, 即腹腔面; 有大小指状突起的一边是空肠的内表面, 即肠腔面, 其表面被覆单层柱状上皮。

〔10 倍物镜〕指状突起表面所被覆的组织是单层柱状上皮, 细胞核呈长椭圆形或杆状, 众多的细胞核紧密排列成一层。有些部位的上皮细胞核聚集成堆或排成多层, 此因该处众多的上皮细胞被斜切所致。少数细胞核上部的胞质呈圆形或椭圆形空泡状, 该细胞为杯状细胞。选择细胞核排列成单层的部位, 换 40 倍物镜观察。

〔40 倍物镜〕小肠单层柱状上皮的游离面有一条红色的带状结构, 称纹状缘。柱状的上皮细胞紧密排列成一层, 细胞间的界限有的不清楚。但是, 可根据细胞核呈长椭圆形或长杆状, 并排列为一排, 即可推断该上皮是由单层的柱状细胞组成 (一般而言, 细胞核的形态是与该细胞的形状相对应的)。细胞核的长轴与细胞的长轴一致, 偏居细胞的基底部。柱状的上皮细胞间可见杯状细胞, 其外形似高脚酒杯, 细胞核上部的胞质内, 有个圆形或椭圆形的空泡区 (此因该处胞质内的粘原颗粒在制片过程中被溶解, 致使颗粒所在区着色很浅); 细胞游离面的纹状缘中断; 细胞核常呈三角形或杆状, 着深蓝色, 位于细胞基底部。

Naked eye: The violet band is the intestinal mucosa.

Low power: Find out finger-like projections (villi) on the mucosa side. The surface of villi is covered by simple columnar epithelium, in which tightly compacted nuclei can be seen in one layer.

High power: Two kinds of cells are present in this epithelium. Columnar cell has an oval nucleus with its long axis paralleling to the long axis of the cell. The luminal plasma membranes of columnar cells are often arranged into numerous, minute, finger-like projections called microvilli which are too small to be resolved individually. But the microvilli collectively give the appearance of a striated border at the luminal surface. Between the columnar cells, goblet cell is irregularly distributed and shows a vacuole feature with a dark nucleus below the vacuolar cytoplasm.

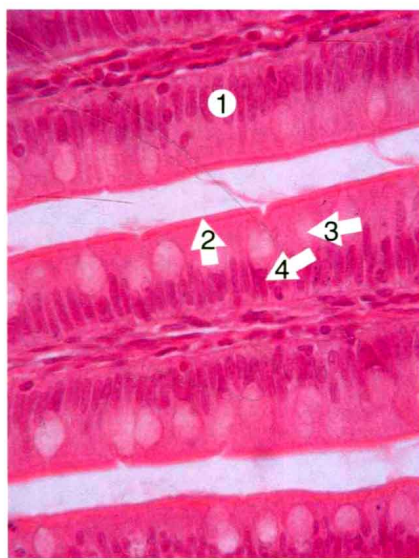


Fig.2-3 单层柱状上皮 simple columnar epithelium
1. 单层柱状上皮 simple columnar epithelium
2. 纹状缘 striated border
3. 杯状细胞 goblet cell
4. 杯状细胞核 nucleus of goblet cell



No.54 假复层纤毛柱状上皮 Pseudostratified ciliated columnar epithelium

气管, 人 Trachea, human, H&E

[4 倍物镜] 气管横切面的组织切片, 呈半环形或环形, 凹面 (气管腔面) 被覆假复层纤毛柱状上皮。

[10 倍物镜] 沿气管腔面观察, 假复层纤毛柱状上皮的细胞核密集排列成数层, 染成蓝色。选择层次结构较清晰的部位, 换 40 倍物镜观察。

[40 倍物镜] 上皮细胞界限不清, 游离面有呈簇或成排的浅红色细丝, 即纤毛。纤毛所在的细胞, 为纤毛细胞, 呈柱状, 该细胞上半部呈柱状, 下半部纤细; 细胞核呈椭圆形, 位于多层上皮细胞核的浅层。纤毛细胞间常有杯状细胞。深层的细胞核多呈圆形, 胞质甚少且不清楚, 此即锥体形细胞。其他的细胞多数是梭形细胞, 细胞核圆形, 位于成层排列的胞核的中间层。常见浸入上皮内的小淋巴细胞, 其核小而圆, 着色很深。上皮基部的基膜, 着淡红色, 呈细线状, 有时不明显。

Naked eye: The inner surface is purple and lined with epithelium.

Low power: The term pseudostratified is derived from the appearance of this epithelium in section which conveys the erroneous impression that there is more than one layer of cells. This, however, is a true simple epithelium since all the cells rest on the basement

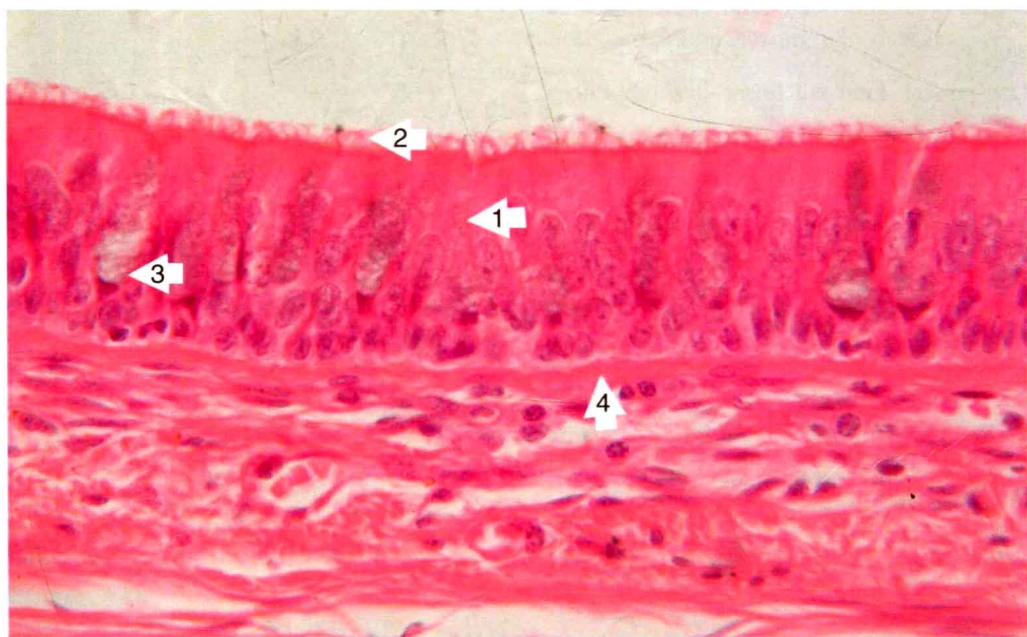


Fig.2-4 假复层纤毛柱状上皮 pseudostratified ciliated columnar epithelium

1. 假复层纤毛柱状上皮 pseudostratified ciliated columnar epithelium
2. 纤毛 cilia
3. 杯状细胞 goblet cell
4. 基膜 basement membrane