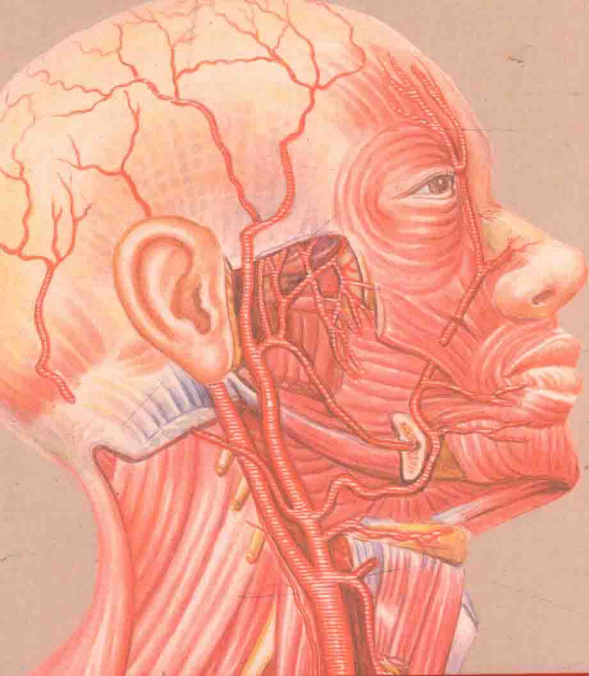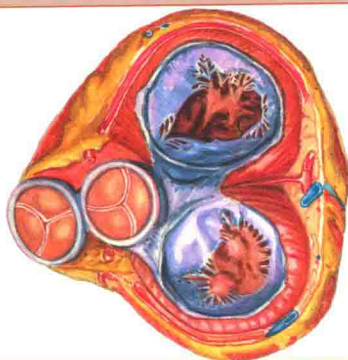
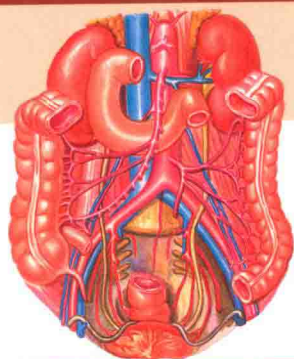


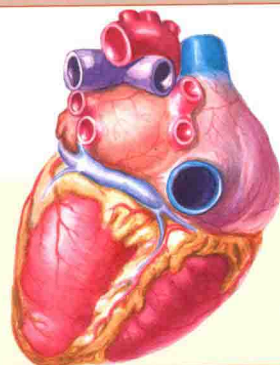


Dynamic
Color Atlas of
Human Anatomy

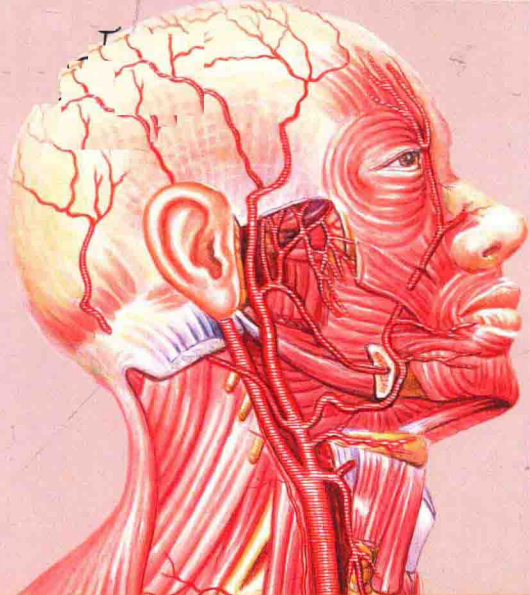
动画感人体解剖学
彩色图谱



主 审 侯明晓 陈 禹
主 编 幸健华 孟威宏

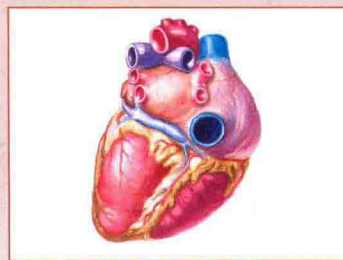
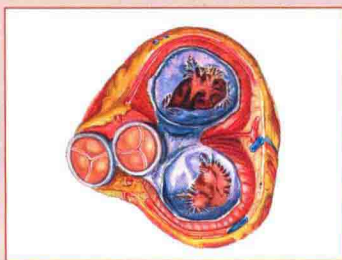
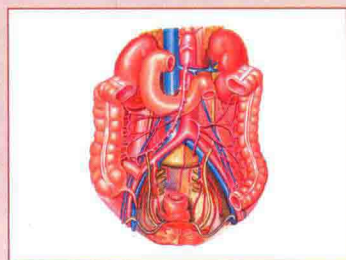


人民卫生出版社



Dynamic
Color Atlas of
Human Anatomy

动画感人体解剖学
彩色图谱



主 审 侯明晓 陈 禹
主 编 幸健华 孟威宏

人民卫生出版社

图书在版编目 (CIP) 数据

动画感人体解剖学彩色图谱 / 幸健华, 孟威宏主编. —北京: 人民卫生出版社, 2014

ISBN 978-7-117-19270-5

I. ①动… II. ①幸… ②孟… III. ①人体解剖学-图谱-医学院校-教材 IV. ①R322-64

中国版本图书馆 CIP 数据核字 (2014) 第 131688 号

人卫社官网	www.pmph.com	出版物查询, 在线购书
人卫医学网	www.ipmph.com	医学考试辅导, 医学数据库服务, 医学教育资源, 大众健康资讯

版权所有, 侵权必究!

动画感人体解剖学彩色图谱

主 编: 幸健华 孟威宏

出版发行: 人民卫生出版社 (中继线 010-59780011)

地 址: 北京市朝阳区潘家园南里 19 号

邮 编: 100021

E - mail: pmph@pmph.com

购书热线: 010-59787592 010-59787584 010-65264830

印 刷: 北京盛通印刷股份有限公司

经 销: 新华书店

开 本: 889×1194 1/16 印张: 16

字 数: 666 千字

版 次: 2015 年 2 月第 1 版 2015 年 2 月第 1 版第 1 次印刷

标准书号: ISBN 978-7-117-19270-5/R · 19271

定 价: 89.00 元

打击盗版举报电话: 010-59787491 E-mail: WQ@pmph.com

(凡属印装质量问题请与本社市场营销中心联系退换)

编委会名单

主 审

侯明晓 陈 禹

主 编

幸健华 孟威宏

副 主 编

仲怀春(沈阳军区总医院)

康万军(解放军第 463 医院)

尹忠民(解放军第 463 医院)

于 明(沈阳军区总医院)

王锦绣(大庆医学高等专科学校)

刘洪涛(大庆医学高等专科学校)

林雪松(大庆医学高等专科学校)

谢爱国(沈阳军区空军后勤部飞行体检中心)

任 旷(吉林医药学院)

郑 飞(沈阳军区总医院)

姚天明(沈阳军区总医院)

关双成(解放军第 463 医院)

李东文(解放军第 463 医院)

薛 强(解放军第 463 医院)

杨志鸣(解放军第 463 医院)

德 琳(解放军第 463 医院)

马湘乔(解放军第 463 医院)

沈 涛(解放军第 463 医院)

萧洪文(泸州医学院)

牛松青(吉林医药学院)

李祥鹏(吉林医药学院)

李万同(沈阳军区总医院)

李 雷(吉林医药学院)

常洪贤(吉林医药学院)

邵 兵(沈阳军区总医院)

马英恒(解放军第 463 医院)

杨柏松(解放军第 463 医院)

吴 静(解放军第 463 医院)

编 委

廖 威(解放军第 463 医院)

李春田(解放军第 463 医院)

李岩松(解放军第 463 医院)

姜泰茂(解放军第 463 医院)

马敬超(解放军第 463 医院)

赵 雷(解放军第 463 医院)

陈拥贵(解放军第 463 医院)

龙 岩(解放军第 463 医院)

王 雷(解放军第 463 医院)

王忠华(沈阳医学院)

王 静(沈阳军区总医院)

王聿杰(沈阳军区总医院)

王 伟(吉林医药学院)

王玉孝(厦门医学高等专科学校)

邵旭辉(解放军第 463 医院)

杨光照(沈阳军区总医院)

隋 艺(解放军第 463 医院)

赵丹丹(解放军第 463 医院)

季瑞芳(沈阳军区总医院)

崔海洋(沈阳军区总医院)

崔 燃(解放军第 463 医院)

吕红梅(解放军第 463 医院)

彭 东(吉林医药学院)

刘 颖(解放军第 463 医院)

刘卫华(成都医学院)

刘 洋(吉林医药学院附属医院)

刘秀玲(吉林省白山中医院)

房修桐(解放军第 463 医院)

刘秀茹(吉林医药学院附属医院)

刘学成(吉林医药学院)

杨贵将(解放军第 463 医院)

孙 雪(解放军第 463 医院)

张蕃已(广东省顺德龙江医院)

李 溪(沈阳军区大连疗养院)

许冬明(吉林医药学院)

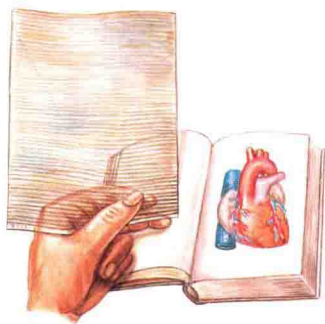
韩 锋(吉林医药学院)

动画感图产生动感效果是由“光栅动片”和“动感图”两者结合产生的。每部图谱都附有一张透明片基,它上面印有平行且粗细均匀的黑色线条,我们称此片为“光栅动片”;目录中凡标有※号的图称为“动感图”。将“光栅动片”取出,覆盖在“动感图”上(图1),匀速、缓慢向下方拉动“光栅动片”(图2),“动感图”便产生向不同方向流动的动画感。“光栅动片”覆盖在没有标※号的图上是不会产生动感的。动感效果的好坏和内容正确与否须注意以下三点:

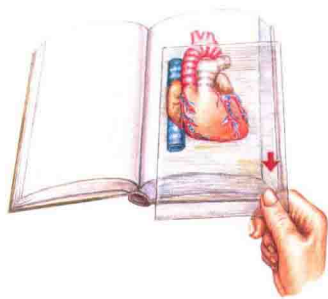
(1) “光栅动片”覆盖在“动感图”上的线条方向一定是横向平行,竖直方向则根本不能产生动感,斜向则动感效果不佳或不正确。

(2) “光栅动片”在“动感图”上的拉动或移动方向必须向下,向上也能产生动感,但动感效果与结构内容相反。

(3) 向下拉动“光栅动片”时,须匀速、缓慢进行,否则动感效果不佳。另外,务必保存和保护好“光栅动片”,没有“光栅动片”“动感图”是不能产生动感的,划伤“光栅动片”会降低其透明度而影响动感效果。如果“光栅动片”不慎丢失,可来函到出版社另行邮购。



(图1)



(图2)

序

作为人体解剖学园地中的一位老园丁,我深情地关注着这个园地里的一花一草,一树一木。解剖学图谱,是这个园地里占有重要地位的一角,曾经孕育过许多五彩纷呈、格调清新的奇葩异果,美不胜收。争奇斗艳的图谱各具特色,或以绘图艺术见长,或以设计巧妙取胜。但是,迄今为止,还没有一部图谱能超凡脱俗,使静态的图像,产生动感效果。

“高楼晓见一花开,便觉春光四面来”,当幸健华、孟威宏老师将《动画感人体解剖学彩色图谱》展现在我眼前时,用简易的“光栅动片”轻轻地一拉,“一波才动万波随”,波澜起伏的血液运转、淋巴返流、原尿滤过、神经传导等,韵味无穷,栩栩如生,让人大开眼界,大饱眼福,从中领悟到人体形态与功能水乳交融的奥秘。

“行成于思,业精于勤”,动态图谱创作人能从看似平常并不起眼的现象中,独具慧眼,找到了美妙的闪光亮点。从两把格尺重叠互动的效应,找到光学中光栅运动的理论依据。结合多年解剖学教学实践体会,精心设计,经过绳锯木断、水滴石穿的奋斗过程,终于荣获国家发明专利,形成了“独留巧思传千古”的新风格,难能可贵,可喜可贺,并欣之为序。

中国工程院院士
中国解剖学会名誉理事长



2014年12月于广州

前言

笔者曾从事人体解剖学教学 20 余年,在教学实践中深感一本好的图谱对学生学习解剖学的重要性。市面上的人体解剖学图谱很多,但如何在图谱中实现形象教学与启发教学,以调动学生的学习兴趣,达到事半功倍的学习效果,一直是笔者苦苦思索并力求有所突破的问题。

在解剖学教学工作中,为了形象生动地展示血液流动等,笔者曾经做了很多的尝试,研制了多种教具,一直都不太理想。直到一个偶然的机,经专家指点,开始运用光学中光栅的原理与线行运动的数学方程结合研究如何用光学投影实现动态显示,并获得了发明专利——具有动画感的卡通式图(专利号:ZL96445355.5,国际专利主分类号:B44F1/06)。在此基础上,结合笔者多年的手绘解剖图经验的积累,尝试着在手绘图中实现动态显示,终于取得了突破,呈现给读者的《动画感人体解剖学彩色图谱》就是这一突破的具体成果。笔者用 5 年时间潜心绘制了近 1000 幅解剖图,从中反复修改、优化并精选出 501 幅汇成本书,其中有 418 幅不动图和 83 幅具有流动、扩散、旋转等动画效果的动画感图。

《动画感人体解剖学彩色图谱》遵照国家高等医学院校解剖教学大纲的要求,按照人体九大系统划分,采用统编教材章节排序,充分展示系统中各个器官正常形态结构特点与其部分生理功能。为使图谱画面精美严谨、结构名称标准规范,绘编时不仅参照大量标本模型,而且查阅了中外多部专著,力求形态层次分明、结构准确无误,结构名称全部标有中、英文对照,希望能够满足广大临床医护工作者和医学院校学生对解剖学知识的需求。

动画感图能形象地模拟血液循环流动感、神经传导运动感、原尿生成滤过吸收等动画效果,既新颖逼真,又栩栩如生,故称“动画感”图谱。为了不破坏解剖系统编排的完整性,“动画感”图分别穿插在各系统章节之中;为了便于区分和辨识动、静图,凡是“动画感”图均在下方图目后标注“※”标识,此标识在目录中也都分别标注,便于读者查找。

“动画感”图产生动画效果是需要您利用书中附带的“动片”,贴放在“※”标识的图片上,均速、缓慢、平行向下拉动,即可出现。操作很简单,您也可以阅读本书中所附“动画感图操作使用说明”,很快就能正确掌握操作方法了。同时,希望您保护和保管好“动片”,因为,一本图谱只需用

1 张也只夹带 1 张“动片”，划痕和折伤都会影响“动片”的透光度，进而影响动画效果。

本书在编制和出版中，得到了解剖学前辈钟世镇院士、柏树令教授、张昆教授、本书编写团队及人民卫生出版社编辑老师的关心、帮助和支持，现将付梓，实现了笔者多年梦想，在此深表感谢！

由于水平有限，专利成果用于出版有待同行检视，疏漏之处敬请前辈与同行多加斧正，不胜感激。

幸健华 孟威宏
2014 年 12 月

运动系统 LOCOMOTOR SYSTEM001

1. 人体骨骼(前面观) The human skeleton (anterior aspect).....	002
2. 人体骨骼(后面观) The human skeleton (posterior aspect).....	003
3. 骨的构造 Structure of the bones.....	004
4. 脊柱(前面观) The spinal column (anterior aspect).....	005
5. 脊柱(后面观) The spinal column (posterior aspect).....	005
6. 脊柱(外侧面观) The spinal column (lateral aspect).....	005
7. 颈椎的形态 The morphology of the cervical vertebrae.....	006
8. 胸椎的形态 The morphology of the thoracic vertebrae.....	006
9. 腰椎的形态 The morphology of the lumbar vertebrae.....	006
10. 骶骨(前面观) The sacrum (anterior aspect).....	007
11. 尾骨(前面观) The coccyx (anterior aspect).....	007
12. 骶骨(后面观) The sacrum (posterior aspect).....	007
13. 尾骨(后面观) The coccyx (posterior aspect).....	007
14. 颅(前面观) The skull (anterior aspect).....	008
15. 新生儿颅(上面观) The skull of a newborn infant (superior aspect).....	008
16. 颅(外侧面观) The skull (lateral aspect).....	009
17. 新生儿颅(外侧面观) The skull of a newborn infant (lateral aspect).....	009
18. 颅底(外面观) The base of the skull (external aspect).....	010
19. 颅底(内面观) The base of the skull (internal aspect).....	011
20. 颅(正中矢状切面) The skull (median sagittal section).....	012
21. 颅(上面观) The skull (superior aspect).....	012
22. 颅(后面观) The skull (posterior aspect).....	012
23. 头颈部骨架(侧面观) Bony framework of head and neck (lateral aspect).....	013
24. 骨性鼻腔外侧壁(1) The lateral wall of the bony nasal cavity (1).....	014
25. 骨性鼻腔外侧壁(2) The lateral wall of the bony nasal cavity (2).....	014
26. 颅冠状切面(前面观) Coronary section of the skull (anterior aspect).....	014
27. 下颌骨(外侧面观) The mandible (lateral aspect).....	014
28. 舌骨 The hyoid bone.....	014
29. 额骨(前面观) The frontal bone (anterior aspect).....	015
30. 额骨(下面观) The frontal bone (inferior aspect).....	015
31. 颞骨(外面观) The temporal bone (external aspect).....	015
32. 颞骨(内面观) The temporal bone (internal aspect).....	015
33. 蝶骨(前面观) The sphenoid bone (anterior aspect).....	016
34. 蝶骨(后面观) The sphenoid bone (posterior aspect).....	016
35. 枕骨和蝶骨(上面观) The occipital bone and sphenoid bone (superior aspect).....	016
36. 腭骨(后面观) The palatine bone (posterior aspect).....	016
37. 腭骨(内面观) The palatine bone (internal aspect).....	016
38. 筛骨(下面观) The ethmoid bone (inferior aspect).....	017
39. 筛骨(后面观) The ethmoid bone (posterior aspect).....	017
40. 上颌骨(外面观) The maxilla (external aspect).....	017
41. 上颌骨(内面观) The maxilla (internal aspect).....	017
42. 右上肢骨(前面观) The bones of the right upper limb (anterior aspect).....	018
43. 肩和肘部骨的肌肉附着点(前面观) Bony attachments of muscles of shoulder and elbow (anterior aspect).....	018
44. 肩和肘部骨的肌肉附着点(后面观) Bony attachments of muscles of shoulder and elbow (posterior aspect).....	018
45. 右锁骨(上面观) The right clavicle (superior aspect).....	019
46. 右锁骨(下面观) The right clavicle (inferior aspect).....	019
47. 右肩胛骨(前面观) The right scapula (anterior aspect).....	019
48. 右肩胛骨(后面观) The right scapula (posterior aspect).....	019
49. 肱骨(前面观) The humerus (anterior aspect).....	020
50. 肱骨(后面观) The humerus (posterior aspect).....	020
51. 桡骨和尺骨(前面观) The radius and ulna (anterior aspect).....	021
52. 桡骨和尺骨(后面观) The radius and ulna (posterior aspect).....	021
53. 手骨(掌侧面) The bones of the hand (palmar aspect).....	022
54. 手骨(背侧面) The bones of the hand (dorsal aspect).....	022
55. 右下肢骨(前面观) The bones of the right lower limb (anterior aspect).....	023
56. 髋和大腿部骨的肌肉附着点(前面观) Bony attachments of muscles of hip and thigh (anterior aspect).....	023
57. 髋和大腿部骨的肌肉附着点(后面观) Bony attachments of muscles of hip and thigh (posterior aspect).....	023

58. 髌骨(内面观) The hip bone (internal aspect).....	024
59. 髌骨(外面观) The hip bone (external aspect).....	024
60. 男性骨盆(上面观) Male pelvis (superior aspect).....	024
61. 股骨(前面观) The femur (anterior aspect).....	025
62. 股骨(后面观) The femur (posterior aspect).....	025
63. 髌骨(前面观) The patella (anterior aspect).....	026
64. 髌骨(后面观) The patella (posterior aspect).....	026
65. 胫骨和腓骨(前面观) The tibia and fibula (anterior aspect).....	026
66. 胫骨和腓骨(后面观) The tibia and fibula (posterior aspect).....	026
67. 足骨(背面观) Bones of the foot (dorsal aspect).....	027
68. 足骨(跖面观) Bones of the foot (plantar aspect).....	027
69. 椎骨间连结(正中矢状切面) The intervertebral joints (median sagittal section).....	028
70. 椎骨间连结(前面观) The intervertebral joints (anterior aspect).....	028
71. 椎间关节和椎间盘(水平切面) The intervertebral joint and intervertebral disc (horizontal section).....	028
72. 椎骨的连结(左外侧面观) Intervertebral joints (left lateral aspect).....	028
73. 椎骨的连结(后面观) Intervertebral joints (posterior aspect).....	028
74. 第二颈椎到第一胸椎(右侧面观) 2nd cervical to 1st thoracic vertebrae (right lateral aspect).....	029
75. 上部颈椎(后上面观) Upper cervical vertebrae (posterosuperior aspect).....	029
76. 寰枕和寰枢关节(后面观) The atlantooccipital joint and atlantoaxial joint (posterior aspect).....	029
77. 颅与颈椎的连结(前面观) The craniocervical vertebrae joints (anterior aspect).....	029
78. 颅与颈椎的连结(后面观) The craniocervical vertebrae joints (posterior aspect).....	029
79. 项韧带(右侧面观) Ligamentum nuchae (right lateral aspect).....	029
80. 第二肋 Second rib.....	030
81. 第一肋 First rib.....	030
82. 第七肋 Seventh rib.....	030
83. 胸骨(前面观) The sternum (anterior aspect).....	030
84. 第一胸肋软骨结合 The first sternocostal synchondrosis.....	030
85. 胸廓(前面观) The thorax (anterior aspect).....	031
86. 肩关节(前面观) The shoulder joint (anterior aspect).....	031
87. 肩关节(内面观,去掉肱骨) The shoulder joint (internal aspect, without humerus).....	031
88. 肩关节(冠状切面) The shoulder joint (coronal section).....	031
89. 肘关节(前面观) The elbow joint (anterior aspect).....	032
90. 肘关节矢状切面(示肱尺关节) Sagittal section of the elbow joint (showing the humeroulnar joint).....	032
91. 前臂骨的连结(前面观) The radioulnar syndesmosis (anterior aspect).....	032
92. 手关节(掌面观) The joints of the hand (palmar aspect).....	033
93. 腕关节(冠状切面) The joints of the wrist (coronal section).....	033
94. 腕的韧带(背面观) The ligaments of the wrist (dorsal aspect).....	033
95. 右髋关节(前面观) The right hip joint (anterior aspect).....	034
96. 右髋关节(后面观) The right hip joint (posterior aspect).....	034
97. 切开关节囊(示髋关节内面) The opened articular capsule (showing the internal surface of the hip joint cavity).....	034
98. 髋关节(冠状切面) The hip joint (coronal section).....	034
99. 骨盆的韧带(前面观) The ligaments of the pelvis (anterior aspect).....	035
100. 骨盆的韧带(后面观) The ligaments of the pelvis (posterior aspect).....	035
101. 膝关节(前面观) The knee joint (anterior aspect).....	035
102. 膝关节(后面观) The knee joint (posterior aspect).....	035
103. 膝关节前面观(切除关节囊) The anterior aspect of the knee joint (without the articular capsule).....	036
104. 膝关节后面观(切除关节囊) The posterior aspect of the knee joint (without the articular capsule).....	036
105. 切开关节囊前部(示膝关节腔内面) The anterior aspect of the opened articular capsule (showing the internal surface of the knee joint cavity).....	036
106. 膝关节半月板和交叉韧带(上面观) The articular meniscus and cruciate ligament of the knee joint (superior aspect).....	036
107. 小腿骨连结(前面观) The tibiofibular syndesmosis (anterior aspect).....	037
108. 距小腿关节和足关节(外侧面观) The talocrural joint and the joints of foot (lateral aspect).....	037
109. 足关节(水平切面) The joints of foot (horizontal section).....	037
110. 足底的韧带 The plantar ligaments.....	037
111. 全身肌肉(前面观) Muscles of the whole body (anterior aspect).....	038
112. 全身肌肉(后面观) Muscles of the whole body (posterior aspect).....	039
113. 肌的形态 The morphology of the muscles.....	040
114. 头颈肌(前面观) Muscles of the head and neck (anterior aspect).....	040
115. 头颈肌浅层(外侧面观) Superficial layer of the muscles of the head and neck (lateral aspect).....	041
116. 颈肌(前面观) Muscles of the neck (anterior aspect).....	041
117. 颈肌(外侧面观) The muscles of neck (lateral aspect).....	041
118. 颈深肌群(前面观) Cervical deep muscles group (anterior aspect).....	041
119. 胸、腹壁肌(前面观) Muscles of the thorax and abdominal wall (anterior aspect).....	042

120. 腹后壁肌及膈(前面观) Muscles of the posterior abdominal wall and the diaphragm (anterior aspect).....	042
121. 膈(胸腔面) The diaphragm (thoracic surface).....	042
122. 膈(腹腔面) The diaphragm (abdominal surface).....	043
123. 腹前壁(内面观) Anterior abdominal wall (internal aspect).....	043
124. 腹股沟区(1) Inguinal region (1).....	044
125. 腹股沟区(2) Inguinal region (2).....	044
126. 腹股沟区(3) Inguinal region (3).....	044
127. 腹股沟三角(内面观) Inguinal triangle (internal aspect).....	044
128. 背部肌肉(浅层) Muscles of back (superficial layers).....	045
129. 背部肌肉(中间层) Muscles of back (intermediate layers).....	046
130. 背部肌肉(深层) Muscles of back (deep layers).....	046
131. 上肢肌(前面观)(1) Muscles of the upper limb (anterior aspect) (1).....	047
132. 上肢肌(前面观)(2) Muscles of the upper limb (anterior aspect) (2).....	047
133. 上肢肌(外侧面观) Muscles of the upper limb (lateral aspect).....	048
134. 上肢肌(后面观) Muscles of the upper limb (posterior aspect).....	048
135. 手掌侧肌 Palmar muscles of the hand.....	049
136. 手掌侧腱鞘 The tendinous sheaths of the palmar side of the hand.....	049
137. 手背侧肌 Dorsal muscles of the hand.....	050
138. 手背侧腱鞘 The tendinous sheaths of the dorsal side of the hand.....	050
139. 下肢肌(前面观) Muscles of the lower limb (anterior aspect).....	051
140. 下肢肌(外侧面观) Muscles of the lower limb (lateral aspect).....	051
141. 下肢肌深层(前面观) Deep layer of muscles of lower limb (anterior aspect).....	052
142. 下肢肌深层(后面观) Deep layer of muscles of lower limb (posterior aspect).....	052
143. 足腱鞘(内侧面观) Tendinous sheaths of foot (medial aspect).....	053
144. 足腱鞘(外侧面观) Tendinous sheaths of foot (lateral aspect).....	053
145. 足底肌(1) Plantar muscles (1).....	053
146. 足底肌(2) Plantar muscles (2).....	053
147. 女会阴肌 Muscles of the female perineum.....	054
148. 男会阴肌 Muscles of the male perineum.....	054

内脏学 SPLANCHNOLOGY 055

149. 腹部的分区与平面(1) Regions and planes of abdomen (1).....	056
150. 腹部的分区与平面(2) Regions and planes of abdomen (2).....	056
151. 消化系统全貌 General arrangement of the alimentary system.....	056
152. 口腔结构(1) Structure of the oral cavity (1).....	057
153. 口腔结构(2) Structure of the oral cavity (2).....	057
154. 腮腺、下颌下腺和舌下腺 The parotid gland, submandibular gland and sublingual gland.....	058
155. 上颌恒牙的排列(下面观) Arrangement of the permanent teeth of maxilla (inferior aspect).....	058
156. 下颌恒牙的排列(上面观) Arrangement of the permanent teeth of mandible (superior aspect).....	058
157. 左侧上、下颌恒牙 Left upper and lower permanent teeth.....	058
158. 牙的构造(模式图)※ The structure of the teeth (diagram).....	059
159. 咽与鼻、口、喉的交通(正中矢状切面) Connection of the pharynx and nose, mouth, larynx (median sagittal section).....	060
160. 咽腔(后面观) The pharyngeal cavity (posterior aspect).....	061
161. 咽肌(后面观) The pharyngeal muscles (posterior aspect).....	061
162. 食管的位置及毗邻 Position and neighbourhood of the esophagus.....	062
163. 胃肌 The muscles of the stomach.....	062
164. 胃腔 The cavity of the stomach.....	062
165. 结肠(外面观) The colon (external aspect).....	063
166. 回肠 The ileum.....	063
167. 空肠 The jejunum.....	063
168. 回盲部(内面观) The ileocecal part (internal aspect).....	063
169. 直肠和肛管的肌肉 Muscles of the rectum and the anal canal.....	063
170. 直肠(冠状切面) The rectum (coronal section).....	064
171. 肝(前面观) The liver (anterior aspect).....	064
172. 肝(下面观) The liver (inferior aspect).....	064
173. 输胆管道及开口(前面观)※ The bile passage and its opening (anterior aspect).....	065
174. 呼吸系统全貌 General arrangement of respiratory system.....	066
175. 骨性鼻腔外侧壁(示鼻旁窦的开口) The lateral wall of the bony nasal cavity (showing the apertures of the paranasal sinuses).....	066
176. 鼻旁窦的开口 The openings of paranasal sinuses.....	066

177. 喉软骨和韧带(前面观) The cartilages and ligaments of larynx (anterior aspect).....	067
178. 喉软骨和韧带(后面观) The cartilages and ligaments of larynx (posterior aspect).....	067
179. 喉软骨和韧带(外侧面观)(1) The cartilages and ligaments of larynx (lateral aspect)(1).....	067
180. 喉软骨和韧带(外侧面观)(2) The cartilages and ligaments of larynx (lateral aspect) (2).....	067
181. 喉腔(后面观) The laryngeal cavity (posterior aspect).....	068
182. 喉腔冠状切面(后面观) Coronal section through the laryngeal cavity (posterior aspect).....	068
183. 喉肌(后面观) Muscles of the larynx (posterior aspect).....	068
184. 喉肌(外侧面观) Muscles of the larynx (lateral aspect).....	068
185. 喉口(后面观) The inlet of the larynx (posterior aspect).....	069
186. 通过声带的喉横切面 A transverse section of larynx through the level of vocal folds.....	069
187. 喉腔的喉镜所见 Laryngoscope view of laryngeal cavity.....	069
188. 右肺(内侧面观) Right lung (medial aspect).....	069
189. 左肺(内侧面观) Left lung (medial aspect).....	069
190. 支气管肺段(外面观) Bronchopulmonary segments (lateral aspect).....	070
191. 支气管肺段(内面观) Bronchopulmonary segments (medial aspect).....	070
192. 支气管肺段(前面观) Bronchopulmonary segments (anterior aspect).....	071
193. 支气管肺段(后面观) Bronchopulmonary segments (posterior aspect).....	071
194. 肺和胸膜(前面观) The lungs and the pleura (anterior aspect).....	072
195. 纵隔(右外侧面观) The mediastinum (right lateral aspect).....	073
196. 纵隔(左外侧面观) The mediastinum (left lateral aspect).....	074
197. 泌尿生殖系统概观 General arrangement of the urogenital system.....	075
198. 腹后壁(示肾及输尿管的位置) Posterior abdominal wall (showing the kidneys and ureters in site).....	076
199. 肾动脉和静脉的位置 The position of renal artery and vein.....	076
200. 肾的位置和毗邻(前面观) The position and neighbourhood of the kidneys (anterior aspect).....	077
201. 肾的位置和毗邻(后面观) The position and neighbourhood of the kidneys (posterior aspect).....	077
202. 肾段动脉模式图 Diagram of renal segmental arteries.....	077
203. 右肾冠状切面(后面观) Coronal section of the right kidney (posterior aspect).....	078
204. 肾筋膜模式图(经右肾矢状切面) Diagram of renal fascia (sagittal section through right kidney).....	078
205. 肾筋膜模式图(经第二腰椎横切面) Diagram of renal fascia (transverse section through 2nd lumbar vertebra).....	078
206. 右睾丸、附睾及被膜 The right testis, epididymis and their coverings.....	079
207. 睾丸内部结构模式图 Diagram showing structure of testis.....	079
208. 膀胱及男性尿道前列腺部(正中矢状切面) The bladder and the prostatic part of the male urethra (median sagittal section).....	079
209. 膀胱、前列腺及精囊(后面观) The urinary bladder, prostate and seminal vesicle (posterior aspect).....	079
210. 阴茎(尿道面) The penis (urethral surface).....	080
211. 阴茎(正中矢状切面) The penis (median sagittal section).....	080
212. 阴茎的海绵体 Cavernous bodies of penis.....	080
213. 男性盆腔(正中矢状切面) Male pelvic cavity (median sagittal section).....	081
214. 女性盆腔(正中矢状切面) Female pelvic cavity (median sagittal section).....	081
215. 女性盆腔结构(上面观) Pelvic cavity structure of female (superior aspect).....	082
216. 女性盆腔器官(前上面观) Pelvic organs of female (anterosuperior aspect).....	082
217. 女性外生殖器 Female external genital organs.....	083
218. 前庭球和前庭大腺 The bulb of vestibule and the greater vestibular gland.....	083
219. 乳房 The mamma.....	084
220. 乳房矢状切面模式图 Diagram of the sagittal section of the mamma.....	084
221. 男性盆腔冠状切面(示尿生殖膈及盆膈) Coronal section of male pelvis cavity (showing urogenital diaphragm and pelvic diaphragm).....	084
222. 女性盆腔冠状切面(示尿生殖膈及盆膈) Coronal section of female pelvis cavity (showing urogenital diaphragm and pelvic diaphragm).....	084
223. 子宫的动脉和静脉 ※ Arteries and veins of uterus.....	085
224. 女性内生殖器(冠状切面) Female internal genital organs (coronal section).....	085
225. 肾单位结构模式图 ※ The diagram of the structure of the nephron.....	086
226. 输精管道及开口(模式图) ※ The ductus deferens and its opening (diagram).....	087
227. 输尿管与子宫动脉(模式图) ※ Ureter and uterine artery (diagram).....	087
228. 小网膜和大网膜 Lesser omentum and greater omentum.....	088
229. 小网膜和胃 The lesser omentum and stomach.....	088
230. 网膜囊 Omental bursa.....	088
231. 腹后壁腹膜的配布 Distribution of the peritoneum on the posterior abdominal wall.....	089
232. 腹后壁腹膜的配布(示系膜根) Distribution of the peritoneum on the posterior abdominal wall (showing the radix of mesentery).....	089
233. 男性盆腔冠状断面 Coronal section of male pelvic cavity.....	090
234. 女性盆腔冠状断面 Coronal section of female pelvic cavity.....	090

235. 女性腹腔(正中矢状切面) Female abdominal cavity (median sagittal section).....	090
--	-----

脉管系统 VASCULAR SYSTEM.....091

236. 全身血管(模式图) Blood vessels of whole body (diagram).....	092
237. 心脏的位置及毗邻 Position and neighbourhood of the heart.....	093
238. 心包及其毗邻器官 Pericardium and its neighbouring organs.....	094
239. 心脏的外形和血管(前面观) Outline form of the heart and its blood vessels (anterior aspect).....	095
240. 心脏的外形和血管(后面观) Outline of the heart and its blood vessels (posterior aspect).....	095
241. 心脏的血管(胸肋面)※ The blood vessels of the heart (sternocostal surface).....	096
242. 心脏的血管(心底面观)※ The blood vessels of the heart (cardiac base aspect).....	097
243. 心底(后面观) Base of heart (posterior aspect).....	098
244. 心底和心的膈面(后下面观) Base and diaphragmatic surfaces (posteroinferior aspect).....	098
245. 右心房(内面观) The right atrium (internal aspect).....	099
246. 右心室(内面观) The right ventricle (internal aspect).....	099
247. 左心房(外面观)和左心室(内面观) The left atrium (latenal aspect) and the left ventricle (internal aspect).....	100
248. 左心房和左心室(内面观) The left atrium and left ventricle (internal aspect).....	100
249. 房间隔和室间隔(水平切面) Interatrial septum and interventricular septum (plane of section).....	101
250. 心脏的瓣膜(上面观)(1) Cardiac valves (superior aspect) (1).....	101
251. 心脏的瓣膜(上面观)(2) Cardiac valves (superior aspect) (2).....	101
252. 大小循环示意图※ Diagram illustrating the greater and the lesser circulation.....	102
253. 心脏传导系统(右内面观)※ Conducting system of the heart (right internal aspect).....	103
254. 心脏传导系统(左内面观)※ Conducting system of the heart (left internal aspect).....	103
255. 心包腔 The pericardial cavity.....	104
256. 心瓣膜的体表投影 The surface projection of the valves of the heart.....	104
257. 头、颈部动脉※ Arteries of the head and neck.....	105
258. 颈内动脉和椎动脉※ The internal carotid artery and the vertebral artery.....	106
259. 面部主要血管 Chief blood vessels of the face.....	107
260. 锁骨下动脉和腋动脉 The subclavian artery and the axillary artery.....	107
261. 腋动脉和肩周动脉吻合(前面观)※ Axillary artery and anastomoses around scapula (anterior aspect).....	108
262. 腋动脉和肩周动脉吻合(后面观)※ Axillary artery and anastomoses around scapula (posterior aspect).....	108
263. 臂的动脉(前面观) Arteries of arm (anterior aspect).....	109
264. 臂的动脉(后面观) Arteries of arm (posterior aspect).....	109
265. 肱动脉和肘关节血管吻合(模式图)※ Brachial artery and anastomoses around elbow (diagram).....	110
266. 前臂动脉(前面观) Arteries of forearm (anterior aspect).....	111
267. 前臂动脉(后面观) Arteries of forearm (posterior aspect).....	111
268. 右手掌面动脉(浅层)※ Arteries of the palm of right hand (superficial layer).....	112
269. 右手掌面动脉(深层)※ Arteries of the palm of right hand (deep layer).....	113
270. 胸主动脉及其分支 Thoracic aorta and its branches.....	114
271. 腹主动脉分支 Branches of the abdominal aorta.....	114
272. 腹腔干及其分支(1) Celiac trunk and its branches (1).....	115
273. 腹腔干及其分支(2) Celiac trunk and its branches (2).....	115
274. 腹腔干及其分支(模式图)※ Celiac trunk and its branches (diagram).....	116
275. 异常肝左动脉(模式图)※ Abnormal left hepatic artery (diagram).....	116
276. 肠系膜上动脉和肠系膜下动脉及其分支※ The superior mesenteric artery and inferior mesenteric artery and their branches.....	117
277. 小肠动脉※ Arteries of small intestine.....	118
278. 男性盆腔的动脉(正中矢状切面)※ Arteries of the male pelvic cavity (median sagittal section).....	119
279. 女性盆腔的动脉(正中矢状切面)※ Arteries of the female pelvic cavity (median sagittal section).....	120
280. 下肢动脉模式图(前面观)※ The diagram of the lower limb artery (anterior aspect).....	121
281. 大腿和膝的动脉(模式图)※ Arteries of thigh and knee (diagram).....	121
282. 大腿的动脉和神经(前面观)※ Arteries and nerves of thigh (anterior aspect).....	122
283. 大腿的动脉(前面观):深层※ Arteries of thigh (anterior aspect): deep layer.....	122
284. 股骨头和股骨颈的动脉※ Arteries of femoral head and neck.....	123
285. 股骨头和股骨颈的动脉※ Arteries of femoral head and neck.....	123
286. 小腿的动脉(前面观)※ Arteries of leg (anterior aspect).....	124
287. 足背的动脉※ Dorsal arteries of foot.....	124
288. 小腿的动脉(后面观)深层 Arteries of leg (posterior aspect) deep layer.....	125
289. 小腿的血管(后面观) Blood vessels of the leg (posterior aspect).....	125
290. 足底的动脉※ Plantar arteries of foot.....	125
291. 头颈部的静脉※ Veins of the head and neck.....	126
292. 颅内、外静脉的交通※ Communications between intracranial and extracranial veins.....	127
293. 上肢浅静脉(前面观) Superficial veins of the upper limb (anterior aspect).....	128

294. 上肢浅静脉(后面观) Superficial veins of the upper limb (posterior aspect)	128
295. 大隐静脉 ※ The great saphenous vein	129
296. 小隐静脉 ※ The small saphenous vein	129
297. 肝门静脉及其属支(模式图) ※ Hepatic portal vein and its tributaries (diagram)	130
298. 肝门静脉和门腔静脉吻合(模式图) ※ Hepatic portal vein and portocaval anastomosis (diagram)	131
299. 颈部深层、腋窝、乳腺的淋巴管和淋巴结 The lymphatic vessels and the lymph nodes of the deep cervical and the axilla and the mammary glands	132
300. 头颈部浅层淋巴管和淋巴结 Superficial lymph vessels and nodes of head and neck	133
301. 颈深部及舌的淋巴管和淋巴结 Lymph vessels and nodes of deep neck and tongue	133
302. 腋窝、乳腺的淋巴管和淋巴结 The lymph vessels and nodes of axilla and mammary glands	134
303. 纵隔的淋巴管和淋巴结(左外侧面观) Lymph vessels and nodes of mediastinum (left lateral aspect)	134
304. 胸腔脏器的淋巴管和淋巴结 ※ Lymph vessels and lymph nodes of thoracic viscerae	135
305. 气管、支气管及肺的淋巴管和淋巴结 ※ Lymph vessels and lymph nodes of trachea, bronchi and lungs	135
306. 体腔后壁的静脉和淋巴回流图 ※ Veins and lymph vessels on the internal aspect of the dorsal abdominal wall	136
307. 胃的淋巴(前面观) Lymph of stomach (anterior aspect)	137
308. 胃的淋巴(后面观) Lymph of stomach (posterior aspect)	137
309. 小肠的淋巴管和淋巴结 Lymph vessels and nodes of small intestine	137
310. 直肠和会阴的淋巴管和淋巴结 Lymph vessels and nodes of rectum and perineal	137
311. 腹后壁的淋巴管和淋巴结 Lymph vessels and nodes of posterior abdominal wall	138
312. 结肠的淋巴管和淋巴结 Lymph vessels and nodes of colon	138
313. 男性盆腔的淋巴管和淋巴结 Lymph vessels and nodes of male pelvic cavity	138
314. 上肢浅部淋巴管和淋巴结 Superficial lymphatic vessels and lymph nodes of the upper limb	139
315. 下肢浅部淋巴管和淋巴结 Superficial lymphatic vessels and lymph nodes of the lower limb	139
316. 脾(脏面) Spleen (visceral surface)	140
317. 脾(膈面) Spleen (diaphragmatic surface)	140
318. 脾的位置和毗邻 The position of spleen and their relations	140

感觉器 **SENSORY ORGANS**

319. 眼球水平切面(模式图) Horizontal section of the eyeball (diagram)	142
320. 眼的前房和后房 Anterior and posterior chambers of eye	142
321. 眼底的眼底镜所见(左侧) Ophthalmoscopic view of fundus of eyeball (left side)	143
322. 虹膜、睫状体及晶状体(后面观) Iris, ciliary body and lens (posterior aspect)	143
323. 眼球的血管和神经(上面观) ※ Blood vessels and nerves of the eye (superior aspect)	144
324. 眼球的血管 Blood vessels of eyeball	145
325. 眼球的动脉供应及静脉回流(模式图) ※ Arteries supply and venous drainage of the eyeball (diagram)	146
326. 眼球及眶腔(矢状断面) Eyeball and the orbital cavity (sagittal section)	147
327. 泪器(右侧) The lacrimal apparatus (right side)	147
328. 眼球外肌(外侧面观) The extraocular muscles (lateral aspect)	147
329. 眼球外肌(上面观) The extraocular muscles (superior aspect)	147
330. 位听器模式图(右侧) Diagram of the organs of the hearing and equilibration (right side)	148
331. 乳突、乙状窦和面神经的关系 Relations of the mastoid process sigmoid sinus and the facial nerve	148
332. 右侧鼓膜(外侧面观) Right tympanic membrane (lateral aspect)	148
333. 右侧听小骨 Right auditory ossicles	148
334. 鼓室内侧壁(右侧) Medial wall of the tympanic cavity (right side)	149
335. 鼓室外侧壁(右侧) Lateral wall of the tympanic cavity (right side)	149
336. 右侧骨迷路及膜迷路(前外侧观) Right bony labyrinth and membranous labyrinth (anterolateral aspect)	149
337. 右侧骨迷路(内面观) Right bony labyrinth (internal aspect)	149
338. 右侧膜迷路(后内侧观) Right membranous labyrinth (postero-medial aspect)	150
339. 耳蜗断面 The section of cochlea	150
340. 迷路的血管 ※ Blood vessels of the labyrinth	150
341. 前庭蜗器和外淋巴 ※ Vestibulocochlear organ and perilymph	151
342. 皮肤的构造(模式图) The structure of the skin (diagram)	152

神经和内分泌系统 **NERVOUS AND ENDOCRINE SYSTEMS**

343. 神经系统概观 General view of nervous system	154
344. 神经元的类型 Types of the neuron	154
345. 神经元的结构(电镜模式图) Structure of the neuron (diagram of electron microscope)	155
346. 脊髓颈段横切面 Transverse section through cervical segment of spinal cord	155

347. 脊髓的细胞构筑分层 Cytoarchitectonic layers of the spinal cord	155
348. 脊髓和脊神经分支起始部位(后面观) Spinal cord and ventral rami in situ (posterior aspect)	156
349. 脊神经根和椎骨的对对应关系(模式图 1、2、3) Relation of spinal nerve roots to vertebrae (diagram 1、2、3)	157
350. 皮肤感觉区的主要平面(前面观) Levels of principal dermatomes (anterior aspect)	158
351. 皮肤感觉区的主要平面(后面观) Levels of principal dermatomes (posterior aspect)	158
352. 脊髓的被膜(后面观) Meninges of the spinal cord (posterior aspect)	159
353. 脊髓和脊神经根 Spinal cord and roots of spinal nerve	159
354. 脊髓的血管(动脉) Blood vessels of spinal cord (artery)	160
355. 脊髓的血管 Blood vessels of spinal cord	160
356. 脊髓的血管(静脉) Blood vessels of spinal cord (veins)	160
357. 脊髓的动脉 ※ Arteries of spinal cord	161
358. 脑底面 Basal surface of the brain	162
359. 大脑底面 The inferior surface of cerebrum	162
360. 脑外侧侧面 Lateral surface of the brain	163
361. 脑的正中矢状面(1) Median sagittal section of the brain (1)	163
362. 脑的正中矢状面(2) Median sagittal section of the brain (2)	163
363. 脑干(背面观) Brain stem (dorsal aspect)	164
364. 脑干的脑神经核(侧面观) Cranial nerve nuclei in brainstem (lateral aspect)	164
365. 脑干的脑神经核(模式图) ※ Cranial nerve nuclei in brainstem (diagram)	165
366. 延髓尾侧部水平切面(经锥体交叉) Horizontal section of the caudal part of the medulla oblongata (through the pyramidal decussation)	166
367. 延髓水平切面(经内侧丘系交叉) Horizontal section of the medulla oblongata (through the decussation of the medial lemniscus)	166
368. 延髓水平切面(经橄榄中部) Horizontal section of the medulla oblongata (through the middle part of the olive)	167
369. 延髓水平切面(经橄榄上部) Horizontal section of the medulla oblongata (through the superior part of the olive)	167
370. 脑桥水平切面(经脑桥中、下部) Horizontal section of the pons (through the middle, inferior part of the pons)	168
371. 脑桥水平切面(经脑桥中部) Horizontal section of the pons (through the middle part of the pons)	168
372. 脑桥水平切面(经脑桥上) The horizontal section of the pons (through the superior part of pons)	169
373. 中脑水平切面(经下丘) The horizontal section of midbrain (through the inferior colliculus)	169
374. 中脑水平切面(经上丘颅侧部) The horizontal section of midbrain (through the cranial part of superior colliculus)	170
375. 中脑上端与间脑之间水平切面(经后连合) The horizontal section between superior mesencephalic extremity and diencephalon (through posterior commissure)	170
376. 小脑(上面观) Cerebellum (superior aspect)	171
377. 小脑(下面观) Cerebellum (inferior aspect)	171
378. 小脑和脑干(背面观) The cerebellum and the brain stem (dorsal aspect)	171
379. 小脑深核 Deep cerebellar nucleus	171
380. 大脑半球内面的沟回 Sulci and gyri of medial surface of the cerebral hemisphere	172
381. 大脑岛叶的沟回 Sulci and gyri of cerebral insula	172
382. 脑的水平切面 Horizontal section of the brain	173
383. 间脑(内侧面观) Diencephalon (medial aspect)	173
384. 间脑冠状切面(乳头体平面) Coronal section of diencephalon (level at the mammillary body)	173
385. 大脑半球内侧面的动脉 Arteries of the medial surface of the cerebral hemisphere	174
386. 大脑半球外侧面的动脉 Arteries on the lateral surface of the cerebral hemisphere	174
387. 脑底部的动脉(1) ※ Arteries at the base of the brain (1)	175
388. 脑底部的动脉(2) ※ Arteries at the base of the brain (2)	175
389. 脑的动脉 ※ Arteries of brain	176
390. 大脑中动脉的皮质支和中央支 ※ The cortical and median branches of middle cerebral artery	176
391. 大脑动脉环(1) ※ Cerebral arterial circle (1)	177
392. 大脑动脉环(2) Cerebral arterial circle (2)	177
393. 脑动脉的吻合(模式图) ※ Anastomoses of arteries to brain (diagram)	178
394. 颅后窝的动脉 Arteries of posterior cranial fossa	179
395. 颅后窝的静脉 Veins of posterior cranial fossa	179
396. 硬脑膜和硬膜静脉窦(上面观) Cerebral dura mater and dural venous sinusec (superior aspect)	180
397. 大脑半球外侧面的静脉 Veins of the lateral surface of cerebral hemisphere	180
398. 硬脑膜窦(后面观) Venous sinus of dura mater (posterior aspect)	180
399. 大脑表面的静脉(外侧观) ※ Superficial veins of cerebral (lateral aspect)	181
400. 大脑室管膜下静脉 ※ Subependymal veins of brain	181
401. 大脑深静脉(上面观) Deep veins of brain (superior aspect)	182
402. 大脑深静脉(下面观) Deep veins of brain (inferior aspect)	182

403. 侧脑室(上面观) Lateral ventricle (superior aspect).....	183
404. 脑室铸型 Cast of the cerebral ventricle.....	183
405. 硬脑膜及硬脑膜静脉窦(外侧观) Cerebral dura mater and venous sinuses of cerebral dura mater (lateral aspect).....	183
406. 脑脊液循环模式图 ※ Diagram of cerebrospinal fluid circulation.....	184
407. 颈神经丛的皮支 Cutaneous branches of cervical plexus.....	185
408. 颈区和腋区的血管神经 Blood vessels and nerves of the neck region and the axilla region.....	185
409. 膈神经、迷走神经颈胸部的行程和分布 The course and the distribution of the phrenic nerve and cervicothoracic branches of the vagus nerves.....	186
410. 腋窝、臂部的神经及毗邻 Nerves of axillary fossa and arm and their neighbourhood.....	187
411. 前臂的神经(前面观) Nerves of the forearm (anterior aspect).....	187
412. 臂部的神经(后面观) Nerves of the arm (posterior aspect).....	188
413. 手背部的神经及其毗邻结构 The nerves and neighbourhood structures of the dorsum of the hand.....	188
414. 手部神经及血管的体表投影 Surface projection of the nerves and blood vessels of the hand.....	189
415. 肋间神经及其分布 Intercostal nerves and their distribution.....	189
416. 腰丛和骶丛 Lumbar plexus and sacral plexus.....	189
417. 男性会阴部的神经及其毗邻结构 Nerves in the male perineum and their neighbourhood structures.....	190
418. 女性会阴部的神经及其毗邻结构 Nerves in the female perineum and their neighbourhood structures.....	190
419. 股神经和股外侧皮神经 ※ Femoral nerve and lateral cutaneous nerve of thigh.....	191
420. 下肢的皮神经(前面观) Cutaneous nerves of lower limb (anterior aspect).....	191
421. 大腿前内侧面的肌肉、血管和神经(1) Muscles, blood vessels and nerves of the anteromedial aspect of the thigh (1).....	192
422. 大腿前内侧面的肌肉、血管和神经(2) Muscles, blood vessels and nerves of the anteromedial aspect of thigh (2).....	192
423. 小腿前部神经及其毗邻结构(1) Nerves of the anterior aspect of the leg and their neighbourhood structures (1).....	193
424. 小腿前部神经及其毗邻结构(2) Nerves of the anterior aspect of the leg and their neighbourhood structures (2).....	193
425. 坐骨神经和股后皮神经 ※ Sciatic nerve and posterior cutaneous nerve of thigh.....	194
426. 下肢的皮神经(后面观) Cutaneous nerve of lower limb (posterior aspect).....	194
427. 大腿后面的肌肉、血管和神经 Muscles, blood vessels and nerves of the posterior aspect of the thigh.....	195
428. 小腿后面的肌肉、血管和神经(1) Muscles, blood vessels and nerves of the posterior aspect of the leg (1).....	195
429. 小腿后面的肌肉、血管和神经(2) Muscles, blood vessels and nerves of the posterior aspect of the leg (2).....	195
430. 足背部的神经 Dorsal nerves of the foot.....	196
431. 足背部的神经及血管 Dorsal nerves and blood vessels of the foot.....	196
432. 足底部的神经及血管(1) Plantar nerves and blood vessels of the foot (1).....	197
433. 足底部的神经及血管(2) Plantar nerves and blood vessels of the foot (2).....	197
434. 十二对脑神经出颅部位(颅底内面观) The inlet and exit points of the 12 pairs of cranial nerves (internal aspect).....	198
435. 脑干(腹侧面观) Brain stem (ventral aspect).....	198
436. 眶腔内的神经(上面观) Nerves in the orbit (superior aspect).....	199
437. 眶腔内的神经(侧面观) Nerves in the orbit (lateral aspect).....	199
438. 眶内神经(侧面观) ※ The nerves of the orbit (lateral aspect).....	200
439. 前庭蜗神经模式图 ※ Diagram of the vestibulocochlear nerve.....	200
440. 睫状神经节和脑神经(1) Ciliary ganglion and cranial nerves (1).....	201
441. 睫状神经节和脑神经(2) Ciliary ganglion and cranial nerves (2).....	202
442. 翼腭神经节、下颌下神经节和脑神经 Pterygopalatine ganglion, submandibular ganglion and cranial nerves.....	203
443. 三叉神经分支(1) The branches of the trigeminal nerve (1).....	204
444. 三叉神经分支(2) The branches of trigeminal nerve (2).....	204
445. 三叉神经分支模式图(外侧观) ※ Diagram showing distribution of the trigeminal nerve (lateral aspect).....	205
446. 面神经的分支 ※ Branches of facial nerve.....	206
447. 面神经的分支和腮腺 ※ Facial nerve branches and parotid gland.....	206
448. 面神经分支及其毗邻结构 Branches and neighbourhood structures of facial nerve.....	207
449. 前庭蜗神经和面神经(模式图) ※ Vestibulocochlear nerve and facial nerve (diagram).....	207
450. 舌咽神经、迷走神经、副神经和舌下神经 Glossopharyngeal nerve, vagus nerve, accessory nerve and hypoglossal nerve.....	208
451. 迷走神经在颈部的分支(前面观) Branch of the vagus nerve in the neck (anterior aspect).....	208
452. 迷走神经在颈部的分支(右侧侧面观) Branch of the vagus nerve in the neck (right lateral aspect).....	208
453. 舌咽神经的纤维成分及其分布(模式图) ※ Fiber composition and distribution of the glossopharyngeal nerve (diagram).....	209
454. 迷走神经的纤维成分及其分布(模式图) Fiber compositions and distribution of the vagus nerve (diagram).....	210

455. 迷走神经颈部的分支(后面观) ※ Branches of the vagus nerves in the neck (posterior aspect).....	211
456. 左、右迷走神经颈胸部的分支(后面观) Cervicothoracic branches of left and right vagus nerves (posterior aspect).....	212
457. 交感系同脊神经和脊髓的关系(模式图) ※ Showing relation of sympathetic system to spinal nerves and spinal cord (diagram).....	213
458. 自主神经系统(模式图) Autonomic nervous system (diagram).....	214
459. 颈部的自主神经 Autonomic nerves in neck	215
460. 胸部自主神经 Autonomic nerves of the thorax	216
461. 心脏的神经 Nerves of heart	217
462. 腹盆部的自主神经丛和节 Plexuses and ganglia of autonomic nerves in abdomen and pelvis.....	218
463. 躯干、四肢痛、温、触觉传导路 ※ The pain, thalposis and pselaphesic conductive pathways of the trunk and limbs.....	219
464. 躯干、四肢本体感觉和精细触觉传导路 ※ The proprioception and refined tactile sensation pathway of trunk and limbs.....	219
465. 头面部痛、温、触觉传导路 ※ Pathways of pain, thalposis, tactile sensation of head and face.....	220
466. 传向小脑的本体感觉传导路 ※ Pathway of the proprioceptive sensibility conducting to the cerebellum.....	220
467. 锥体系(皮质脊髓束) ※ The pyramidal system (corticospinal tract).....	221
468. 锥体系(皮质核束) ※ The pyramidal system (corticobulbar tract).....	221
469. 锥体外系(纹状体—苍白球系) ※ Extrapyramidal system (corpus striatum-globus pallidus).....	222
470. 锥体外系(皮质—脑桥—小脑系) ※ Extrapyramidal system (cortex-pons-cerebellum system).....	222
471. 嗅区 The olfactory region.....	223
472. 嗅器及其神经分布 ※ The olfactory organs and its innervation.....	223
473. 视觉传导路 ※ The visual pathway.....	224
474. 听觉传导路 ※ The auditory pathway	225
475. 味觉及其神经分布 ※ The gustatory organs and its innervation.....	226
476. 平衡觉传导路 ※ The equilibrium pathway.....	227
477. 膀胱的神经支配示意图 ※ Scheme to show innervation of the urinary bladder.....	228
478. 肝、胆牵涉性痛的反射途径示意图 ※ Scheme to show reflex tracts of the referred pain of the liver and gall-bladder.....	229
479. 心脏牵涉性痛的反射途径示意图 ※ Scheme to show reflex tracts of the referred pain of the heart.....	229
480. 心的神经支配和血压调节示意图 ※ Scheme to show innervation of the heart and regulation of the blood pressure.....	230
481. 支气管、肺的神经支配和呼吸调节示意图 ※ Scheme to show innervation of the bronchi and lungs and control of respiration.....	231
482. 甲状腺及甲状旁腺(前面观) The thyroid gland and the parathyroid glands (anterior aspect).....	232
483. 甲状腺及甲状旁腺(后面观) The thyroid gland and the parathyroid glands (posterior aspect).....	232
484. 胸腺 The thymus.....	232
485. 肾上腺 The suprarenal glands.....	232
486. 下丘脑主要核团(模式图)(1) The principal nuclei of hypothalamus (diagram) (1).....	233
487. 下丘脑主要核团(模式图)(2) The principal nuclei of hypothalamus (diagram) (2).....	233
488. 垂体的血液供应(1) Blood supply of the hypophysis (1).....	233
489. 脑垂体的血液供应(2) Blood supply of the hypophysis (2).....	233
490. 垂体的血液供应(3) ※ Blood supply of the hypophysis.....	234
491. 内分泌腺概观 General view of endocrine glands.....	235
492. 横断面:胸4以上(平胸锁关节) Transverse section: Upper level of T4 (sternoclavicular joint).....	236
493. 横断面:胸4~5椎间盘(平胸骨柄) Transverse section: T4~5 intervertebral disc (manubrium).....	236
494. 横断面:胸5~6椎间盘(胸骨角) Transverse section: T5~6 intervertebral disc (sternal angle).....	237
495. 横断面:胸7平面(平第三肋间隙) Transverse section: level of T7 (3rd interchondral space).....	237
496. 横断面:胸10平面 Transverse section: level of T10	238
497. 横断面:胸12平面(剑突下平面) Transverse section: level of T12 (inferior to xiphoid).....	238
498. 横断面:胸12至腰1椎间盘平面 Transverse section: level of T12-L1 intervertebral disc.....	239
499. 横断面:腰1-2椎间盘平面 Transverse section: level of L1-2 intervertebral disc	239
500. 横断面:骶1平面(髂前上棘平面) Transverse section: level of s1 (anterior superior iliac spines).....	240
501. 横断面:平耻骨嵴、股骨头、尾骨 Transverse section: pubic crest, femoral heads, corryx.....	240